

EMERGENCIES IN CARDIOLOGY

Saul G. Myerson | Robin P. Choudhury |
Andrew R. J. Mitchell

A concise guide to the practical
management of cardiac emergencies

Features a standard layout for early
problem identification

Offers a stepwise action plan to
avoid errors

Senior clinicians present established
principles gained from personal
experience

SECOND EDITION •
2
• SECOND EDITION

☠️ —A true life-threatening emergency. Memorizing these conditions may help. Call immediately for assistance. Try to remain calm and quickly assess ABC. Once the problem has been dealt with remember to reassess- other problems may have been forgotten or missed in the heat of the moment.

⚡️ —These patients need to be assessed very quickly, because they can rapidly deteriorate. Consider senior help/advice.

⚠️ —These conditions require careful assessment and correction but are less likely to become life-threatening emergencies.

❓ —These conditions are non-urgent, or cover general guidance.

OXFORD MEDICAL PUBLICATIONS

Emergencies in Cardiology

Second edition

Published and forthcoming titles in the Emergencies in... series:

Emergencies in Anaesthesia

Edited by Keith Allman, Andrew McIndoe, and Iain H. Wilson

Emergencies in Cardiology

Edited by Saul G. Myerson, Robin P. Choudhury, and Andrew Mitchell

Emergencies in Clinical Surgery

Edited by Chris Callaghan, J. Andrew Bradley, and Christopher Watson

Emergencies in Critical Care

Edited by Martin Beed, Richard Sherman, and Ravi Mahajan

Emergencies in Nursing

Edited by Philip Downing

Emergencies in Obstetrics and Gynaecology

Edited by S. Arulkumaran

Emergencies in Oncology

Edited by Martin Scott-Brown, Roy A.J. Spence, and Patrick G. Johnston

Emergencies in Paediatrics and Neonatology

Edited by Stuart Crisp and Jo Rainbow

Emergencies in Palliative and Supportive Care

Edited by David Currow and Katherine Clark

Emergencies in Primary Care

Chantal Simon, Karen O'Reilly, John Buckmaster, and Robin Proctor

Emergencies in Psychiatry

Basant K. Puri and Ian H. Tressaden

Emergencies in Clinical Radiology

Edited by Richard Graham and Ferdia Gallagher

Emergencies in Respiratory Medicine

Edited by Robert Parker, Catherine Thomas, and Lesley Bennett

Head, Neck and Dental Emergencies

Edited by Mike Perry

Medical Emergencies in Dentistry

Nigel Robb and Jason Leitch

Emergencies in Cardiology

Saul G. Myerson

Consultant Cardiologist,
John Radcliffe Hospital,
Honorary Senior Clinical Lecturer,
University of Oxford
Oxford

Robin P. Choudhury

Wellcome Trust Senior Clinical Fellow
Clinical Director,
Oxford Acute Vascular Imaging Centre
Honorary Consultant Cardiologist
John Radcliffe Hospital, Oxford

Andrew R. J. Mitchell

Consultant Cardiologist,
Jersey General Hospital

OXFORD
UNIVERSITY PRESS

OXFORD

UNIVERSITY PRESS

Great Clarendon Street, Oxford OX2 6DP

Oxford University Press is a department of the University of Oxford.
It furthers the University's objective of excellence in research, scholarship,
and education by publishing worldwide in

Oxford New York

Auckland Cape Town Dar es Salaam Hong Kong Karachi
Kuala Lumpur Madrid Melbourne Mexico City Nairobi
New Delhi Shanghai Taipei Toronto

With offices in

Argentina Austria Brazil Chile Czech Republic France Greece
Guatemala Hungary Italy Japan Poland Portugal Singapore
South Korea Switzerland Thailand Turkey Ukraine Vietnam

Oxford is a registered trade mark of Oxford University Press
in the UK and in certain other countries

Published in the United States
by Oxford University Press Inc., New York

© Oxford University Press, 2010

The moral rights of the author have been asserted
Database right Oxford University Press (maker)

First published 2006
Euromedice edition published 2007
Second edition published 2010

All rights reserved. No part of this publication may be reproduced,
stored in a retrieval system, or transmitted, in any form or by any means,
without the prior permission in writing of Oxford University Press,
or as expressly permitted by law, or under terms agreed with the appropriate
reprographics rights organization. Enquiries concerning reproduction
outside the scope of the above should be sent to the Rights Department,
Oxford University Press, at the address above

You must not circulate this book in any other binding or cover
and you must impose this same condition on any acquirer

British Library Cataloguing in Publication Data
Data available

Library of Congress Cataloging in Publication Data
Data available

Typeset by Cepha Imaging Private Ltd., Bangalore, India
Printed in China

on acid-free paper by
Asia Pacific Offset Limited

ISBN 978-0-19-955438-6

10 9 8 7 6 5 4 3 2 1

Oxford University Press makes no representation, express or implied, that the drug dosages in this book are correct. Readers must therefore always check the product information and clinical procedures with the most up to date published product information and data sheets provided by the manufacturers and the most recent codes of conduct and safety regulations. The authors and publishers do not accept responsibility or legal liability for any errors in the text or for the misuse or misapplication of material in this work. Except where otherwise stated, drug dosages and recommendations are for the non-pregnant adult who is not breast-feeding.

Preface

Acute cardiology problems often need quick, appropriate diagnosis and treatment. With the increasing complexity and rapidly-changing nature of available therapies, knowing which to use and in what situation can be difficult. This book provides an easily accessible guide to diagnosing and managing acute cardiovascular problems and is designed for busy medical and cardiology teams, with expert advice in a clear, concise format. The familiar Oxford Handbook style, with bullet-point information for speed and clarity, is combined with an integral cross-referencing system, enabling rapid access to the necessary information.

This second edition incorporates much of the feedback received from the first edition, and includes updated sections throughout, with significantly expanded sections on myocardial infarction, heart failure, and cardiac problems in pregnancy. There is a new chapter on cardiac drugs and a separate chapter for infective endocarditis. The layout is even clearer than before, with improved text, several new illustrations, algorithms and ECG's and additional practical procedure guidance including exercise ECG interpretation and intra-aortic balloon pumps.

The first section of the book is symptom based and is designed to help clinch the diagnosis with suggestions of the key points in the history, physical findings and investigations and extensive cross-referencing to specific cardiac conditions later in the book.

The second section "Specific conditions" describes the presentation, investigation and management of all the common (and some uncommon) acute cardiac problems. The chapter authors have used their specialist knowledge to guide management in all areas, including potentially challenging problems such as arrhythmias (and implantable defibrillators), cardiac issues in pregnancy, cardiac problems around the time of surgery, adults with congenital heart disease, and cardiac trauma.

The final section deals with "practical issues", with clear descriptions of how to perform common practical cardiac procedures. It also includes a chapter on the art of ECG recognition with a library of example ECGs to help pattern recognition.

We hope that you enjoy the new edition of the book and use it to enhance the care of your patients. We welcome further suggestions for alterations and inclusions in future editions.

This page intentionally left blank

Contents

Contributors *ix*

Symbols and abbreviations *xi*

Part I **Presentation: making the diagnosis**

1	Cardiovascular collapse	3
2	Chest pain	13
3	Shortness of breath	19
4	Syncope	23
5	Palpitation	33

Part II **Specific conditions**

6	Acute coronary syndromes	39
7	Acute heart failure	67
8	Valve disease	93
9	Infective endocarditis	121
10	Arrhythmias	137
11	Aortic dissection	189
12	Pericardial disease	203
13	Pulmonary vascular disease	213
14	Systemic emboli	227
15	Cardiac issues in pregnancy	235
16	Adult congenital heart disease	253
17	Perioperative care	291
18	Cardiac drugs: effects and cardiotoxicity	309
19	Miscellaneous conditions	347

Part III Practical issues

20	Practical procedures	359
21	ECG recognition	383

Index 431

Contributors

Dr Kaleab Asress

Registrar in Cardiology
General Hospital
St. Helier
Jersey
*Pulmonary vascular disease
Shortness of breath*

Dr Adrian Banning

Consultant Cardiologist
John Radcliffe Hospital
Oxford
Aortic dissection

Prof. Harald Becher

Consultant Cardiologist
John Radcliffe Hospital
Oxford
Pericardial disease

Dr Tim Betts

Consultant Cardiologist and
Electrophysiologist
John Radcliffe Hospital
Oxford
Arrhythmias

Prof. Keith Channon

Oxford University Dept. of
Cardiovascular Medicine
John Radcliffe Hospital
Oxford
Acute coronary syndromes

Dr Robin Choudhury

Wellcome Trust Senior Clinical
Fellow
Oxford University Dept. of
Cardiovascular Medicine;
Honorary Consultant Cardiologist
John Radcliffe Hospital
Oxford
*Acute coronary syndromes
Chest pain
Perioperative care*

Dr Jo D'Arcy

Cardiology Registrar
John Radcliffe Hospital
Oxford
Acute heart failure

Dr Jeremy Dwight

Consultant Cardiologist
John Radcliffe Hospital
Oxford
Acute heart failure

Prof. Pierre Foex

Professor of Anaesthesia
Nuffield Dept. of Anaesthesia
John Radcliffe Hospital
Oxford
Perioperative care

Prof. Michael Gatzoulis

Consultant Cardiologist
Adult Congenital Heart Disease
and Pulmonary Hypertension Unit,
Royal Brompton Hospital
London
Adult congenital heart disease

Dr George Giannakoulas

Clinical Research Fellow
Adult Congenital Heart Disease
and Pulmonary Hypertension Unit,
Royal Brompton Hospital
London
Adult congenital heart disease

Dr Lucy Hudsmith

Registrar in Cardiology
John Radcliffe Hospital
Oxford
Cardiac issues in pregnancy

Dr Andrew R. J. Mitchell

Consultant Cardiologist
General Hospital
St. Helier
Jersey
Aortic dissection
Pulmonary vascular disease
Shortness of breath
Miscellaneous conditions

Dr Steve Murray

Consultant Cardiologist and
Electrophysiologist
The Freeman Hospital
Newcastle
ECG recognition

Dr Saul G. Myerson

Consultant Cardiologist
John Radcliffe Hospital;
Honorary Senior Clinical Lecturer
University of Oxford
Oxford
Chest pain
Infective endocarditis
Palpitation
Perioperative care
Valve disease

Dr Sheraz Nazir

Department of Cardiology
John Radcliffe Hospital
Oxford
*Cardiac drugs: effects and
cardiotoxicity*

Dr Mark Petersen

Consultant Cardiologist
Gloucester Royal Hospital
Gloucestershire
Syncope

Dr Jon Salmon

Consultant Physician
Adult Intensive Care Unit
John Radcliffe Hospital
Oxford

Cardiovascular collapse

Dr Cheerag Shirodaria

Registrar in Cardiology
John Radcliffe Hospital
Oxford
*Cardiac drugs: effects and
cardiotoxicity*

Dr Rodney Stables

Consultant Cardiologist
The Cardiothoracic Centre
Liverpool
Practical procedures

Dr Jonathan Timperley

Consultant Cardiologist
Northampton General Hospital
Northampton
Systemic emboli

Dr Sara Thorne

Consultant Cardiologist in Adult
Congenital Heart Disease
University Hospital Birmingham
Birmingham
Cardiac issues in pregnancy

Dr Anselm Uebing






Department of Paediatric
Cardiology
University Hospital of
Schleswig-Holstein
Kiel
Germany
Adult congenital heart disease

Dr Kelvin Wong

Department of Cardiology
John Radcliffe Hospital
Oxford
Arrhythmias

The authors are grateful to Louise Beaumont, Medicines Information & Cardiology Pharmacist, John Radcliffe Hospital, Oxford for her diligent work in checking the drugs and doses

Symbols and Abbreviations

	cross reference
	warning
	important
	don't dawdle
∴	therefore
↑	increased
↓	decreased
→	leading to
Δ	differential diagnosis
1°	primary
2°	secondary
>	greater than
<	less than
~	approximately
	website
∴	therefore
3D	three-dimensional
5-FU	5-fluorouracil
ACE	angiotensin-converting enzyme
ACHD	adult congenital heart disease
ACS	acute coronary syndrome
ACT	activated clotting time
ADP	adenosine diphosphate
AF	atrial fibrillation
ANA	antinuclear antibody
AP	action potential
AR	aortic regurgitation
ARVC	arrhythmogenic right ventricular cardiomyopathy
AS	aortic stenosis
ASAP	as soon as possible
ASD	atrial septal defect
ASO	antistreptolysin O
AST	aspartate aminotransferase
ATP	antitachycardia pacing

AV	atrioventricular
AVNRT	atrioventricular nodal re-entry tachycardia
AVR	aortic valve replacement
AVRT	atrioventricular re-entry tachycardia
AVSD	atrioventricular septal defect
BD	twice daily
BNP	brain natriuretic peptide
BP	blood pressure
BT	Blalock–Taussig
CABG	coronary artery bypass graft
ccTGA	congenitally corrected transposition of the great arteries
CHB	complete heart block
CK	creatin kinase
cm	centimetre/s
CMR	cardiovascular magnetic resonance
CNS	central nervous system
COPD	chronic obstructive pulmonary disease
COX	cyclooxygenase
CPAP	continuous positive airway pressure
CPR	cardio-pulmonary resuscitation
CRP	C-reactive protein
CT	computed tomography
CTPA	computed tomography pulmonary angiography
CVP	central venous pressure
CXR	chest X-ray
DC	direct current
DCM	dilated cardiomyopathy
DIC	disseminated intravascular coagulation
DVT	deep vein thrombosis
ECG	electrocardiogram
ECMO	extracorporeal membrane oxygenation
EMI	electromagnetic interference
ESR	erythrocyte sedimentation rate
FBC	full blood count
FFP	fresh frozen plasma
g	gram/s
GA	general anaesthetic
GI	gastrointestinal
GP	general practitioner
GTN	glyceryl trinitrate

HACEK	<i>Haemophilus species, Actinobacillus actinomycetemcomitans, Cardiobacterium hominis, Eikenella corrodens, and Kingella species</i>
HCM	hypertrophic cardiomyopathy
HDL	high-density lipoprotein
HDU	High Dependency Unit
HR	heart rate
IABP	intra-aortic balloon pump
ICD	implantable cardioverter defibrillator
ICU	Intensive Care Unit
IHD	ischaemic heart disease
IM	intramuscular
INR	international normalized ratio
IV	intravenous
IVC	inferior vena cava
JVP	jugular venous pressure
LA	left atrium/atrial
LAD	left anterior descending
LBBB	left bundle branch block
LDL	low-density lipoprotein
LFT	liver function test
LV	left ventricle/ventricular
LVF	left ventricular failure
LVOT	left ventricular outflow tract
m	metre/s
MAP	mean arterial pressure
mcg	microgram/s
MCV	mean corpuscular volume
MI	myocardial infarction
min	minute/s
mL	millilitre/s
MR	mitral regurgitation
MRI	magnetic resonance imaging
MS	mitral stenosis
msec	millisecond
N/saline	normal saline
NSAID	non-steroidal anti-inflammatory drug
NSTEMI	non-ST segment elevation myocardial infarction
OD	once daily
PCI	percutaneous coronary
PCR	polymerase chain reaction

PCWP	pulmonary capillary wedge pressure.
PDA	patent ductus arteriosus
PE	pulmonary embolism
PEA	pulseless electrical activity
PET	positron emission tomography
PFO	patent foramen ovale
PFT	pulmonary function test
PLE	protein-losing enteropathy
PO	<i>per os</i> (orally)
PR	pulmonary regurgitation
PRN	when necessary
QDS	four times daily
RA	right atrium/atrial
RBBB	right bundle branch block
RCA	right coronary artery
RV	right ventricle/ventricular
RVOT	right ventricular outflow tract
RVOTO	right ventricular outflow tract obstruction
S ₁	first heart sound
S ₂	second heart sound
S ₃	third heart sound
S ₄	fourth heart sound
SaO ₂	arterial oxygen saturation
SCD	sudden cardiac death
ScvO ₂	central venous oxygen saturation
sec	seconds/s
SL	sublingual
SLE	systemic lupus erythematosus
SOB	shortness of breath
SpO ₂	saturation of peripheral oxygen
SR	sustained release
STEMI	ST segment elevation myocardial infarction
SVC	superior vena cava
SVT	supraventricular tachycardia
TCPC	total cavopulmonary connection
TDS	three times daily
TIA	transient ischaemic attack
TIMI	thrombolysis in myocardial infarction
TNK	tenecteplase
TOE	transoesophageal echocardiogram

ToF	tetralogy of Fallot
TR	tricuspid regurgitation
TTE	transthoracic echocardiography
TTP	thrombotic thrombocytopenic purpura
U&E	urea and electrolytes
URTI	upper respiratory tract infection
VF	ventricular fibrillation
VLDL	very low-density lipoprotein
VT	ventricular tachycardia
VSD	ventral septal defect
VTE	venous thromboembolism
WCC	white cell count
WPW	Wolff–Parkinson–White

This page intentionally left blank

Part 1

Presentation: making the diagnosis

Chapter 1	Cardiovascular collapse	3
Chapter 2	Chest pain	13
Chapter 3	Shortness of breath	19
Chapter 4	Syncope	23
Chapter 5	Palpitation	33

This page intentionally left blank

Cardiovascular collapse

Introduction 4

Cardiac arrest 4

Shock 4

Initial assessment 6

Approaching a differential 6

Immediate actions 8

Continuing investigation and treatment 10

Introduction

Cardiovascular collapse is the rapid or sudden development of circulatory failure. This forms part of a spectrum of shock which encompasses:

- Cardiac arrest
- Shock—overt and compensated.

Cardiac arrest

Treat immediately according to current guidelines (see Fig. 1.1).

Shock

- *Systolic BP <90 mmHg with features of reduced organ perfusion*

In shock, cardiac output may be high (e.g. sepsis) or low (e.g. cardiogenic shock). The common factor is failure of tissue oxygen delivery and/or tissue oxygen utilization. The clinical presentation depends upon the severity and speed of onset of the cause and the physiologic reserve of the host. Determining the cause may be difficult and the diagnosis may only be apparent following, or during, resuscitation. Pathologies frequently co-exist, particularly in the elderly (e.g. cardiac failure complicating sepsis).

► Assessment and treatment should proceed in parallel.

The immediate priorities are to maintain:

- A safe airway and oxygenation
- Sufficient circulation to perfuse the heart and brain.

When these have been achieved, there is time to refine the diagnosis and indulge in special investigations and specific treatment while continuing to resuscitate the circulation.

This may involve a trade-off between giving fluids and vasoactive drugs to improve the peripheral circulation at the expense of increasing myocardial work. However, it is critical: failure to restore adequate tissue perfusion vastly increases mortality and makes all your hard work meaningless.

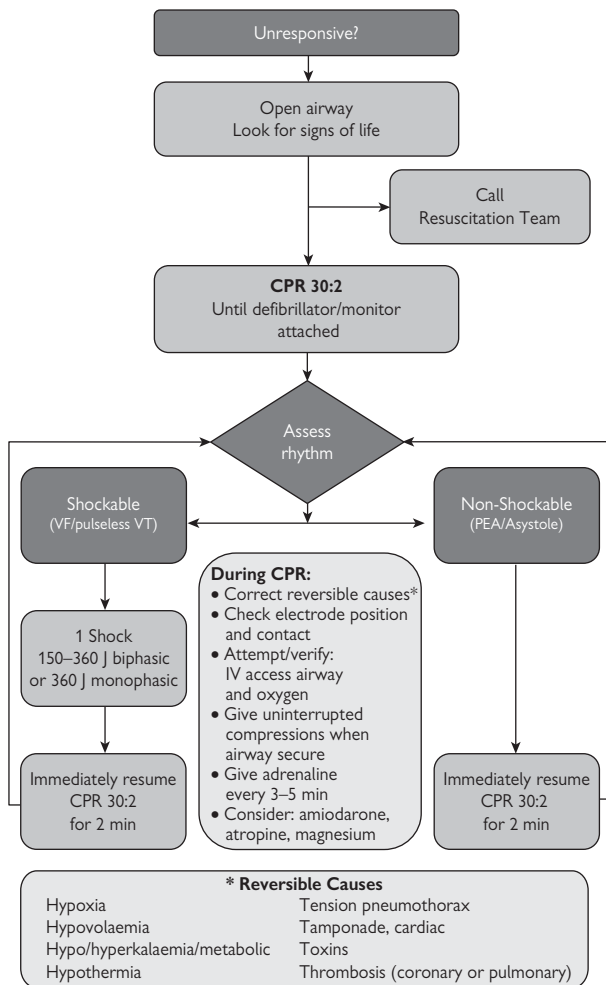


Fig. 1.1 The Advanced Life Support universal algorithm for the management of cardiac arrest in adults. Reproduced with permission from the Resuscitation Council UK.

Initial assessment

This should be rapid. You need to decide whether the patient can survive more detailed assessment or whether you must start resuscitating immediately.

► If the patient can speak, take a brief, focused history; if not, assess the patient whilst questioning nursing staff, ambulance personnel, or relatives.

Check immediately

- **A**irway competence
- **B**reathing
- **C**irculation—pulse: rate and character.

Specifically examine

- Peripheral perfusion, including capillary refill
- BP
- JVP
- Is there a sternotomy scar?
- Check the trachea
- Percuss the upper chest and listen to air entry to exclude pneumothorax and for crackles of pulmonary oedema
- Listen to the heart. Are there any (possibly new) murmurs?
- Quickly feel the abdomen for distension, pulsatile masses etc.
- Assess conscious level using the AVPU score:
 - A = Awake
 - V = responds to Voice only
 - P = responds to Pain
 - U = Unresponsive
- Check capillary blood sugar.

Obtain (or nominate a colleague to obtain)

- 12-lead ECG
- CXR
- Arterial blood gas analysis
- Urgent biochemistry—U&E, Ca^{2+} , Mg^{2+} , troponin, glucose, CK, amylase
- FBC, clotting studies, group and save
- If sepsis seems likely, check CRP and send blood cultures.

Approaching a differential

At the end of this you should have sufficient information to make a preliminary diagnosis and assign the patient to one of three main categories:

- Intrinsic cardiogenic
- Extrinsic cardiogenic
- Non-cardiogenic.

See Box 1.1 for causes.

Box 1.1 Causes of shock***Intrinsic cardiogenic***

- Acute myocardial failure
- Acute myocardial ischaemia
- Acute valvular lesion
- Cardiodepressant drugs
- Arrhythmia.

Extrinsic cardiogenic

- Pulmonary embolus
- Pericardial tamponade
- Tension pneumothorax.

Non-cardiogenic

- Sepsis
- Anaphylaxis
- Hypovolaemia
- Vasoactive drug toxicity (drug-induced hypotension).

Immediate actions

- ▶ Reassess Airway, Breathing, Circulation frequently.
- ▶ Treat cardiac arrest according to protocol.

Initial targets

- Mean arterial BP >60 mmHg (systolic >90 mmHg)
- PaO₂ >8 kPa.

Respiratory management

- Place Guedel airway if patient unconscious, to maintain airway
- High-flow O₂ via reservoir bag or assist ventilation with bag and mask
- For tension pneumothorax perform immediate needle thoracostomy followed by formal chest drainage
- If the patient is conscious, hypoxic, and has pulmonary oedema or respiratory distress, face-mask continuous airways pressure (📖 p.10) may be a valuable precursor or alternative to intubation.

When to call the anaesthetist

- Airway compromised
- Severe respiratory failure
 - Respiratory rate >30 or <10 breaths per min
 - PaO₂ <10 kPa on high-flow O₂
 - ↑PaCO₂
- Patient comatose (AVPU = P or U)
- Cardioversion likely to be required
- Do not attempt intubation without good IV access and resuscitation drugs, unless patient is already in cardiac arrest.

Circulatory management

- Establish good peripheral IV access
- If significant bradycardia, give atropine 0.5–1 mg IV and consider external pacing if inadequate response (📖 p.368)
- If the patient is not in intrinsic cardiogenic shock and is without evidence of intravascular volume overload or pulmonary oedema, give rapid IV fluid challenge (100–200 mL colloid or 250–500 mL Hartmann's/0.9% saline). If beneficial, repeat
- If BP remains low (<70 mmHg systolic) despite adequate filling and treatment of immediately reversible causes, obtain central venous access and start inotropes (see Table 1.1)
- If there are delays in obtaining central venous access or in setting up an infusion of inotropes, consider small boluses of adrenaline (0.25–0.5 mL 1:10,000 from a Minijet®) peripherally. Remember, circulation time will be long: there may be no response for 60 sec (it will feel longer).

General management

- If glucose low, give 50 mL, 50% dextrose immediately
- If pupils are constricted and patient is unresponsive, give naloxone 200–400 mcg IV stat. If improvement, repeat.

Table 1.1 Table of inotropes. Infusions should be given centrally. Dopamine and dobutamine can be given peripherally at lower concentrations (dilute in 500 mL, not 50 mL). Caution with extravasation of bolus drugs. An inoconstrictor (epinephrine or dopamine) can be used if norepinephrine is not immediately to hand, though norepinephrine is preferable if the patient is very tachycardic (>120 bpm), or if there is clear evidence of myocardial ischaemia. Ephedrine or metaraminol are reasonable alternatives for peripheral boluses.

	Route of administration	Formulation	Dose range	Initial dose (70kg man)
Vasodilators				
GTN				
<i>Initial treatment of angina or acute LVF</i>	Bolus (SL spray)	400 mcg		2–4 puffs
<i>Continued treatment of anginal/LVF</i>	Infusion 1mg/mL	50 mg in 50 mL N/saline	0.5–20 mg/hour	2–5 mL/hour
Inodilators				
Dobutamine	Infusion 5mg/mL	250 mg in 50mL N/saline	1.25–10 mcg/kg/min	1.6–4 mL/hour (~2–5mcg/kg/min)
Inoconstrictors				
Adrenaline/epinephrine	Bolus (Minjet®)	1 mg in 10 mL	PRN	0.5 mL bolus
<i>In extremis</i>				
<i>Increase BP and cardiac output</i>	Infusion	4 mg in 50 mL N/saline	Up to 50 mL/hour (titrate to effect)	2–5 mL/hour
Dopamine <i>As adrenaline</i>	Infusion	200 mg in 50 mL N/saline	1–10 mcg/kg/min	2–5 mL/h (~2–5 mcg/kg/min)
Ephedrine <i>As adrenaline. Slower onset (2–10 min) and longer lasting</i>	Bolus 3 mg/mL	Dilute 30 mg (1 mL) to 10 mL with N/saline	3–6 mg repeated every 3–4 min (max 30 mg)	1 mL
Vasoconstrictors				
Noradrenaline <i>'Pure' vasoconstriction— increase BP, little effect on CO</i>	Infusion	4 mg in 50 mL N/saline	Up to 50 mL/hour (titrate to effect)	2–5 mL/hour
Metaraminol <i>'Pure' vasoconstrictor Slow onset—max effect at 10 min</i>	Bolus	Dilute 10 mg (1 mL) to 10 mL with N/saline		0.5–5 mL bolus

Continuing investigation and treatment

If the underlying diagnosis is obvious, you can now initiate definitive treatment. Otherwise, the most useful investigation to perform next is an urgent echocardiogram which will inform on:

- LV dysfunction—MI, myocarditis, cardiomyopathy
- Wall-motion abnormalities—ischæmia
- Valvular/structural lesions
- Pericardial disease/tamponade; p.208
- Right-sided cardiac dilatation—PE (p.214), decompensated pulmonary hypertension; p.220

Other investigations might include:

- CT pulmonary angiogram (PE)
- CT thorax/abdomen (aortic/intra-abdominal pathology).

Monitoring and assessment of the circulation

For all conditions, is the circulation adequate?

- Ideally heart rate 60–100 bpm. Higher or lower rates may be acceptable if all other components of the circulation are adequate
- Mean arterial BP should be at least 60 mmHg to allow adequate cerebral perfusion (can be estimated by: diastolic + pulse pressure/3). Previously hypertensive patients may require a higher pressure to cerebral perfusion and pass urine
- Diastolic BP must be sufficient to allow myocardial perfusion (>35–40 mmHg, no ST depression on ECG)
- Urine output >0.5 mL/kg/h
- Capillary refill should be <2 sec
- Lactate concentration should be <2.0 mmol/L, preferably <1.6. If higher, it should fall in response to resuscitation.


Continuous positive airway pressure

In LV dysfunction, CPAP has pulmonary and cardiac benefits. It increases functional residual capacity, thus increasing the effective alveolar surface area and improving oxygenation, and, in most patients, reduces the work of breathing (caution if chest hyperinflated or restrictive chest-wall disease). Cardiac effects include a reduction in LV preload, improved ejection fraction, and reduction in MR.

Non-invasive ventilation

Non-invasive ventilation is more controversial and should probably not be applied in patients with LV failure. If CPAP is inadequate, it is often better to ventilate formally—seek anaesthetic help.

Intra-aortic balloon counterpulsation (aortic balloon pump)

IABP devices are mostly used in specialist cardiac units but are increasingly used in emergency departments and intensive care. They can be used to improve haemodynamics in cases of cardiogenic shock—indications and contraindications are listed in Box 1.2. See  p.374 for more details.

Box 1.2 IABP use (see also p.83 & p.374)**Indications**

- Cardiogenic shock
- Severe pulmonary oedema
- Acute LV dysfunction (e.g. MI) with severe cardiac failure
- Acute severe MR with cardiac failure, e.g. post-MI
- VSD with severe cardiac failure (esp. post-MI)
- Intractable myocardial ischaemia
- Support during CABG and coronary angioplasty.


Contraindications

- Significant AR
- Significant AS
- Hypertrophic obstructive cardiomyopathy with significant gradient
- Thoracic aortic pathology, e.g. dissection, aneurysm, clot
- Significant peripheral vascular disease—relative contraindication.

Cautions

- May sometimes worsen renal blood flow
- Peripheral vascular compromise can occur, usually affecting the leg on the side of insertion, though ischaemia of the contralateral limb can also occur. A cold, pale, and painful limb with reduced pulses demands immediate specialist attention.

Central venous monitoring

Central venous cannulae should be placed by the internal jugular or subclavian route into the SVC (not the RA),  p.362. This allows monitoring of right-sided filling pressures and the dynamic response to fluid challenges, repeated central venous blood gas estimation (of no value for pO_2 and pCO_2 but useful for tracking changes in pH and [lactate]), and estimation of central venous oxygen saturation ($ScvO_2$)

Central venous pressure

Normal CVP is approximately 4–8 cmH_2O and should reflect both RV and LV end-diastolic pressures. Changes in circulating volume, venoconstriction or dilatation, and pulmonary vascular disease may all mean that CVP does not reflect left-sided filling pressures.

► In all causes of shock, myocardial filling pressures need to increase to maintain stroke volume, but to an unpredictable degree.

Consequently, static measurement of CVP is of little value and it is better to measure the response to a volume challenge.

Fluid challenge

- The principle is that a fluid challenge will produce an initial rise in CVP but, when the infusion is completed, the fluid will redistribute and the CVP will then fall, particularly in hypovolaemia
- In well-filled patients, there will be a net increase in CVP which will be sustained
- By convention, 200 mL of colloid (500 mL of crystalloid) is given over 10–15 min, the CVP is measured before the infusion starts, immediately it is completed, and again 10–15 min later
- A sustained rise in CVP above baseline of $>3 cmH_2O$ indicates the circulation is well-filled
- An initial rise then a fall, or failure of the CVP to rise by $3 cmH_2O$ implies the circulation is empty and more fluid should be given.


Central venous oxygen saturation ($ScvO_2$) measurement

- If cardiac output is low in relation to tissue oxygen demand, more oxygen will be extracted per unit blood and the saturation of venous blood will fall
- A true mixed venous oxygen sample taken from the pulmonary artery reflects the balance between tissue oxygen delivery and consumption, a surrogate estimate can be obtained from the SVC (NB RA and IVC samples are not reliable)
- Normal $ScvO_2$ is approximately 80%
- Values $<70\%$ imply that cardiac output is low and, if there is other evidence of tissue hypoperfusion, there may be benefit in acting to increase cardiac output (e.g. with fluids and inotropes)
- If the $ScvO_2$ is $>70\%$, there is probably little value in increasing cardiac output further with inotropes.

Chest pain

- Diagnosing chest pain 14
- Patterns of presentation 15
- Associated physical signs 16
- Investigations 17






Diagnosing chest pain

The key is the pattern of features, as indicated on  p.15. Aspects to ask about, with more likely diagnoses, include:

- *Nature of the pain*: what is its quality, distribution, and severity?
 - Retrosternal, heavy/crushing/squeezing pain/ache—angina/MI
 - Sharp, lateral chest wall, easier to localize—pleuritic/muscular
 - Very localized sub-mammary pain—usually musculoskeletal
- *Associated features*:
 - Diaphoresis (sweating), breathlessness—IHD, PE
 - (Pre)syncope—PE?
 - Cough, sputum, haemoptysis—chest infection?
 - Superficial tenderness—musculoskeletal
- *Pattern of occurrence*—exacerbating and relieving factors:
 - Relationship to exertion—IHD, esp. if predictable
 - Emotional stress—can be IHD, or muscular tension
 - Eating—?gastro-intestinal source, but can be IHD too
 - Respiration—pleuritic
- *Change*:
 - In frequency or intensity of chest pain
- *Previous history*:
 - Of cardiac, respiratory, or upper gastrointestinal pathology? (May be related to this.)
- *Background risk*:
 - Medication—indicates diagnosis
 - Cardiac risk factors
 - Smoking history.

Causes of chest pain

Cardiovascular

- Angina/MI, see  p.39
- Pulmonary embolus, see  p.214
- Aortic dissection, see  p.189
- Pericarditis, see  p.204
- Myocarditis, see  p.84.

Non-cardiovascular

- Pneumonia—treat with antibiotics, O₂, physiotherapy etc.
- Pneumothorax—assess for aspiration/drainage
- Chest wall pain (pleuritic/musculoskeletal)—analgesia
- Muscular—analgesia
- Oesophageal reflux—proton-pump inhibitors required?
- Oesophageal rupture—urgent surgical review
- Nerve root pain
- Herpes zoster.

Patterns of presentation

Angina pectoris (📖 p.39)

Typically 'tight', 'heavy', 'band-like', or 'compressing' in quality with retrosternal location \pm radiation to (left) arm or throat and occasionally to the back or epigastrium. The severity is highly variable. Angina may not necessarily indicate coronary artery disease—aortic stenosis, LVOTO, and anaemia are all possible causes.

- Chronic stable angina is provoked by physical exertion, cold (leading to peripheral vasoconstriction), and emotional stress, and is relieved by rest. Sublingual GTN, where effective, will work within minutes
- Unstable angina (see 📖 p.62) occurs at rest or on minimal exertion and is more likely to be severe and sustained. Stuttering or rapidly increasing symptoms leading up to the acute presentation may occur and are termed crescendo angina. There may be associated 'autonomic' features, e.g. sweating and nausea \pm vomiting
- Sharp stabbing pains, pains that are well localized, e.g. left submammary, of fleeting duration e.g. <30 sec, or of flitting location are unlikely to reflect myocardial ischaemia.

Thoracic aortic dissection (📖 p.189)

Typically has abrupt, even instantaneous, onset. A tearing sensation from anterior to posterior in the chest may be described and the pain is severe and often terrifying. Other features may supervene, according to compromised vascular territories, e.g. angina, neurological symptoms due to carotid or spinal artery involvement. The usual cause is hypertension, which may be previously undiagnosed. Marfan syndrome is an important predisposition.

Pulmonary embolism (📖 p.214)

May present with pleuritic chest pain (sharp, localized, worse with inspiration) \pm associated breathlessness/haemoptysis. Large pulmonary emboli may diminish cardiac output to the extent that syncope occurs. Ask about risk factors such as prolonged immobility (travel, surgery—esp. orthopaedic), malignancy, postpartum, previous DVT/PE, personal or familial tendency to thrombosis, smoking, and oral contraceptive use.

Pericarditis (📖 p.204)

A gnawing, sore, retrosternal pain, often relieved by leaning forward (probably separates the inflamed pericardial layers). May also cause pleuritic pain. There may be associated 'viral-type' symptoms or features of the underlying disease. Breathlessness may indicate the accumulation of pericardial fluid, or tamponade.

Oesophageal pain

Can mimic angina to the extent that it may be associated with physical exertion and relieved by nitrates. Association with acid reflux, exacerbation when supine, with food or alcohol, and relief from antacids points towards oesophageal pain, but the distinction can be difficult and investigation is often required. Remember that meals can also provoke angina.

Associated physical signs

Unstable angina and acute myocardial infarction

(Also see  p.44, p.62.)

- Since things can change quickly it is important to document normal and negative findings clearly, so that new problems will be immediately apparent
- Note pulse (either tachycardia or bradycardia occur) and BP
- Pay attention for any signs of heart failure
- Record the heart sounds including any added sounds and the nature or absence of murmurs
- A rapid survey for neurological deficits is appropriate (as anticoagulation or thrombolysis may be indicated), with more detailed examination reserved for those where relevant abnormalities are identified.

Pulmonary embolism

(Also see  p.214.)

- Sinus tachycardia
- Hypotension
- Cyanosis
- Tachypnoea
- Low grade fever
- Palpable RV
- Loud pulmonary component of S_2 (loud P_2)
- Pleural rub
- Signs of DVT.

Pericarditis

(Also see  p.204.)

- Pericardial friction rub
- Check the pulse character
- Measure the BP yourself (pulsus paradoxus if systolic pressure difference through respiratory cycle >10 mmHg)
- Look for other signs of tamponade, e.g. hypotension, Kussmaul's sign (JVP rises on inspiration), and quiet or absent heart sounds.

Investigations

Investigations will reflect the possible diagnoses and complications based on the history and physical examination. They will also be directed towards risk factors and secondary prevention measures, e.g. cholesterol measurement and treatment in ischaemic heart disease. More detailed consideration of the investigation and management is given in the chapters that deal with each condition.

Unstable angina/acute myocardial infarction

(Also see  p.44, p.62.)

- FBC and U&E
- Glucose
- Total cholesterol and HDL cholesterol
- Troponin
- ECG
- Chest X-ray
- *Selected patients:* echocardiogram, coronary angiography.

Pulmonary embolism

(Also see  p.214.)

- FBC
- D-dimer
- Arterial blood gases
- ECG
- CXR
- *Selected patients:* CT pulmonary angiogram, ventilation perfusion (VQ) scan, echocardiogram, pulmonary angiogram, Doppler ultrasound leg veins, thrombophilia screen.

Aortic dissection

(Also see  p.189.)

- FBC and U&E
- Group and save blood/cross match
- ECG
- CXR
- Contrast CT thoracic and abdominal aorta
- *Selected patients:* TTE and/or TOE, MRI.

Pericarditis

(Also see  p.204.)

- FBC and U&E
- CRP
- Troponin
- ECG
- *Selected patients:* ANA, dsDNA, viral titres, pericardial fluid microscopy and culture, echocardiogram.

This page intentionally left blank

Shortness of breath

Diagnosing breathlessness 20

Investigations 22

Diagnosing breathlessness

► Ask about speed of onset, associated symptoms, previous cardiac and respiratory history, current medication, allergies, cardiac risk factors, smoking history. Obtain additional information from relatives, GP, notes.

► Read the ambulance sheet—it is a vital source of information.

Speed of onset

- Sudden —acute PE, arrhythmia, acute valve disease, pneumothorax, airway obstruction, anaphylaxis
- Minutes —angina / MI, pulmonary oedema, asthma
- Hours/days —pneumonia, exacerbation of COPD, congestive cardiac failure, pleural effusion
- Weeks/months —constrictive/restrictive cardiomyopathy, pulmonary fibrosis, pneumonitis, chronic PE
- Intermittent —asthma, LV failure, arrhythmias.

Associated symptoms









- Chest pain —ischaemic (angina, MI)
—pericarditic (pericarditis)
—pleural (pneumonia, PE)
—musculoskeletal (chest wall pain)
- Palpitation —AF is the commonest clinical arrhythmia
- Wheeze —asthma/COPD, anaphylactoid
- Orthopnoea, paroxysmal nocturnal dyspnoea —cardiac failure
- Sweats/weight loss —malignancy, infection
- Cough/sputum —pneumonia
- Haemoptysis —pink froth suggests pulmonary oedema
- Hyper-anxious —thyrotoxicosis, anxiety. Breathless that *only* occurs at rest is unlikely to be pathological.

Associated signs

- Clammy, pale —LV failure, MI
- Cardiac murmur —valve disease, but beware incidental murmur
- Crackles —early/coarse (pulmonary oedema, pneumonia)
—late/fine (fibrosis)
- Clubbing —malignancy, cyanotic congenital heart disease
—endocarditis, bronchiectasis
—pulmonary hypertension
- Cyanosis —severe hypoxaemia
- Displaced apex —LV dilatation
- RV heave —elevated right heart pressures
- Elevated JVP —right heart failure, fluid overload
—pericardial tamponade/constriction
—large PE
- Stridor —upper airway obstruction
- Peripheral oedema —right heart failure
- CO₂ retention flap —type 2 failure (see Box 3.1).

Box 3.1 Causes of breathlessness

Cardiovascular

- LV failure \pm pulmonary oedema  p.68
- Angina/MI  p.44
- Severe \pm acute \pm decompensated valve disease  p.94
- Arrhythmias (especially AF)  p.137
- Constrictive pericarditis/cardiac tamponade  p.208
- Restrictive/dilated cardiomyopathy  p.86
- Pulmonary embolus  p.214
- Pulmonary hypertension  p.220.

Non-cardiovascular

- Pneumonia
- Asthma
- COPD
- Pneumothorax
- Pleural effusion
- Upper airway obstruction
- Bronchial carcinoma
- Lymphangitis carcinomatosa
- SVC obstruction
- Pneumonitis/pulmonary fibrosis
- Anaemia
- Thyrotoxicosis
- Metabolic, e.g. acidosis
- Chest wall pain—pleuritic/musculoskeletal
- Skeletal abnormalities
- Neuromuscular—diaphragmatic weakness
- Central nervous system disorder—meningitis, pontine infarction, haemorrhage
- Anxiety/psychogenic.

Box 3.2 Respiratory failure

- Diagnosed if the $\text{PaO}_2 < 8$ kPa
- Subdivided according to the PaCO_2 :
 - Type 1: $\text{PaCO}_2 < 6.5$ kPa. Seen in virtually all acute disease of the lung, e.g. pulmonary oedema, pneumonia, asthma
 - Type 2: $\text{PaCO}_2 > 6.5$ kPa. The problem is hypoventilation. Neuromuscular disorders, severe pneumonia, drug overdose.

Investigations

- ECG—iskaemic changes, arrhythmias
- CXR
- Pulse oximetry
- Arterial blood gases
- FBC—anaemia, white cell count
- Cardiac enzymes—troponin, CK
- Further investigations according to differential diagnosis:
 - B-type natriuretic peptide—if low then cardiac failure unlikely
 - D-dimers—unlikely PE if negative
 - CRP
 - Renal function and electrolytes
 - Blood cultures if pyrexial
 - Peak expiratory flow rate
 - Spirometry \pm lung function testing—including gas transfer
 - Echocardiography—LV function, valve disease
 - CT—plain/pulmonary angiogram/high resolution.

Syncope

Introduction 24

Diagnosing syncope 24

Investigations 26

Neurally-mediated (vasovagal) syncope 28

Orthostatic hypotension 28

Cardiac syncope 30

Introduction

Syncope: a transient, sudden loss of consciousness, usually leading to falling.

Syncope can be caused by a wide spectrum of conditions, ranging from the benign faint to potentially fatal cardiac arrhythmias. The challenge is to identify those that require specialist management.

The underlying mechanism is hypotension due to a failure of cardiac output or a loss of peripheral vascular resistance. This results in reduced cerebral perfusion and lost consciousness. A 6–8 sec interruption to cerebral blood flow may be all that is required for syncope to occur. Syncope can occur without warning but, in some, there are prodromal symptoms such as nausea, sweating, loss of balance, or altered vision. Patients with true syncope do not remember hitting the ground.

1 in 4 of the population will have at least 1 episode of syncope.

Diagnosing syncope

► The history and examination are the most important steps in differentiating syncope from non-syncopeal causes of loss of consciousness.

- Conditions that mimic syncope, with a loss of consciousness include:
 - Epilepsy
 - Hypoglycaemia
 - Intoxication
- Some conditions without loss of consciousness may mimic syncope—falls, cataplexy, psychogenic syncope, transient ischaemic attacks
- Remember that many elderly patients with syncope describe the episodes as falls, often failing to recognize loss of consciousness.

Questions to ask

- Enquire about the 3 'P's':
 - *Provocative* factors (fatigue, dehydration, warm atmospheres, emotional circumstances, fear, pain)
 - *Prodromes* (nausea, sweating, giddiness, abdominal discomfort)
 - *Postural* components (standing, sitting, or lying)
- Try to obtain a witness account of the episode. Ask about the appearances of the patient during the episode. Was there pallor? Was there seizure activity and if so for how long? Remember that short-lived seizures and myoclonic jerks often occur in simple vasovagal syncope
- How long did the episode last? Arrhythmic syncope can be very brief with almost immediate recovery such as intermittent AV block (Stokes–Adams attacks). Vasovagal episodes tend to be a little longer although these too can be quite short lived
- How long did the patient take to recover and how did they feel? Was there confusion? Following vasovagal episodes patients may report nausea/vomiting and prolonged light headedness with recurrent syncope or presyncope if they stand too quickly. They may also feel profound tiredness which can last for hours and often patients report sleeping in the immediate aftermath of episodes.

Box 4.1 Causes of syncope

Neurally-mediated syncope and orthostatic hypotension are the cause of >50% of cases of syncope. Cardiac causes represent 15% of cases. Neurological and psychiatric causes are found in 10%.

Neurally-mediated (reflex) syncope

- Vasovagal syncope:
 - Classical (simple faints)
 - Non-classical (unprovoked)
- Situational syncope:
 - Swallow, cough, micturition
- Carotid sinus hypersensitivity.

Orthostatic hypotension

- Autonomic failure:
 - Primary (e.g. pure autonomic failure, multi-system atrophy and Parkinson plus syndromes)
 - Secondary (diabetes mellitus)
- Drug induced (vasodilator therapy)
- Volume depletion (diuretics, fluid loss, and Addison disease).






Cardiac arrhythmia

- Sinus node dysfunction (📖 p.142)
- AV block (📖 p.146)
- Paroxysmal arrhythmias (📖 p.152)
- Inherited syndromes e.g. long QT, Brugada syndrome (📖 p.177, p.182)
- Drug-induced bradycardia or prolonged QT interval (📖 p.183, p.344).

Other cardiovascular

- Obstructive valvular disease, e.g. AS (📖 p.102)
- LV outflow obstruction, e.g. hypertrophic cardiomyopathy (📖 p.86)
- Aortic dissection (📖 p.189)
- Pericardial tamponade (📖 p.208)
- Pulmonary hypertension (📖 p.220)
- Pulmonary embolus (📖 p.214)
- Atrial myxoma (📖 p.352).

Investigations

- 12-lead ECG. Abnormalities suggesting a cardiac cause include:
 - Q waves (prior MI)
 - LBBB or RBBB and left anterior or posterior hemiblock
 - AV block (2° or higher)  p.146
 - Sinus bradycardia (<50 bpm) or sinus pauses >3 sec
 - Pre-excitation (short PR interval and delta wave)  p.174
 - Prolonged QT interval  p.183, 344
 - Widened QRS (>0.12 sec)
 - RBBB with ST elevation in V1–V3 (Brugada syndrome)  p.177
- CXR—cardiac enlargement or aortic dissection ( p.189)
- Routine blood testing (except plasma glucose) has a low yield
- Carotid sinus massage (Box 4.2)
- *In selected patients:* echo, 24-hour tape.

Who needs a 24-hour ECG tape?

Prolonged ECG monitoring is available in most hospitals. However, the diagnostic yield is low in unselected patients with syncope, and will be most beneficial in those with frequent symptoms or in whom you have a high suspicion of a cardiac cause. Factors which suggest a cardiac cause include a history of cardiac disease, an abnormal ECG, or abnormal echo.

Who should be admitted?

Most patients who present following a single episode of syncope can be investigated as an outpatient. In hospital monitoring and investigation is warranted if the initial clinical evaluation suggests significant structural heart disease or when syncope is recurrent or disabling. Patients without clinical evidence of structural heart disease and no family history of sudden death who present with an isolated episode of classical vasovagal or situational syncope can be discharged back to their GP without the need for any specific follow-up. All other patients should be referred on for further evaluation as an outpatient.

Box 4.2 Carotid sinus massage

- Used to diagnose carotid sinus hypersensitivity
- Perform with continuous ECG recording and (ideally) beat-to-beat BP monitoring since BP changes are rapid
- With the patient supine, pressure is applied to each carotid sinus in turn for 10–20 sec. If no abnormal response is elicited, the procedure can be repeated with the patient tilted upright
- Avoid in patients with a history of recent stroke (<3 months), carotid bruits, or known carotid vascular disease.

Carotid sinus hypersensitivity is defined as a ventricular pause of >3 sec or a drop in systolic pressure of >50mmHg.

Carotid sinus syndrome is the combination of syncope and carotid sinus hypersensitivity, in a patient in whom clinical evaluation and investigation has identified no other cause of syncope.

Box 4.3 Tilt table testing

- A provocation test for neurally-mediated syncope
- There are a number of protocols in use in clinical practice varying in the angle of tilt (typically 60–70 degrees head-up), the duration of tilt (20–45 min), and the use of additional provocation (sublingual GTN).
- Both false positives and false negatives can occur but the test compares favourably with other non-invasive cardiac investigations
- Tilt testing is very likely to be positive in those with obvious classical vasovagal episodes
- However, the diagnosis is rarely in doubt in such patients and tilt testing has a much more important role in investigating patients with recurrent unexplained syncopal episodes and in the investigation of patients with a broad range of disturbances of consciousness where the cause is unclear (e.g. is it really epilepsy?).

② **Neurally-mediated (vasovagal) syncope**

- Loss of consciousness in vasovagal syncope is typically for <30 sec although patients and relatives usually report longer
- Likely in the absence of cardiac disease and if there are provoking factors, associated prodromal autonomic symptoms or syncope occurs with head rotation (carotid sinus pressure)
- Situational syncope occurs when directly linked with swallowing, micturition, or coughing.

Investigations

- Carotid sinus massage (Box 4.2)
- Tilt-table testing (Box 4.3).

If tests are negative and symptoms recur then consider prolonged ECG monitoring or an implantable loop recorder (see Fig. 4.1).

Management

Carotid sinus syndrome usually responds well to dual chamber permanent pacing.

For other neurally-mediated syncope, treatment is less straightforward and patients should be referred for specialist advice.

- Non-pharmacological measures are the first-line treatments for patients with vasovagal syncope. These include education, reassurance, tilt-training (enforced upright posture), leg crossing, or hand grips during prodromes (to delay or avoid loss of consciousness)
- Pacing for vasovagal syncope can reduce symptoms in selected patients but patients must be informed that it does not prevent attacks
- Pharmacological agents have an unpredictable response and include beta-blockers, fludrocortisone, midodrine, and fluoxetine.

② **Orthostatic hypotension**

Commonly occurs shortly after standing up, or after prolonged standing typically in a hot crowded room. Can occur after exertion. A systolic blood pressure drop of >20 mmHg after 3 min of standing or a drop to <90 mmHg is defined as orthostatic hypotension, irrespective of whether symptoms occur.

The commonest cause is vasodilator drugs and diuretic therapy, especially in the elderly.

Reveal(R) Plus Model 9526

Storage Mode: 3 patient, 5 auto events, 42 min. (c) Medtronic, Inc

Patient Event 1 of 2 recorded

12.5 mm/sec, 25.0 mm/mV

▲=Activation point

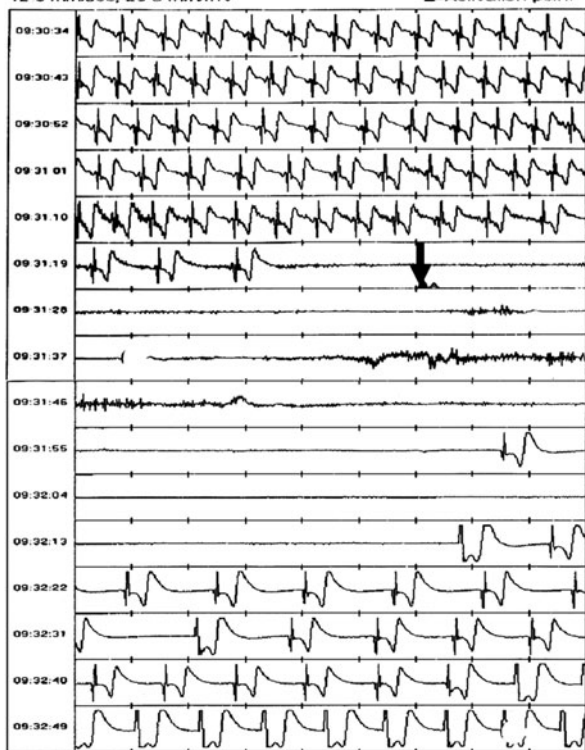


Fig. 4.1 ECG printout downloaded from an implantable loop recorder in a patient with neurocardiogenic syncope. The patient has activated the recorder (black arrow) soon after the onset of sinus arrest. After nearly 1 min of asystole, sinus rhythm returns. The early activation point suggests that the patient had a period of associated autonomic or hypotensive symptoms prior to bradycardia.

! Cardiac syncope

- Likely if syncope occurs in the presence of severe structural heart disease, particularly severe LV impairment
- Syncope in patients with poor cardiac function confers a bad prognosis
- Symptoms can occur at any time
- May be provoked by exertion
- Can occur whilst sitting or supine
- Can be associated with palpitation or chest discomfort.

Investigations

- Echocardiography
- Prolonged ECG monitoring
- *In selected patients:* electrophysiological studies
- Syncope occurring during effort should be investigated with echocardiography and exercise stress testing.

Important causes of cardiac syncope

- ▶ Urgent cardiology referral is required.
- **Severe LV impairment:** associated with monomorphic VT, atrial arrhythmias, postural or drug-induced hypotension.
- **AS:** exertional syncope resulting from severe AS is associated with a high incidence of sudden death. See 📖 p.102
- **Hypertrophic cardiomyopathy:** syncope occurs in up to 25% of patients and can be a risk marker for SCD. See 📖 p.86
- **Long QT syndrome:** episodes of polymorphic VT can result in recurrent syncope. See 📖 p.182, 344
- **Brugada syndrome:** a cause of SCD. ST elevation is seen in the right precordial leads (V1–V3) but changes can be dynamic. See 📖 p.177, 425.

Reference

1. Guidelines on Management (diagnosis and treatment) of syncope – update 2004: The Task Force on Syncope, European Society of Cardiology. *Europace* 2004; **6**: 467–537.

Driving and lifestyle restrictions

⚠ Documented advice on driving *must* be given to each patient presenting with syncope. Restrictions for driving should be reviewed according to national guidelines as updates are made frequently. In general, driving should cease for at least 4 weeks after an episode of unexplained syncope. If no cause has been identified then a period of at least 6 months without driving is usually recommended.

Weblink

In the UK, the Driver and Vehicle Licensing Agency issue guidelines for medical practitioners:  <http://www.dvla.gov.uk/medical/ataglace.aspx>

Other lifestyle restrictions

Patients should be advised to avoid situations where syncope would be hazardous, e.g. working up a ladder.

This page intentionally left blank

Palpitation

Diagnosing palpitation 34

Investigations 36

General management 36

Diagnosing palpitation

Definition

Palpitation is the symptom of an increased awareness of the heartbeat.

The term however is interpreted by patients to mean different things and it is important to elicit exactly what the patient's symptoms are.

The history is vital. A good history can often provide the diagnosis and may avoid the need for further investigation, especially if a non-cardiac cause is suspected. ECG documentation of the cardiac rhythm during an episode is proof of the diagnosis—if this is normal, an arrhythmic cause for the symptoms can be excluded.

In general, if the symptoms are brief (<10 sec), not associated with other severe symptoms, and/or occur only at times of stress/anxiety, it is unlikely there is a concerning cause for them.

1. Clarify the symptoms—ask the patient to ‘tap out’ the rhythm

- Pounding heart—may be physiological
- Sudden one-off ‘jump’—unimportant, likely ectopic beat
- Irregular heart beat—likely multiple ectopic beats or AF
- Fast heart rhythm—consider tachyarrhythmia.

2. What is the pattern?

- Abrupt onset/cessation
- Slow increase/decrease
- At times of stress/anxiety
- Related to exertion
- Early beat, pause, then heavy beat
- Irregular rhythm

Likely cause(s) (Box 5.1)

SVT, VT, AF
Sinus tachycardia
Anxiety/emotion
Sinus, AF, SVT if abrupt onset
Atrial/ventricular ectopic beats
AF, multiple ectopic beats.

3. How often does it occur?

- Useful for determining impact on patient
- Guides choice of investigation

4. Duration of symptoms

- Brief (few seconds)
- Several minutes/few hours
- Continuous

Likely cause(s) (Box 5.1)

Atrial/ventricular ectopics
SVT/AF
Sinus tachycardia/thyrotoxicosis.





5. Associated symptoms (warrant further cardiac investigation)

- Angina
- Syncope or near syncope
- Significant breathlessness.

6. Previous history

- Known poor LV function—VT more likely
- Previous SVT/AF/VT—recurrence?

Box 5.1 Causes of palpitation**Cardiac**

- Tachyarrhythmia:
 - AF, see  Atrial fibrillation, p.160
 - Atrial flutter, see  p.166
 - SVT, see  p.170, 172
 - VT, see  p.178
- Ventricular or atrial ectopic beats.

Non-cardiac

- Sinus tachycardia—pain, anxiety, fear, exertion, hypoxia, infection, hypovolaemia (e.g. dehydration), anaemia, thyrotoxicosis, see p.158
- Thyrotoxicosis—appropriate referral to endocrine team. Consider beta-blockade (propranolol 40 mg QDS PO) ± carbimazole (40 mg daily PO) if severe (HR >140 bpm)
- Gastro-oesophageal reflux
- Anxiety/emotion
- Rare:
 - Pheochromocytoma
 - Carcinoid syndrome.

Investigations

12-lead ECG

Ideally during symptoms.

Blood tests

- FBC—anaemia → sinus tachycardia?
- Thyroid function—thyrotoxicosis?
- U&E—low/high K^+ ? (encourages arrhythmias).

Assuming that by this stage, you think a true arrhythmia may be present, further investigations may be undertaken:

Echocardiogram

Identifies any structural heart disease.

Ambulatory ECG monitoring

ECG documentation of an arrhythmia prior to management is crucial—treatment is only appropriate when you know what you're dealing with! Assuming this has not been obtained previously, it is worth considering ambulatory monitoring to attempt to document the rhythm during a symptomatic episode. It is worth persevering until an ECG is recorded during symptoms.

24/48-hour ECG monitor

Good for frequent symptoms, may need several before rhythm identified.


Patient-activated event recorder

The ECG is stored during an episode and can be downloaded to the ECG department over the telephone. The device may be kept for several weeks ∴ good for less frequent episodes. Patient needs to be alert during episode and capable of operating device.

Implantable loop recorders

A small device implanted under the skin in pectoral or axillary region. It typically records 40 min of ECG, 'frozen' by a patient-activated key or stored automatically. Good for infrequent but severely symptomatic events.

General management

- Establish rhythm and treat accordingly (see  Box 5.1, p.35, for relevant sections)
- Most investigations are best performed on an outpatient basis
- Admit if significant associated symptoms for further investigation and ECG monitoring:
 - Severe chest pain
 - Severe SOB
 - Syncope/near syncope.

Part 2

Specific conditions

Chapter 6	Acute coronary syndromes	39
Chapter 7	Acute heart failure	67
Chapter 8	Valve disease	93
Chapter 9	Infective endocarditis	121
Chapter 10	Arrhythmias	137
Chapter 11	Aortic dissection	189
Chapter 12	Pericardial disease	203
Chapter 13	Pulmonary vascular disease	213
Chapter 14	Systemic emboli	227
Chapter 15	Cardiac issues in pregnancy	235
Chapter 16	Adult congenital heart disease	253
Chapter 17	Perioperative medicine	291
Chapter 18	Cardiac drugs	309
Chapter 19	Miscellaneous conditions	347

This page intentionally left blank

Acute coronary syndromes

Introduction	40
Pathophysiology	40
Coronary artery anatomy	42
Acute STEMI	44
Reperfusion therapy for STEMI	48
Additional treatments	54
Risk stratification and prognosis	54
Complications of acute MI	56
Post-infarct management	60
Unstable angina and NSTEMI	62
Recent percutaneous coronary intervention	66

Introduction

Acute coronary syndromes (ACS) are a collection of clinical conditions involving acutely compromised myocardial perfusion (Table 6.1):

- ST segment elevation myocardial infarction (STEMI)
- Non-ST segment elevation myocardial infarction (NSTEMI)
- Unstable angina—an ACS without myocardial damage as indicated by elevation of troponin or cardiac enzymes.

Pathophysiology

Understanding the pathophysiology helps to explain the spectrum of presentation and underpins rational treatment.

Chronic stable angina occurs when fixed stenotic lesions impede myocardial perfusion at times of ↑oxygen demand.

ACS occur when erosion or rupture of the ‘fibrous cap’ overlying an atherosclerotic lesion exposes intensely thrombogenic material within the plaque to platelets and coagulation factors in the blood. These lesions need not be stenotic prior to the acute presentation, which explains why many ACS events are unheralded. The nature of the occlusion (partial or total; transient, intermittent, or fixed) and location (proximal or distal and the specific coronary artery affected) largely determine the clinical presentation and course.

Non-atherosclerotic causes of acute MI

These warrant consideration in specific patients but are less common:

- Embolus, e.g. vegetation in infective endocarditis
- Spontaneous coronary dissection
- Intense spasm, e.g. in cocaine abuse
- Coronary arteritis, e.g. Kawasaki disease
- Thrombosis *in situ* in pro-coagulable states
- Trauma—avulsed coronary artery
- Aortic dissection
- Iatrogenic due to coronary intervention.

Table 6.1 Classification of ACS

	Troponin	ECG
STEMI	↑ or ↑↑	ST elevation LBBB
Non-STEMI	↑ (occasionally ↑↑)	Normal Abnormal, but unchanged ST segment depression T-wave inversion
Unstable angina	↔	

Box 6.1 Risk factors for coronary atherothrombosis

- Tobacco smoking
- Family history
- Diabetes mellitus
- Hypertension
- ↑ low-density lipoprotein (LDL)-cholesterol
- ↓ high-density lipoprotein (HDL)-cholesterol.

Additional risk factors

- Elevated markers of inflammation, including CRP, interleukin-6, and tumour necrosis factor
- Central obesity
- Sedentary lifestyle
- High apolipoprotein B (ApoB)
- Low apolipoprotein AI (ApoAI)
- High lipoprotein (a) [Lp(a)]
- High plasma homocysteine.

Coronary artery anatomy

The origins of the coronary arteries can be seen in Fig. 6.1

The **left anterior descending** (LAD) coronary artery runs in the anterior interventricular groove supplying the anterior wall of the heart. It gives off **septal** branches that supply blood to the anterior 2/3 of the interventricular septum, including the left bundle branch; **diagonal** vessels to the lateral wall of the LV; and a terminal bifurcation that supplies the apex of the LV and sometimes wraps around to supply the inferior wall of the LV.

The **circumflex** (LCX) artery runs posteriorly in the left AV groove and gives **obtuse marginal** branches to the lateral wall of the LV, supplying the posterior wall of the LV.

The **right** coronary artery (RCA) runs in the right AV groove. It gives branches to the sinoatrial node, AV node, and RV. On reaching the posterior interventricular groove, it gives rise to the **posterior descending artery** that supplies the inferior wall of the LV, and the inferior 1/3 of the interventricular septum. This is the more common variant. In about 10% of patients, the circumflex gives rise to the posterior descending artery and is then termed 'dominant'.

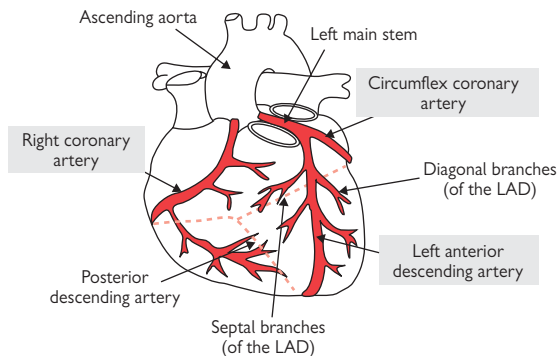


Fig. 6.1 Coronary artery anatomy. There are three principal coronary arteries. The left main stem arises from the left aortic sinus and soon gives rise to the (1) left anterior descending and (2) circumflex coronary arteries. The (3) right coronary artery normally has a separate origin in the right aortic sinus.

Table 6.2 Coronary artery territories

Site of arterial occlusion	Myocardial territory	ECG changes
LAD	Anterolateral	V4–V6, I, VL
	Anteroseptal	V1–V4 LBBB
LCX	Posterior	Mirror image changes in V1–V2 or V3, i.e. ST segment depression \pm inferior changes; tall R in V1 May be electrically silent on standard 12-lead ECG
RCA	Inferior wall of LV	II, III, aVF
	RV	ST elevation V4R to V6R

Acute STEMI


This is a medical emergency usually caused by thrombotic occlusion of a major epicardial coronary artery. Irreversible ischaemic injury to the myocardium is threatened (or may have occurred at presentation). Prompt action conserves myocardium and prevents complications, including death.

The optimal treatment of acute STEMI should be based on the implementation of an emergency system that is planned and agreed locally, taking into account local geography, ambulance provision, medical facilities, and expertise for the appropriate delivery of 1° angioplasty. Pre-hospital diagnosis is desirable in most models of care.

Symptoms

- Severe ‘crushing’ central chest pain ± radiation to jaw, neck, or arms
- ‘Autonomic’ features: diaphoresis (sweating), nausea, and vomiting
- Breathlessness due to LV dysfunction
- Atypical presentations include pain in the back or abdomen, confusion
- MI may be silent (especially in the elderly and in patients with diabetes).


Determine:

- Current haemodynamic status
- Timing of the onset of symptoms
- Are there contraindications to thrombolysis? ( Box 6.3, p.53)
- Has aspirin been given, e.g. in ambulance?
- Is there a history of coronary disease?

Signs


- Pain or distress
- Clammy (sweating and cutaneous vasoconstriction) and grey.

Look for complications:

- Hypotension
- Lung crepitations and other evidence of heart failure
- Rhythm disturbances—bradycardia, e.g. heart block; AF, sinus tachycardia (pain, anxiety, or compensatory)
- Murmurs—MR due to papillary muscle ischaemia or chordal rupture; acquired VSD ( p.57)
- Fever <38°C is common in the first 48 hours.

Investigations

12-lead ECG (Fig. 6.2)

- If ST segment elevation is present, a rapid decision on revascularization is required. See  Indications for revascularization, p.48
- In patients with inferior MI, right-sided ECG leads should be obtained, to identify possible RV infarction
- Where ECG diagnostic criteria are not met initially, but pain persists, obtain serial ECGs every 10 min
- ECG monitoring should be initiated as soon as possible to facilitate immediate diagnosis and management of life-threatening arrhythmias.

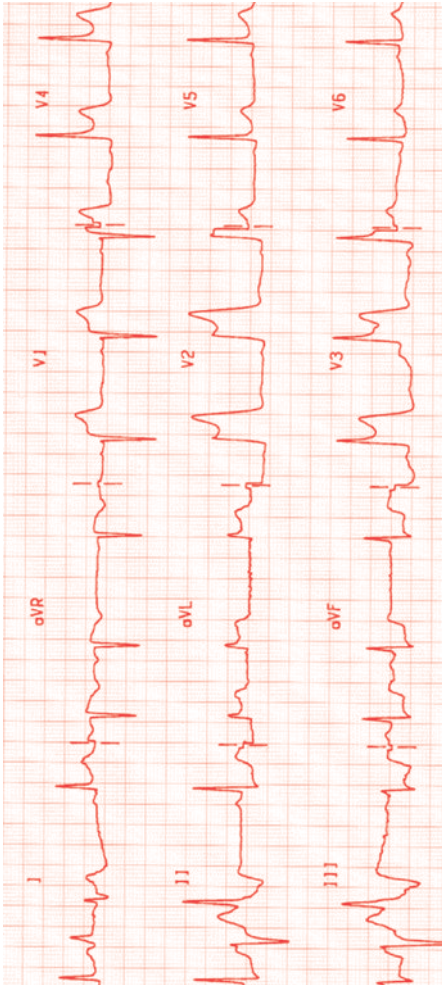


Fig. 6.2 ECG in acute anterolateral MI. There is marked ST segment elevation in leads V1–V4 and aVL. Reciprocal ST segment depression is present in leads II, III, and aVF.

Other investigations

- If diagnostic uncertainty persists, echocardiography can be helpful, since segmental hypokinesis occurs early in the course of acute ischaemia (though can not be differentiated with certainty from chronic dysfunction). However, treatment should not be significantly delayed waiting for an echocardiogram.
- A portable chest radiograph should be obtained but, where the clinical diagnosis is acute MI, CXR should not delay reperfusion therapy
- Blood for troponin (Box 6.2), and repeated 12 hours after symptom onset. In acute MI, initial treatment decisions are **not** dependent on blood test results
- FBC, U&E, serum cholesterol, and glucose. Remember that serum cholesterol may decrease after 24 hours and persist at lower level for several weeks following an acute MI.

Immediate management

- ▶ Your patient may be terrified. Provide reassurance where possible.
- Oxygen
- Aspirin 150–300 mg. Chewed for rapid buccal absorption
- Clopidogrel 300–600 mg PO loading dose (see 📖 p.50)
- IV access
- Diamorphine 2.5–5 mg IV or morphine 5–10 mg IV
- Metoclopramide 10 mg IV
- Oral β -blocker e.g. atenolol 50 mg PO or metoprolol 25–50 mg TDS in the absence of heart failure and hypotension (BP <100 mmHg). IV β -blockers, e.g. metoprolol 5mg IV followed by further 5mg IV if required can also be used, particularly to counter tachyarrhythmias or marked hypertension.
- ▶ **Reperfusion therapy:** 1° PCI or thrombolysis (see 📖 p.48).

Important differential diagnoses

- ⚠️ **Aortic dissection** (📖 p.189) can present with chest pain and ST segment elevation. The pain is usually distinguished by its abrupt onset, migration to the back, and tearing nature. Where ST segment elevation is recorded, it is usually in the inferior (i.e. right coronary) territory since dissection involving the left main stem is usually fatal.
- ⚠️ Thrombolytic therapy in acute aortic dissection is potentially lethal. Where there is significant suspicion of dissection, further imaging (e.g. contrast CT aorta, TOE, or MRI) should be obtained.
- ⚠️ **Acute pericarditis** (📖 p.204) may present with chest pain and ST segment elevation on the ECG. The pain is typically exacerbated by inspiration and relieved by sitting upright. The ECG changes are classically concave upwards (saddle shaped) and may be widespread, spanning the equivalent of multiple coronary territories.

Box 6.2 Interpreting the troponin measurement

Troponins are contractile proteins, specific to the myocardium, and elevated levels in the blood are indicative of myocardial injury. Levels rise within 12 hours of myocardial injury, peak at around 24 hours, and remain elevated for up to 14 days.

It is important to recognize that the diagnosis of ACS is, in the first instance, clinical—the initial management is based on clinical diagnosis and the ECG(s) and is not contingent on the troponin result. The troponin may turn out to be elevated and in NSTEMI patients is one of the markers of ↑risk (📖 Box 6.4, p.65), but importantly, may be normal in patients with unstable angina who are at high risk of subsequent cardiac events, and the clinical diagnosis is crucial in these patients.

Furthermore, release of troponin T is not specific to coronary disease. Caution is necessary in interpreting an elevated serum troponin in the absence of a typical history and/or ECG changes, particularly where the rise is relatively modest. Other conditions that can lead to troponin elevation include:

- Myocarditis
- Pericarditis
- PE
- Sepsis
- Renal failure.

Because of superior specificity, troponin measurement has largely superseded measurement of other biomarkers of myocardial damage—CK, AST, and LDH.

Reperfusion therapy for STEMI

Reperfusion therapy with thrombolysis or with PCI should be performed according to local policies (see Fig. 6.3), with which you should be familiar. The goals are prompt restoration of coronary flow and myocardial perfusion. Rapid action is vital: the door-to-needle time (thrombolysis) should be <20 min and the door-to-balloon time (for 1° PCI) should be <60 min. Most hospitals have multidisciplinary teams to accelerate provision of reperfusion therapy. Delays increase myocardial necrosis, decrease the efficacy of eventual reperfusion therapy, and increase mortality.

Indications for reperfusion therapy

- Symptoms of myocardial ischaemia
- Onset within the prior 12 hours (or up to 24 hours if symptoms of ischaemia persist)
- ST segment elevation of >0.1 mV (usually 1 mm) in at least two adjacent limb leads *or*
- ST segment elevation of >0.2 mV (usually 2 mm) in at least two contiguous chest leads *or*
- New (or presumed new) LBBB *or*
- True posterior MI*.

*Posterior MI is notorious for the absence of definitive ECG changes. ST segment depression in leads V2 and V3—particularly in the context of concomitant inferior and/or lateral ST segment elevation—should suggest posterior MI, where the clinical syndrome fits. If the changes are inconclusive, an echocardiogram may help.

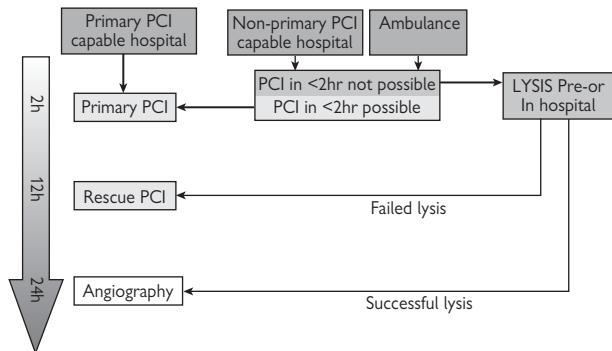


Fig. 6.3 Reperfusion therapy decision tree. Upper tier boxes represent site of first medical contact. For patients presenting within 2 hours of symptom onset, the benefit of treatment is greatest and immediate treatment is mandatory. In patients with successful thrombolysis, angiography should not be undertaken within 3 hours. The grey arrow indicates time limits. Adapted from Van de Werf F et al. Management of acute myocardial infarction in patients presenting with persistent ST-segment elevation: The Task Force on the management of ST-segment elevation acute myocardial infarction of the European Society of Cardiology. *Eur Heart J* 2008;**29**:2909–45.

Primary PCI

1° PCI refers to immediate PCI as the initial reperfusion strategy. It achieves high levels of vessel patency and, in experienced hands, may reduce mortality compared to thrombolysis. The risk of stroke is also lower compared to thrombolysis.

- Initiate immediate management measures (📖 p.46)
- Clopidogrel should be given in patients heading for 1° PCI. To effect more rapid onset of action, a loading dose of 600 mg should be given followed by 75 mg daily thereafter
- Alert the cardiac catheterization laboratory/duty cardiologist at the earliest opportunity, ideally at 'first medical contact' and, if possible, before the patient has arrived in the hospital
- Ideally the patient is moved from the ambulance (or Emergency Department) directly to the cardiac catheterization laboratory
- Informed consent is usually obtained by the operator or a competent deputy
- If there is likely to be more than minor delay (i.e. >60 min door-to-balloon) before PCI, thrombolysis may be more appropriate, particularly if the symptom duration is <3 hours.

In the catheterization laboratory

- The purpose is restoration of myocardial perfusion as soon as possible
- Intra-coronary thrombus aspiration catheters have been shown to be of benefit in acute STEMI
- Many patients will receive IV glycoprotein (GP) IIb/IIIa receptor inhibitors (abciximab) by bolus injection and by infusion in the hours following PCI
- The HORIZONS-AMI trial suggested reduced bleeding complications through use of the direct thrombin inhibitor, bivalirudin (with provisional use of GP IIb/IIIa blocker) vs. heparin plus a GP IIb/IIIa blocker.

Facilitated 1° PCI

- This is the practice of using full or partial dose lytic therapy prior to 1° PCI. This practice is **not** currently recommended, due to lack of benefit and excess bleeding complications
- Similarly, the vessel patency rates with up-front (pre-cardiac catheterization laboratory) GP IIb/IIIa receptor inhibition have not improved long-term outcome. Their use is also not routinely indicated.

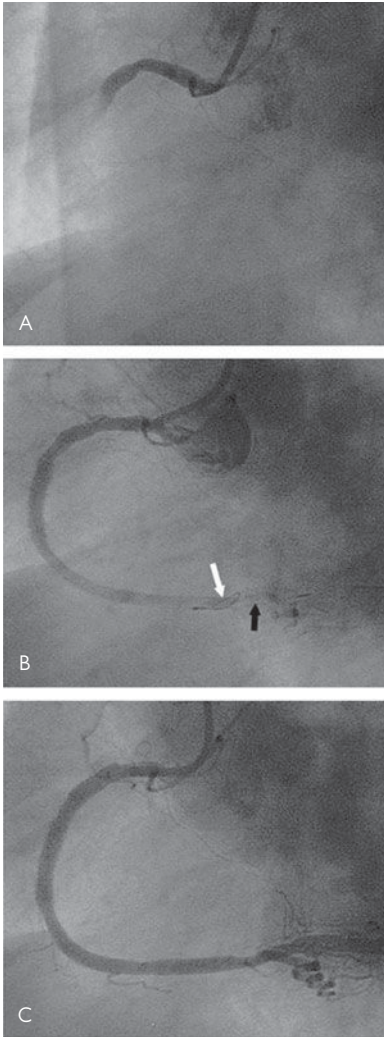


Fig. 6.4 (A) Acute MI with occlusion of the RCA. A small filter device (B, arrows) captures embolic debris released during PCI. Stent deployment at the site of occlusion restores vessel patency and distal flow (C).

Thrombolysis

Practical considerations mean that for many hospitals, thrombolysis is the standard reperfusion treatment. In some areas, pre-hospital thrombolysis is delivered by community physicians or paramedics.

Even where thrombolysis is the usual reperfusion strategy, 1° PCI should be considered in patients with contraindication to thrombolysis or those <75 years old, with shock, and within 36 hours of an acute MI.

Angiographic patency and flow at 90 min in the infarct-related artery are directly related to 30-day mortality. Patency is at best only 80% at 90 min with thrombolysis. Reperfusion is suggested by relief of pain and resolution of ST segment elevation following thrombolysis by >50%.

- Exclude contraindications (Fig. 6.5) and warn of the small risk of stroke (1%) or major bleeding (5–10%)
- Avoid arterial punctures, multiple venous punctures, and IM injections in patients where thrombolysis is likely.

Choice of thrombolytic

Alteplase (rtPA) accelerated regimen (<6 hours from symptom onset):

- If >65 kg body weight (weight-adjust dose if <65 kg)
- 15 mg by IV bolus followed by:
 - 50 mg over 30 min, then
 - 35 mg over 60 min (i.e. total 100 mg over 90 min).

This should be followed by an IV bolus and infusion of unfractionated heparin (UFH) (trials on the use of LMWH are ongoing)

Alternatively:

- Streptokinase 1.5 million units IV over 60 min
- Tenecteplase (TNK) 500 mcg per kg (max 50mg) IV over 10 sec
- Reteplase 10 units IV over not more than 2 min followed by 10 units 30 min later.

All reduce mortality. Alteplase, tenecteplase, and reteplase have equivalent efficacy and are more powerful thrombolytics, resulting in 10 fewer deaths per 1000 patients treated, but at the expense of 3 additional strokes compared to streptokinase.

Failure to reperfuse

Ongoing ischaemic symptoms and/or persistent ST segment elevation (>50% in the lead of greatest ST elevation, 60–90 min after thrombolysis) may result from a failure to achieve patency of the epicardial vessel or due to distal (microvascular) occlusion.

- These patients should undergo emergency (rescue) PCI, with transfer to the local PCI centre, if required (based on the findings of the REACT trial)
- If rescue PCI is not available and a large infarction is in process or threatened, and the risk of bleeding is assessed not to be high, a second administration of thrombolytic can be considered, although the REACT trial showed no benefit from repeat thrombolysis over conservative management (NB streptokinase should not be given more than once).

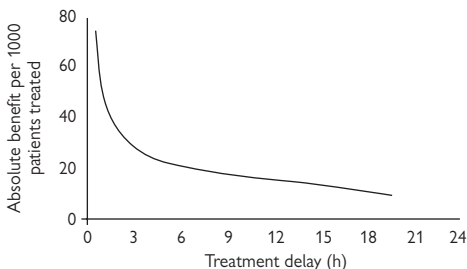


Fig. 6.5 Summary of meta-analysis of thrombolysis trials shows the marked time sensitivity of thrombolysis particularly within the first 'golden' 2 hours after the onset of pain. Modified from Boersma E *et al.* Early thrombolytic treatment in acute myocardial infarction: reappraisal of the golden hour. *Lancet* 1996; **348**: 771–5.

Box 6.3 Contraindications to thrombolysis

Absolute

- Any prior intracranial haemorrhage
- Known intracranial structural vascular lesions (e.g. arteriovenous malformation)
- Known intracranial malignant neoplasm (1° or 2°)
- Ischaemic stroke within 3 months
- Active bleeding or bleeding diathesis
- Significant head trauma within 3 months.


Relative

- Severe hypertension (systolic >180 mmHg; diastolic >110 mmHg) despite treatment
- Traumatic or prolonged CPR
- Major surgery within 3 weeks
- Non-compressible vascular punctures
- Recent (within 2–4 weeks) internal bleeding
- Pregnancy
- Active peptic ulcer
- Current anticoagulant use
- Pain for >24 hours
- For streptokinase: prior exposure to streptokinase (persistent antibodies).

► NB Patients with contraindications to thrombolysis should be considered for 1° PCI

Modified from Antman EM *et al.* ACC/AHA guidelines for the management of patients with ST-elevation myocardial infarction. *Circulation*, 2004; **110**: 588–636.

Additional treatments

- An ACE inhibitor (e.g. ramipril 2.5 mg BD or lisinopril 5 mg OD) should be commenced within the first 24 hours following acute MI if the systolic BP is >100 mmHg. There is particular benefit in the presence of LV dysfunction. The dose should be titrated upwards as BP permits
- Statin treatment should be instigated in almost all patients
- The antiplatelet agent clopidogrel administered at presentation and continued at a dose of 75 mg daily for 4 weeks, in addition to standard therapy, reduces the 30-day risk of a composite of death, reinfarction, and stroke inpatients undergoing non-invasive management. In patients receiving stents, see  p.60
- In post-STEMI patients with LV ejection fraction <40%, already receiving an ACE inhibitor and with either symptomatic heart failure or diabetes, but without significant renal dysfunction or hyperkalaemia, there is a benefit from aldosterone blockade. The trial data is with eplerenone
- Diabetic patients should receive an insulin infusion based on a sliding scale, according to local hospital guidelines.

Surgery

- CABG surgery is not usually undertaken acutely, but may be necessary, e.g. for failed PCI
- If CABG is likely to be required for widespread coronary disease (determined on angiography), it is possible to stent the culprit artery acutely using a bare metal stent(s), planning for CABG later in a more stable situation. The bare metal stent reduces the risk of perioperative stent thrombosis, as endothelialization is quicker.

Risk stratification and prognosis

- An important predictor of 30-day mortality in acute MI is the presence (and degree) of heart failure, quantified by Killip¹ in 1967 and updated from GUSTO trial data for the thrombolytic era (see Table 6.3).
- The extent of myocardial damage can be estimated from the magnitude of the rise in cardiac enzymes/troponin and from the appearances on echocardiography. Cardiac magnetic resonance is highly accurate in assessing the extent of myocardial scar if required.

Reference

1. Killip T, Kimball JT. Treatment of myocardial infarction in a coronary care unit: a two-year experience with 250 patients. *Am J Cardiol* 1967; **20**: 457–64.

Table 6.3 Acute MI, prognostic indicators

Group	Clinical feature	30-day mortality (%)
Killip class I	No S ₃ and clear lungs	5.1
Killip class II	S ₃ or crepitations in lungs	13.6
Killip class III	Crepitations >50% of lung	32.2
Killip class IV	Shock	57.8
Anterior MI		9.9
Inferior MI		5.0
Age <60 years		2.4
Age 60–75 years		7.9
Age >75 years		20.5

Adapted from Lee KL *et al*, Predictors of 30-day mortality in the era of reperfusion for acute myocardial infarction. Results from an international trial of 41,021 patients. GUSTO-I Investigators. *Circulation* 1996; **91**: 1659–68.

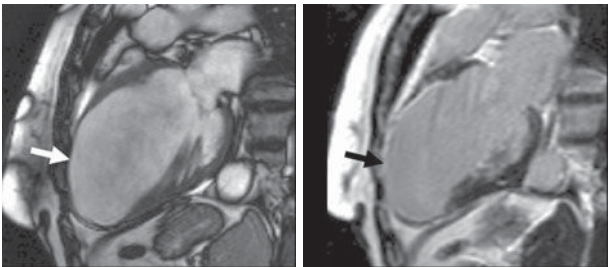


Fig. 6.6 Cardiac MRI following acute antero-apical MI. Note thinning of the LV anterior wall and apex (left, white arrow). Blood within the heart appears white on this still from a cine image. Right: delayed gadolinium enhancement imaging shows the full extent of the infarcted tissue—infarcted myocardium appears white (black arrow).

Complications of acute MI

Immediate complications (within hours)

⚠: *Ventricular arrhythmia*

VT and VF are the principal causes of death early in acute MI. Patients in the immediate peri-infarct period should be managed on a specialized coronary care unit that is equipped to treat such arrhythmias.

⚠: *Complete heart block*

Usually occurring in the context of acute inferior MI, CHB is often transient, resolving with reperfusion. When haemodynamic compromise occurs, insertion of a temporary transvenous pacing wire may be indicated (📖 Box 10.1, p.139 & p.368). Resolution of CHB may take several days, so be patient before prescribing a permanent pacemaker. CHB in the context of anterior MI suggests extensive infarction, and adverse prognosis—temporary pacing should be considered.

⚠: *Hypotension*

Hypotension in the absence of signs of heart failure may respond to a fluid challenge, e.g. 250–500 mL normal saline given rapidly. Acute inferior MI is often accompanied by rv infarction.

① *Right ventricular infarction*

Occurs in 30% of inferior MI and carries an adverse prognosis. Suggested by ST elevation >1mm in V4R. Often associated with hypotension, which may require robust fluid resuscitation to ‘push’ the RV and maintain left-sided filling pressures; central venous lines aid fluid resuscitation in this case.

⚠: *Cardiogenic shock* (📖 p.4).

Where hypotension (systolic BP <90 mmHg) is accompanied by signs of heart failure or where LV function is known to be severely impaired, IV fluid challenge is contraindicated. It may be appropriate to institute inotropic support (📖 p.9) and/or intra-aortic balloon counter pulsation (📖 p.374). Within 36 hours of acute MI, emergency PCI should be considered.

⚠: *Pulmonary congestion and pulmonary oedema*

Give oxygen, morphine, and IV loop diuretics, e.g. furosemide 40–100 mg IV. Infuse GTN 0.5–10 mg/hour IV if BP >90 mmHg systolic. Obtain a CXR. Insert a urinary catheter and monitor urine output hourly. Give oxygen and monitor HbO₂ saturation with pulse oximetry. In severe cases, CPAP or intubation and ventilation may be required (📖 p.10). Anticipate these requirements and discuss early with the ITU physicians. Speak to the patient’s relatives.

Early complications (within days)**① New murmur**

New murmur and abrupt haemodynamic deterioration suggest the possibility of papillary muscle rupture (or dysfunction) causing MR, or VSD, or free wall rupture. Obtain an echocardiogram urgently. In general, a structural problem needs a structural fix. Call the surgeons early.

⊕: Mitral regurgitation

Acute severe MR due to papillary muscle rupture is a cardiac surgical emergency. Stabilization can be attempted with IV diuretics, IV nitrates, and intra-aortic balloon counterpulsation (📖 p.374) but these are temporizing measures at best. Urgent surgical repair should be considered.

⊕: Ventricular septal rupture

Acquired VSD requires urgent surgical repair. Stabilization can be attempted with IV diuretics, IV nitrates, and IABP insertion (📖 p.374).

⊕: Rupture of myocardial free wall

Abrupt deterioration within 3 days post MI may indicate myocardial rupture. If not fatal, urgent surgical repair should be considered.

⊕ Pericarditis

Common after MI. The pain is usually pleuritic, positional, and distinct from the ischaemia-related pain of the initial presentation. Pericarditis occurs >12 hours after acute MI and is treated with high (anti-inflammatory) dose aspirin, up to 650 mg 4–6-hourly. There is some evidence that indomethacin and ibuprofen may adversely affect myocardial remodelling early post-MI, and are best avoided. Anticoagulation should be stopped if a pericardial effusion develops or enlarges.

Mural thrombus and systemic embolization

Full anticoagulation with heparin (and subsequently warfarin) should be obtained in patients with large anterior MI, known LV thrombus, or AF all of which are associated with an ↑risk of systemic embolization. Aspirin should usually be continued in addition.

Late complications (several weeks)② **Dressler syndrome**

Autoimmune-mediated acute febrile illness that occurs 2 weeks to several months after acute MI. The incidence has fallen in the reperfusion era. Management is with aspirin or NSAIDs. Large pericardial effusions may accumulate causing haemodynamic embarrassment or even tamponade—obtain an echocardiogram. Stop anticoagulants to minimize risk of haemorrhagic transformation. Percutaneous drainage (📖 p.372) may be required if tamponade occurs (rare).

① **Ventricular tachycardia**

Scar formation post-MI predisposes to VT (📖 p.178). In selected patient implantable cardioverter-defibrillator (ICD) therapy is indicated.

② **Left ventricular aneurysm**

Infarcted tissue may become thinned and dyskinetic. Aneurysms are haemodynamically inefficient, predispose to thrombus formation, and may cause persistent ST elevation on the ECG.

This page intentionally left blank

Post-infarct management

- In the absence of complications or persistent ischaemia, patients should be mobile within 24 hours
- After successful 1° PCI and an uncomplicated course, patients may be discharged at ~72 hours
- After successful thrombolysis, current guidelines recommend inpatient diagnostic angiography (within 24 hours) as the best strategy. A more conservative strategy is for a pre-discharge (day 5–7) submaximal exercise test. A low-level positive test indicates further myocardium at risk, and pre-discharge angiography is usually indicated. A negative test indicates a low-risk group and is helpful to rebuild patient confidence.

Inform the patient that they may not drive for 1 month and of their responsibility to inform the licensing authority and their motor insurance company.

Take the opportunity to implement education on 2° prevention, e.g. smoking cessation and diet (low saturated fat, low salt, promote Mediterranean-type diet). Introduction to a supervised, structured rehabilitation programme is generally beneficial.

Discharge medication

- Aspirin
- Clopidogrel
- β -blocker
- ACE inhibitor
- Statin
- Aldosterone antagonist (if ejection fraction <40%; K^+ <5 mmol/L)
- \pm omega-3 fatty acid supplements

Longer term

- For most patients, aspirin 75 mg daily will continue indefinitely.
- The optimal duration of clopidogrel treatment is uncertain. In practice, duration is determined by the nature of stent that is implanted. Patients with drug-eluting stents should receive dual antiplatelet therapy for at least 12 months. Patients with bare metal stents usually receive both for 4–6 weeks
- β -blockers are often given indefinitely in recovered STEMI patients, but evidence exists for the first year or two post-MI only
- Indefinite use of ACE inhibitors should be considered in patients with atherosclerotic disease (as 2° prevention). The benefit is greatest when there is LV dysfunction, and in these patients the dose should be titrated upwards as an outpatient.
- LDL reduction with a statin shows marked benefit in 2° prevention. Targets for treatment are for total cholesterol <4mmol/L and LDL-cholesterol <2mmol/L.
- Omega-3 fatty acids commenced within 3 months of acute MI have been associated with a mortality benefit.

Further reading

Antman EM et al. ACC/AHA Guidelines for the Management of Patients With ST-Elevation Myocardial Infarction. *Circulation* 2004; **110**: 588–636. Available at: <http://circ.ahajournals.org/cgi/reprint/110/9/e82>

Antman EM et al. 2007 Focused Update of the ACC/AHA 2004 Guidelines for the Management of Patients With ST-Elevation Myocardial Infarction. *Circulation* 2008; **117**: 296–329. Available at: <http://circ.ahajournals.org/cgi/content/full/117/2/296>.

Van de Werf J et al. Management of acute myocardial infarction in patients presenting with persistent ST-segment elevation. The Task Force on the management of ST segment-elevation acute myocardial infarction of the European Society of Cardiology. *Eur Heart J* 2008; **29**: 2909–45.

ⓘ **Unstable angina and NSTEMI**

In the absence of sustained ST segment elevation, ischaemic pain of abruptly worsening severity or occurring at rest is classed as 'unstable angina' or non-ST segment elevation MI (NSTEMI). The distinction depends on the eventual presence (NSTEMI) or absence (UA) of an elevated troponin measurement. The underlying pathology (ruptured or eroded coronary plaque with non-occlusive or intermittently occlusive thrombus) and initial management is the same. The immediate objectives are to relieve pain and to prevent progression to acute MI.

Symptoms

- Similar to STEMI
- Central chest pain/ache of variable severity and duration—may radiate to the jaw or (left) arm and typically not relieved by GTN
- There may be a history of prior chronic stable angina. Pain is sometimes accompanied by 'autonomic' features diaphoresis (sweating), nausea, and vomiting

Signs

- There may be no abnormal physical signs
- Pain or distress
- Clammy—a result of sweating and cutaneous vasoconstriction
- Occasionally accompanied by intermittent pulmonary oedema, depending on degree of ischaemia and underlying LV function.

Investigations

- ▶ At presentation, the diagnosis is clinical.

ECG

- The ECG may be normal
- ECG changes include ST segment depression and T-wave inversion, which may be 'dynamic'—coming and going with symptoms (Fig. 6.7)
- Exclude sustained ST-segment elevation (📖 p.44)
- If the ECG is normal but pain persists, obtain serial ECGs.

Bloods

- Check FBC—to exclude anaemia
- Troponin at presentation and 12 hours after onset of pain.

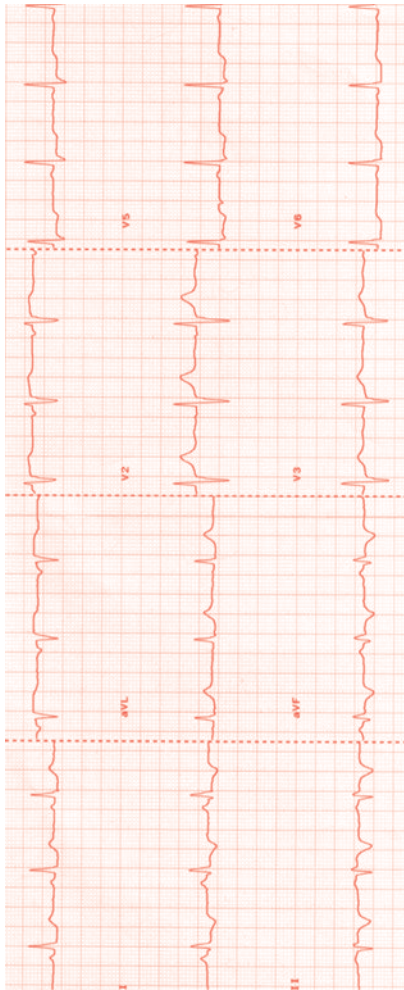


Fig. 6.7 ECG during chest pain. ST segment depression in leads I, V5, and V6 with T-wave inversion in leads II, III, and aVF is suggestive of ischaemia in the inferolateral territory.

Immediate management

There are 4 principal categories of therapy:

- Agents to reduce ischaemia
- Antiplatelet agents
- Anticoagulants
- PCI.

A general scheme is given here, but the precise management is determined in part by decisions on 'early conservative' management vs. an 'early invasive' strategy (i.e. angiography \pm PCI)

- Aspirin 150–300 mg. Chewed to achieve rapid buccal absorption
- Clopidogrel 300–600 mg PO loading, then 75 mg daily
- Anticoagulation: LMWH (enoxaparin 1 mg/kg twice daily SC) **or** factor Xa inhibition (with fondaparinux 2.5 mg daily SC—for early conservative group)
- SL or IV GTN
- Morphine 5–10 mg or diamorphine 2.5–5 mg IV analgesia as required
- Metoclopramide 10 mg IV as required (give with opiates if prescribed)
- β -blocker, e.g. atenolol 50mg OD PO or metoprolol 25–50mg PO TDS
- Oral diltiazem is an alternative when β -blockers are contraindicated (and there is no evidence of cardiac failure, AV block, or hypotension)
- \pm revascularization in selected patients according to risk (see Box 6.4)

Early invasive treatment

- With a view to revascularization (by PCI or coronary artery bypass as influenced by coronary anatomy)
- Clinical indications for an early invasive strategy include ongoing symptomatic ischaemia, especially dynamic ST segment depression on the ECG (i.e. changes with the pain), haemodynamic compromise, (recurrent) major arrhythmias and recent (e.g. within 6 months) PCI
- Elevated troponin also suggests a high-risk category
- The TIMI score is a well-validated, simple risk calculator (see Box 6.4). As a guide, patients with TIMI score >3 are at high risk and early invasive management may be beneficial.

Anticoagulation

- Anticoagulants are given to reduce thrombin-mediated thrombus formation and are administered in addition to antiplatelet agents
- Both unfractionated and LMWHs have been used in ACS. For patients undergoing an early invasive strategy, UFH or enoxaparin should be given immediately. For patients undergoing early conservative management, LMWH (enoxaparin) or fondaparinux may be given.

Thienopyridines

Clopidogrel has been evaluated in clinical trials using a 300 mg loading dose with 75 mg daily thereafter. In patients undergoing early invasive management, it is reasonable to give clopidogrel 600 mg loading, since this results in more rapid platelet inhibition, though the strategy has not been evaluated in a large clinical outcome setting.

Glycoprotein IIb/IIIa inhibition

Glycoprotein IIb/IIIa inhibitors are potent antiplatelet agents that block the common path of platelet aggregation. Patients with 'high risk features' (see Box 6.4) or evidence of ongoing or recurrent ischaemia may benefit from eptifibatid or tirofiban (but not abciximab) even where early PCI is not planned. Decisions on the use of GPIIb/IIIa inhibition should factor in bleeding risk.

Discharge medication and longer-term management

Similar to STEMI (p.60), typically:

- Aspirin
- Clopidogrel
- β -blocker
- ACE inhibitor
- Statin

Box 6.4 TIMI risk score for unstable angina/NSTEMI (1 point for each)

- Age ≥ 65 years
- ≥ 3 coronary risk factors
- Use of aspirin within 7 days
- Elevated cardiac markers
- ST segment deviation
- Prior angiographic evidence of coronary disease
- >2 angina events within 24 hours.

The score is determined by simply summing the number of risk factors as listed. For patients with TIMI score 0–1, the combined risk of death, (re)infarction, or recurrent severe ischaemia requiring revascularization is 75% while TIMI score 6–7 confers a risk of 41%. A score >3 is often used to indicate high risk worthy of an early invasive strategy.

Further reading

Bassand J-P et al. Guidelines for the diagnosis and treatment of non-ST segment elevation acute coronary syndromes. The Task Force for the Diagnosis and Treatment of Non-ST-Segment Elevation Acute Coronary Syndromes of the European Society of Cardiology. *Eur Heart J* 2007; **28**: 1598–660. Available at: <http://eurheartj.oxfordjournals.org/cgi/reprint/ehm161v1>.

Recent percutaneous coronary intervention

- ▶ Be aware of the possibility of stent-related thrombosis, particularly early after implantation, where drug compliance is questionable or where antiplatelet agents have recently been stopped.
- ▶ Immediate angiography is indicated where subacute stent thrombosis is suspected. The mortality of untreated stent thrombosis is high.

Insertion of a metallic stent during PCI poses a risk of acute and subacute stent thrombosis. To counter this, aspirin and clopidogrel are given prior to PCI and heparin (\pm abciximab) is given in the cardiac catheterization laboratory. The risk of stent thrombosis declines rapidly during first 24 hours after PCI but there remains a longer-term risk of thrombosis until the endothelium grows over the stent.

For bare metal stents, it is usual to continue a combination of aspirin 75mg OD and clopidogrel 75mg OD for at least 1 month after PCI to cover the small risk of subacute stent occlusion. Where drug-eluting stents are used, there is a possibility of delayed stent endothelialization and aspirin/clopidogrel combination is usually maintained for 12 months.

Acute heart failure

- Clinical features 68
- Causes of decompensation 70
- Investigations 70
- Differential diagnosis 70
- Management 72
- Monitoring and goals 76
- Adverse signs 78
- Special circumstances in heart failure 80
- Cardiogenic shock 82
- Myocarditis 84
- Cardiomyopathies 86
- Difficult case examples 90

Clinical features

Acute heart failure can be either acute or acute-on-chronic (more common). In all cases, efforts should be made to identify the underlying cause (Box 7.1) and, in particular, why it should present now. Heart failure is not a homogeneous condition and whilst some general principles apply, successful treatment depends upon the accurate assessment of the aetiology and haemodynamic profile in each patient (see Table 7.1).

Clinical features are of fluid overload and low cardiac output:

Fluid overload/congestion

- Orthopnoea
- Raised JVP*
- Gallop rhythm
- Pulmonary inspiratory crackles
- Peripheral oedema*
- Ascites*
- Hepatic distension.

Low output

- Tachycardia
- Low BP/narrow pulse pressure*
- Cool extremities
- Poor capillary refill
- Confusion/drowsiness
- Oliguria
- Pulsus alternans (terminal).

*May be absent in acute heart failure

▶▶ If the patient is shocked (systolic BP <90 mmHg with signs of reduced major organ perfusion), they need urgent attention (☞ p.4).

Systolic vs. diastolic heart failure

Systolic heart failure involves reduced systolic function on echocardiography or other imaging modality. Diastolic heart failure involves impaired LV filling in the absence of major systolic dysfunction. This is mainly due to increased stiffness of the ventricle, commonly from longstanding hypertension, and is particularly common in the elderly. These patients respond to vasodilators, adequate fluid balance, and rate slowing (if tachycardic); they respond poorly to dehydration.

Box 7.1 Causes of heart failure

- Ischaemic heart disease—usually chronic; may be acute (STEMI)
- Valvular heart disease—either chronic, or acute* e.g. following MI
- Arrhythmias*
- Hypertension—either longstanding, or crisis*
- Pericardial tamponade*
- Myocarditis*
- Cardiomyopathy with acute decompensation—dilated, hypertrophic, post partum
- Aortic dissection*—coronary ischaemia, aortic regurgitation
- Renal failure*—volume overload
- Alcohol abuse
- High output—anaemia, hyperthyroidism, arteriovenous fistulae.

*May be acute (others generally acute-on-chronic).

Table 7.1 New York Heart Association (NYHA) classification of heart failure

Score	RiskTreatment
Class I	Asymptomatic (though with reduced LV function). No limitation of physical activity.
Class II	Mildly symptomatic, with slight limitation of physical activity. Comfortable at rest but ordinary physical activity results in fatigue or dyspnoea.
Class III	Moderately symptomatic, with marked limitation of physical activity. Comfortable at rest but less than ordinary activity results in fatigue or dyspnoea.
Class IV	Severely symptomatic. Unable to carry out any physical activity without discomfort. Includes dyspnoea/fatigue at rest, with any activity resulting in increased discomfort.

Causes of decompensation

Many cases of acute heart failure are in fact decompensation of chronic heart failure, and 2/3 are a readmission within 3 months. Seeking the reasons for decompensation is therefore important. Failure to comply with therapy (either drugs or fluid intake) is a common cause.

- Lack of compliance
- Uncontrolled hypertension
- Arrhythmias
- Inadequate therapy
- Pulmonary infection
- Administration of inappropriate medications, e.g. NSAIDs, anti-arrhythmic agents, non-dihydropyridine calcium antagonists
- Fluid overload—often iatrogenic if in hospital
- MI
- Endocrine disorders (thyrotoxicosis).

Investigations

- FBC—anaemia, infection
- U&E, thyroid function
- Troponin—acute coronary syndrome
- ECG—ischæmia, MI, arrhythmia, hypertension
- CXR—pulmonary oedema, tamponade, sepsis, dissection
- Brain natriuretic peptide (BNP)—see Box 7.2
- Echocardiography
- Arterial blood gas analysis if severe heart failure.

Differential diagnosis

Any cause of SOB (📖 p.21) may be included here, but the commonest ones, particularly without CXR evidence of pulmonary oedema, are:

- COPD
- Pulmonary embolus (major PE can however cause pulmonary oedema).

Echocardiography is the most useful diagnostic tool for discrimination and may be supplemented by BNP measurement (Box 7.2).

For patients presenting with radiological evidence of pulmonary oedema, non-cardiogenic causes have to be considered (Box 7.3). Clinical features suggestive of a non-cardiogenic cause are normal/low venous pressure, normal/increased cardiac output, normal ECG, normal LV function on echocardiography, failure to respond to standard heart failure therapy.

Box 7.2 Brain natriuretic peptide (BNP)

Serum levels can be helpful in confirming the diagnosis of acute heart failure. BNP is more accurate than any other single finding on history, examination, or laboratory testing. A negative test result makes the diagnosis of heart failure unlikely. Threshold values of >300 pg/mL for NT-proBNP and 100 pg/mL for BNP have been suggested. The availability of diagnostic testing may however be limited.

► The following may give rise to an elevated BNP in the absence of clinical heart failure:

- Renal failure
- ACS
- Aortic stenosis
- Mitral regurgitation
- Hypertrophic cardiomyopathy.

Box 7.3 Causes of non-cardiogenic pulmonary oedema

- Imbalance of Starling's forces:
 - ↑ pulmonary capillary pressure
 - ↓ plasma oncotic pressure (hypoalbuminaemia)
 - ↓ interstitial pressure (decompression of pneumothorax, severe asthma)
- Acute respiratory distress syndrome (↑alveolar-capillary permeability):
 - Infection
 - Toxins
 - Aspiration of gastric contents
 - Disseminated intravascular coagulation (DIC)
 - Acute pancreatitis
- Drugs
- 'Shock-lung'
- Other:
 - Lymphatic insufficiency
 - High altitude
 - PE
 - Neurogenic
 - Eclampsia
 - Post-CABG/cardioversion
 - Post-anaesthesia.

Management

See management algorithm in Fig. 7.1.

Immediate

Treatment aims are to reduce preload and afterload with a combination of diuretics and vasodilators. It is important in the early stages of treatment to establish adequate oxygenation—this has a major impact on myocardial performance and the response to diuretic therapy.

- Sit patient up
- Oxygen therapy: aim for SpO₂ >95% (or >90% with COPD)
- IV morphine 2.5–10 mg IV (good venodilator and relieves acute stress)
- Loop diuretics (e.g. furosemide 40–120 mg IV)
- IV nitrate infusion (e.g. GTN 1–10 mg/hour) may be useful if significant failure and BP allows (i.e. >95 mmHg systolic)
- Withdraw any drugs which may be contributing to heart failure (e.g. calcium-channel blockers and NSAIDs).

Continuing

Drug therapy can be tailored to the haemodynamic profile (see Box 7.4).

Diuretics

Loop

- Standard therapy in acute pulmonary oedema and in patients demonstrating signs of fluid overload
- Infusions are more effective than bolus regimens (time above the natriuretic threshold is more important than maximum concentration in the nephron)
- Start with furosemide 40 mg IV (or bumetanide 1 mg IV) bolus if not already on diuretics. If previously treated, start with usual oral dose given intravenously and titrate according to response
- A good response usually occurs within 30 min, though loop diuretics last several hours
- In severe heart failure, diuretic resistance or renal impairment, consider furosemide bolus followed by infusion over 4–8 hours. Maximum bolus dose 50 mg, maximum infusion rate 4 mg/min.

Non-loop

- Thiazides and aldosterone antagonists are useful as an adjunct to loop diuretics in diuretic resistance.
 - Bendroflumethiazide 2.5 mg daily (ineffective when the creatinine clearance is <30 mL/min)
 - Metolazone (2.5–10 mg daily) has an effect regardless of creatinine clearance and produces a more rapid diuresis. Care is required however due to its potent effect
- Aldosterone antagonists:
 - Spironolactone (25–50 mg daily), eplerenone (25–50 mg daily). Avoid if creatinine >220 μmol/L or K⁺ >5 mmol/L.

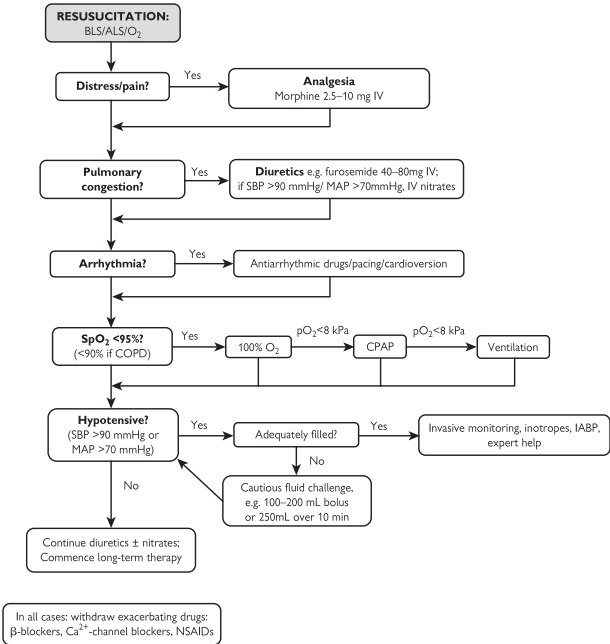


Fig. 7.1 Management algorithm for patients presenting with acute heart failure, incorporating the ESC guidelines on management of acute heart failure.

ACE inhibitors

- Beneficial in the long term, including a reduction in mortality
- Not always introduced in the acute phase of heart failure, although there is good evidence for their early introduction following MI
- They should be withheld temporarily in the following circumstances:
 - Systolic BP <90 mmHg, especially in the presence of renal impairment or diuretic resistance
 - Creatinine >300 $\mu\text{mol/L}$, or progressive rise in creatinine >25–30%.


 β -blockers

- Contraindicated in acute heart failure
- Patients already on β -blockers should normally have them withheld temporarily. Only in those with mild heart failure with predominant fluid overload can they be continued
- β -blockers can be introduced when fluid status and haemodynamics are optimal—usually in the outpatient setting
- If stopped temporarily, ensure they re-started gently after stabilization.

Digoxin

- Often beneficial in acute heart failure with fast AF
- For those in sinus rhythm, opinion is divided as to the usefulness in acute settings. It is most effective in patients with a S_3 , elevated JVP, and severe LV dilatation.

Vasodilators

- Morphine (2.5–10 mg IV stat):
 - Predominant venodilator
 - Important in relieving acute distress.
- Nitrates:
 - IV if acutely unwell (e.g. GTN infusion 1–10 mg/hour)
 - Oral nitrates may be added, though evidence for usefulness is poor
 - Venodilators at low doses; arterial vasodilators in high dose
 - Tolerance occurs after 24 hours
 - Aim for a 10 mmHg fall in systolic BP
 - Discontinue if BP falls below 90 mmHg
- Sodium nitroprusside (0.5–8 mcg/kg/min IV infusion) (see  Box 11.3, p.196):
 - For severe cases
 - Requires continuous arterial pressure monitoring
 - Prolonged use is associated with toxicity and should be avoided in patients with severe renal or hepatic failure
 - Most useful in hypertensive heart failure and acute mitral regurgitation.

Box 7.4 Haemodynamic profiles in heart failure

Warm/cold = good/poor peripheral perfusion.

Wet/dry = congested/not congested.

Warm and wet (common)

- Emphasis on diuretic therapy with addition of vasodilators
- Significant diuresis may be required
- β -blockers can be continued
- Inotropes inappropriate.

Cold and wet

- Emphasis on vasodilator therapy with additional diuretics
- β -blockers and ACE inhibitors may need temporary withdrawal
- Vasodilating inotropes (e.g. dobutamine) may be helpful if poor response.

Cold and dry

- ▶ Distinguish from hypovolaemic shock.
- Emphasis on inotropic support \pm IABP
- Haemodynamic monitoring required
- Cautious filling if CXR clear.

Warm and dry

- This is the target profile
- Emphasis on titration of chronic therapy to optimal doses

Adapted from Nohria A *et al.* Medical management of advanced heart failure. *JAMA* 2002; **287**: 628–40.


Monitoring and goals

Monitoring

Pulse, BP, ECG monitoring, pulse oximetry

- Automatically in first 24 hours
- Prolonged in the presence of arrhythmias, during inotrope therapy, or in the case of persistent haemodynamic instability.

Arterial blood gases

- On admission in all cases with severe heart failure; if abnormal, repeat at appropriate intervals to monitor response to therapy and guide need for assisted ventilation
- Regularly in patients on CPAP (see  p.10)
- Consider an arterial line if haemodynamically unstable or for frequent arterial blood gases.

Electrolytes, creatinine, and renal function

- Daily in patients who are haemodynamically unstable, and patients on IV or combination diuretics.

Fluid balance/urinary catheterization

- Good fluid balance is important for all cases
- Urinary catheterization recommended in severe heart failure. Can be a surrogate for cardiac output in the absence of significant renal disease.

CVP (p.12)

- Not usually required
- Not recommended in acute pulmonary oedema (lying patient flat may precipitate cardiac arrest)
- May be required if inotropic support required.

Pulmonary artery catheter (p.366)

- Rarely required
- Can be useful for exclusion of non-cardiogenic pulmonary oedema
- May be misleading in MS, AR, high airway pressures, and poor LV compliance.

Goals of therapy

Without haemodynamic monitoring

- Symptomatic improvement
- Oxygenation $\text{SaO}_2 > 95\%$
- Warm peripheries
- Systolic BP > 90 mmHg
- JVP (isolated right heart failure excluded) < 5 cm
- Clinical and radiological resolution of pulmonary oedema
- Urine output > 0.5 mL/kg/hour.

With haemodynamic monitoring (previous list included)

- Pulmonary wedge pressure 16–18 mmHg
- Cardiac output > 2.5 L/min/m²
- Systemic vascular resistance 950–1300 dyne.sec/cm².

This page intentionally left blank

Adverse signs

Suggest deterioration/failure to respond to therapy.

① Hypotension (systolic BP <90mmHg)

- Stop any exacerbating drugs (e.g. nitrates). Use opiates and diuretics with caution
- May require a fluid challenge if BP doesn't recover
- If no response to fluids, or adequately filled already, and evidence of organ hypoperfusion (e.g. oliguria, prolonged capillary refill time, impaired consciousness), consider vasopressor inotropes (📖 p.9).

① Oliguria/anuria

- Sometimes called cardiorenal syndrome
- Ensure adequate renal perfusion—correct hypotension with fluid challenge if evidence of underfilling, or consider vasodilating inotropes if systolic BP >90mmHg
- May need further diuretic boluses or an infusion, especially in cases of severe heart failure, previous regular diuretic use or renal impairment
- Monitor urine output (aim >20mL/hour)
- Some cases may be suitable for haemofiltration if oliguria remains despite adequate renal perfusion.

① Persistent pulmonary oedema (see also p.80)

- Ensure adequate oxygenation ($SpO_2 > 95\%$)
- Consider further diuretics: furosemide continuous infusion (maximum infusion rate 4mg/min) may be required
- If adequate BP, try IV nitrate infusion
- Exclude concurrent infection, pulmonary disease, non-cardiogenic pulmonary oedema
- May respond well to CPAP if fitted appropriately and patient is given appropriate support.

① Confusion/drowsiness

- Often due to hypotension and inadequate cerebral perfusion, ∴ treatment of the hypotension is required
- Rule out hypoxia and hypercapnia: check SpO_2 and/or arterial blood gases and treat findings accordingly.

This page intentionally left blank

Special circumstances in heart failure

① Intractable pulmonary oedema and hypoxia

$pO_2 < 8$ kPa, $pCO_2 > 6.5$ kPa, worsening acidosis.

Non-invasive ventilation (📖 p.10)

Two forms of non-invasive ventilation can be used: CPAP and BiPAP, which has additional inspiratory assistance. These may be particularly helpful in patients with reversible ischaemia. BiPAP may, however, increase cardiac work, and should be used with caution and after specialist advice.

Invasive ventilation

Should be considered in the following circumstances:

- Failure to correct hypoxia ($SaO_2 < 90\%$)
- Fatigue associated with acidosis ($pH < 7.2$)
- Failure to tolerate CPAP mask.

Haemofiltration

May occasionally be required in the presence of acute renal failure and volume overload, where the aetiology of the acute heart failure is felt to be reversible.

⚠️ Acute MI (📖 p.44)

Revascularization using thrombolysis or primary/rescue angioplasty with balloon pump support if available, in addition to treating heart failure.

⚠️ Acute VSD/mitral valve rupture

- These predominantly mechanical disorders giving rise to pulmonary oedema often respond poorly to conventional therapy
- Urgent surgery, with balloon pump support as a holding measure, is recommended (see 📖 p.57).

Diabetes

Insulin infusion is recommended in diabetics with acute heart failure.

Thyrotoxicosis

Cautious use of non-selective β -blockade is recommended (propranolol 0.5 mg IV, or 10 mg orally).


① Hypertensive crisis (📖 p.348)

LV function is often normal.

⚠️ Severe bronchoconstriction ('cardiac asthma')

- A profound bronchoconstrictor response to pulmonary oedema
- If conventional therapy fails there may be a response to IV aminophylline (250 mg IV bolus over 20 min). Caution however—this is associated with an incidence of cardiac arrhythmias.

ⓘ Right heart failure (Box 7.5)

- Particularly seen in the context of RV infarction (usually accompanying inferior MI,  p.56) and PE
- The diagnosis is suggested by clear lung fields in the context of a raised venous pressure and systemic hypotension
- Early echocardiography is recommended
- Requires fluid supplementation (200 mL saline fluid challenges) to drive RV contraction
- Use inotropes for resistant hypotension and hypoperfusion
- May be worsened by mechanical ventilation, so avoid this if possible.

Box 7.5 Causes of right heart failure

- RV infarction
- Pulmonary embolic disease
- Cardiac tamponade
- Chronic pulmonary disease/hypoxia
- Pulmonary hypertension
- Valvular disease—pulmonary/tricuspid valves
- Congenital heart disease, e.g. Ebstein's anomaly, Eisenmenger syndrome
- Arrhythmogenic RV cardiomyopathy.

Recurrent admissions with 'flash' pulmonary oedema

These patients may have a relatively normal exercise tolerance between attacks. The following should be considered:

- Renal artery stenosis
- Reversible ischaemia
- Intermittent tachyarrhythmias.

ⓘ Severe aortic stenosis (p.102)

- Patients with severe AS and heart failure are difficult to treat, so **expert help is required!**
- Diuretics are the mainstay of therapy as a holding measure
- Vasodilators and inotropes are contraindicated
- The only truly effective treatment is urgent aortic valve replacement—although high risk, the prognosis is dismal without.

⊕ Cardiogenic shock

In cardiogenic shock with acute heart failure, prognosis is particularly poor and recovery is unlikely unless there is a reversible cause.

Cardiogenic shock is defined by:


- MAP <60 mmHg or systolic BP <90 mmHg
- In the presence of:
 - Satisfactory heart rate (60–95 bpm).
 - Adequate filling pressures
 - On 100% O₂
- With 1 of the following:
 - Obtunded cerebral function
 - Poor peripheral perfusion
 - Low urine output
 - Central venous O₂ saturation <70%
 - Lactic acidosis >2.0 mmol/L
- Need intensive, and usually invasive, monitoring.

Treatment (see Cardiovascular collapse p.4)

► Aggressive and invasive treatment is only appropriate in patients where there is a potentially reversible cause or as a bridge to revascularization or transplantation (see Box 7.6).

Use opiates cautiously as they may drop BP further/exacerbate cerebral obtundation.

Principally consists of:

- Inotropic support—if evidence of organ hypoperfusion, consider cautious use of vasopressor, e.g. epinephrine/norepinephrine
- IABP as a bridge to revascularization/surgery/transplantation (Box 7.7)
- Consider a fluid challenge, e.g. 100 mL boluses of saline, with CVP monitoring ( p.12) if underfilled
- Stop/avoid agents causing hypotension (e.g. ACE inhibitors)
- Mechanical LV assist devices are available in a few centres, primarily as a bridge to transplantation, or recovery in some patients (e.g. acute myocarditis, peripartum cardiomyopathy)
- Intubation and mechanical ventilation may be necessary, especially when patients are undergoing invasive treatments, as lying flat may precipitate cardiac arrest.

Box 7.6 Appropriateness of intensive therapy

Intensive therapy may be appropriate in cases where the aetiology of acute heart failure is felt to be reversible, e.g.:

- Acute myocarditis is the likely cause, e.g. infective myocarditis or peripartum cardiomyopathy
- Patients with no/few comorbidities and good pre-morbid quality of life
- Acute heart failure 2° to ischaemia/infarction or its complications, as a bridge to revascularization or surgery
- Valvular disease in whom surgery is planned.

Box 7.7 IABPs—guidance for use in cardiogenic shock

Adapted from the AHA/ACC guidelines for IABP following acute MI, but applicable to most situations of cardiogenic shock. ESC guidelines are similar.

► IABPs require expert help for insertion and use. They are not for the inexperienced!

An IABP may be appropriate in the following circumstances:

- In cardiogenic shock which doesn't rapidly reverse with pharmacological measures, pending revascularization
- With acute mitral regurgitation or VSD, as a stabilizing measure prior to repair
- Recurrent ventricular arrhythmias with haemodynamic instability
- Refractory post-MI angina as a bridge to revascularization
- In the presence of haemodynamic instability, poor LV function, or persistent ischaemia in patients with a large area of myocardium at risk (i.e. severe global ischaemia).

! Myocarditis

Causes

- Viral—characteristically enterovirus infections, e.g. coxsackie
- Other infective—bacterial, fungal, rickettsial, and spirochaetal
- Cocaine
- Peripartum cardiomyopathy
- Giant cell myocarditis.
- Idiopathic

Presentation

A wide spectrum from the acute fulminant form, in which the outcome ranges from complete recovery to death, to a chronic form indistinguishable on presentation from dilated cardiomyopathy.

Clinical features

- Fatigue, breathlessness, and chest discomfort
- \pm fever with a disproportionate tachycardia
- \pm heart failure if severe cardiac dysfunction (less common)
- Atrial and ventricular arrhythmias are common.

Investigations

- CXR—heart size may be normal or enlarged
- ECG—ST and T-wave abnormalities, may present with regional ST elevation and can be mistaken for acute MI. AV block and conduction defects
- Echocardiography—global or regional wall motion abnormalities (generally not in a coronary artery distribution)
- Viral serology—often sent but rarely useful in guiding therapy
- Troponin—elevated in acute cases
- Myocardial biopsy—again rarely helpful in guiding therapy but may sometimes be performed at the time of coronary angiography.

Treatment

- Bed rest, ACE inhibitors, diuretics, and inotropes as required
- Arrhythmias treated as for patients with known LV dysfunction. However, patients display an \uparrow sensitivity to digoxin
- Anticoagulation for severe LV dysfunction or LV thrombus
- Cardiac transplantation in selected extreme cases.

Prognosis

- 80% 1-year survival; 50–60% 5-year survival
- 1/3 of those recovering have residual LV dysfunction
- The more fulminant, very acute form has a better long-term prognosis than the chronic, slower presentation.

This page intentionally left blank

Cardiomyopathies

Hypertrophic cardiomyopathy

The identification of patients presenting with hypertrophic cardiomyopathy is important, as vasodilators and inotropes are usually inappropriate, and contraindicated in those with outflow obstruction.

The most likely emergency presentations are with syncope, arrhythmias, or chest pain. Presentation with LV failure is uncommon and is usually secondary to fast AF. Cases are often discovered incidentally when echocardiography is performed.

Symptoms

- Syncope
- Chest pain
- Palpitations
- Breathlessness.

Examination

- Can be normal
- Prominent 'a' wave in JVP
- Bifid pulse and/or apex
- Mid systolic murmur in aortic region
- S₄
- Pan systolic murmur at apex (if mitral regurgitation).

Investigations

- ECG: prominent Q waves in inferior/anterior leads, LA enlargement, giant T-wave inversion (esp. apical variant), ± pre-excitation (Fig. 7.2)
- Echocardiography: LV hypertrophy (>13 mm), characteristically asymmetrical, systolic anterior movement of mitral valve, mitral regurgitation, LV outflow tract gradient, diastolic dysfunction.

Treatment

- The presence of hypertrophic cardiomyopathy itself rarely requires acute treatment
- Adequate filling pressures should be maintained, especially in postoperative patients. The LV is stiff ± an outflow tract gradient and adequate fluid balance is important
- Treat heart failure and arrhythmias if present
- Early cardioversion for AF is advised in patients who are hypotensive and in pulmonary oedema
- Avoid digoxin generally, and use verapamil cautiously in patients with an outflow tract gradient
- Angina can be treated with β -blockade
- In the presence of an outflow tract gradient, inotropes and nitrates are contraindicated, even in the presence of hypotension
- Longer-term management involves a risk assessment for sudden death, genetic counselling, and family screening.

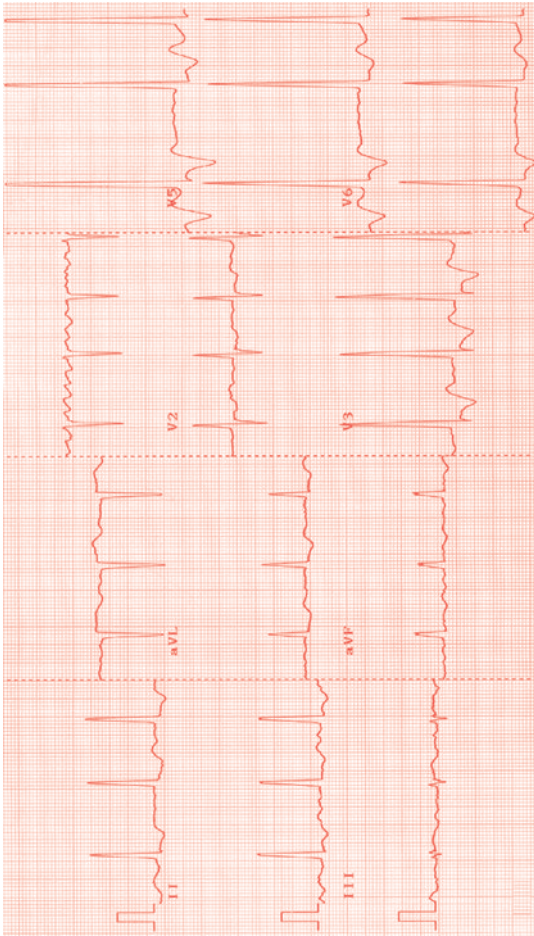


Fig. 7.2 ECG in hypertrophic cardiomyopathy. The underlying rhythm is AF. Tall R waves are seen along with repolarization changes in V3–V6, in keeping with significant LV hypertrophy.

Dilated cardiomyopathy

- Globally dilated LV with poor function
- Often discovered incidentally
- Acute presentation is uncommon but when occurs, it is likely to be acute-on-chronic heart failure
- Treat as for other causes of heart failure, but especially important to investigate the reasons for decompensation (e.g. arrhythmia)
- Causes include:
 - Idiopathic (\pm familial)
 - Coronary artery disease
 - Alcoholic cardiomyopathy
 - Hypertension—end-stage
 - AS
 - Myocarditis
 - Chronic tachyarrhythmia
 - Peripartum cardiomyopathy
 - Autoimmune disease
 - HIV cardiomyopathy
 - Arrhythmogenic RV cardiomyopathy—predominantly RV dilation, but can be LV too
 - Haemochromatosis.

Restrictive cardiomyopathy

- Usually hypertrophied LV with poor function (diastolic $>$ systolic)
- Again, acute presentation is rare but look for precipitating cause for heart failure
- As for hypertensive heart disease, patients require adequate filling, vasodilators, and minimal diuretics
- Causes include:
 - Idiopathic
 - Myocardial fibrosis—from any cause
 - Amyloidosis
 - Sarcoidosis
 - Scleroderma
 - Iron storage diseases—haemochromatosis, thalassaemia
 - Diabetic cardiomyopathy
 - Eosinophilic heart disease
 - Glycogen storage diseases
 - Other rare genetic diseases, e.g. Fabry and Hurler syndromes.

This page intentionally left blank

Difficult case examples

► NB these are only examples to illustrate certain difficult combinations. These are not exhaustive, and individual cases will vary significantly.

1. AF and heart failure

Severe pulmonary oedema with AF at a rate of 170 bpm. Has not responded to 3 doses of furosemide 40 mg IV and a loading dose of digoxin. Oxygen saturations are 90% on 100% O₂. Is it safe to cardiovert?

A: Cardioversion under full anaesthetic is probably the best option here especially if the patient is hypotensive. Cardioversion with sedation alone is not appropriate (due to the significant respiratory compromise already). A period of ventilation afterwards may be needed but this in itself can be a good treatment for heart failure.

2. Sepsis and heart failure

Acute dyspnoea and sepsis, pulse 110 bpm, systolic BP 80 mmHg, venous pressure not visible. There is a history of LV failure and the patient does not want to lie flat. What is the appropriate management?

A: Patients with a combination of sepsis and heart failure present difficult management problems. A clear CXR is reassuring and it is then reasonable to institute fluids, but often there is only a portable X-ray which is difficult to interpret. A central line is helpful (target CVP 8–10 mmHg). However, it is not advisable to force a patient flat to put in a central line when they are acutely dyspnoeic: they can arrest. Cautious boluses of 100 mL normal saline can be used but **stay with the patient to monitor the response**. Stop if patient deteriorates or desaturates. Vasoconstricting inotropes may be needed.

3. Patient on β -blocker therapy

Presents with breathlessness and evidence of LV failure with basal crepitations and an elevated JVP. The patient is taking carvedilol 25mg BD and an ACE inhibitor. Should the β -blocker be stopped and if so when can it be restarted?

A: If the patient is haemodynamically stable and not in acute respiratory distress, it is reasonable to continue β -blocker therapy and increase the diuretic dose. With haemodynamic compromise, β -blocker therapy should be discontinued and restarted when the pulmonary oedema has cleared and systolic blood is ≥ 100 mmHg. ACE inhibitor should be stopped if there is severe hypotension (systolic BP < 80 mmHg), or moderate hypotension with evidence of deteriorating renal function (oliguria or rising creatinine).

4. Poor peripheral perfusion and pulmonary oedema

Presented with pulmonary oedema. The patient is cold peripherally, the pulse is 100 bpm (small volume) and systolic BP 110 mmHg. They have not passed urine for 2 hours despite 100 mg IV frusemide. What are the therapeutic options?

A: Patients with evidence of poor tissue perfusion but a reasonable systolic pressure may respond to vasodilating inotropes (e.g. dobutamine or low-dose dopamine). Vasodilating inotropes are often started inappropriately late when the systolic BP is low—in this situation they are often ineffective and lower the BP further.

5. Cardiogenic shock post-MI

Deteriorated 8 hours following thrombolysis for a large anterior MI. Pulmonary oedema and hypotension (systolic BP 80 mmHg) are present. There has been no urine output for 3 hours. What is the appropriate management?

A: This situation carries a very high mortality regardless of any intervention. Vasoconstricting inotropes or insertion of an IABP may be required whilst awaiting transfer to the catheter laboratory for angioplasty. Advanced support may not be indicated if no definitive procedure to restore myocardial function is planned, or prognosis is further reduced by significant comorbidities.

This page intentionally left blank

Valve disease

Acute valve problems 94
Emergency non-cardiac surgery 100
Chronic valve disease 100

Specific valve lesions

Aortic stenosis 102
Aortic regurgitation 104
Mixed aortic valve disease 104
Mitral stenosis 106
Mitral regurgitation 108
Pulmonary stenosis 110
Pulmonary regurgitation 110
Tricuspid stenosis 112
Tricuspid regurgitation 112
Prosthetic valves 114
Acute rheumatic fever 118

Acute valve problems

► Acute valve problems require urgent treatment, as decompensated heart failure can occur rapidly.

Mode of presentation

It can be difficult to differentiate the nature of the current problem, as patients' presentations may be similar, but the following may help:

⊖: *Acute*

Rapid/sudden deterioration of valve function on previously normal valve. The patient is usually extremely unwell as the LV has not had time to compensate. Nearly always regurgitation rather than stenosis.

Causes:

- Infective endocarditis—leaflet disintegration, perforation, or dehiscence (?abscess); vegetation (→ incompetence or stenosis); dehiscence of prosthetic valve ring; papillary muscle rupture
- MI—usually MR 2° to papillary muscle dysfunction (causes: papillary muscle infarction, rupture, or tethering to infarcted myocardial wall)
- Aortic dissection—type A can dissect into aortic root causing aortic valve dehiscence
- Ruptured chordae tendinae, causing MR or, rarely, TR
- Trauma.

① *Acute-on-chronic*

Recent worsening of pre-existing valve lesion. Causes as for acute, plus:


- Recent deterioration of valve function, i.e. natural history
- Severe changes in haemodynamics, e.g. rise or fall in BP, changes in fluid balance.

① *Cardiac decompensation*


Pre-existing valve dysfunction with new ventricular decompensation.

Causes:


- Natural history, 2° to chronic valve dysfunction
- Changes in haemodynamics—BP changes or fluid shifts
- Arrhythmias—particularly tachyarrhythmias
- Other diseases affecting the myocardium—*ischaemic heart disease*, *hypertensive heart disease*, *infiltrative diseases* etc.

Box 8.1 Brief guide to the commonest murmurs**Aortic stenosis** (see  p.102)


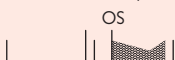- Harsh, rasping, sometimes musical, ejection murmur
- Aortic region, radiating to carotids
- Slow rising pulse, soft/absent A₂, LVH.

Aortic regurgitation (see  p.104)

- Early diastolic, de-crescendo murmur (\pm systolic flow murmur)
- Lower left sternal edge
- Collapsing pulse, displaced, hyperdynamic apex.

Mitral regurgitation (see  p.108)

- Soft, blowing, monotonous, pansystolic murmur
- Apex, radiating to axilla
- Displaced, hyperdynamic apex.


Mitral stenosis (see  p.106)

- Low-pitched, quiet, mid-diastolic rumble
- Apex, no radiation
- Opening snap, 'tapping' apex, AF, loud P₂ (pulmonary hypertension).

Symptoms/signs

- Breathlessness (most commonly):
 - Acute valve disease—onset over minutes/hours
 - Acute-on-chronic—onset over days/weeks (generally)
 - Cardiac decompensation—onset over hours–months
- Angina (AS, acute coronary ischaemia)
- Syncope (in AS or PS)
- Explosive, tearing back pain—aortic dissection.

Differential diagnosis

► It is vital to consider other causes of breathlessness (see  Chapter 3), as even if present, valve disease may be an innocent bystander. Previous notes/echocardiograms may be helpful in identifying any recent changes. If no change in valve or LV function, consider other diagnoses.

Clinical signs

- Signs of significant valve disease (see relevant sections in this chapter and Box 8.1)
- Signs of cardiac failure
- External stigmata of infective endocarditis
- Absent pulses in aortic dissection.

Investigations**Echocardiography**

Echocardiography is appropriate for any patient in whom the clinical picture suggests valve dysfunction as a cause of the acute presentation. This includes unexplained breathlessness or syncope with signs of valve disease, or pre-existing valve disease with worsening clinical signs (of the valve, or cardiac dysfunction). New or worsening clinical heart failure needs echocardiography too, for valvar and non-valvar causes.

Severely unwell patients with suspected true acute valve dysfunction need echocardiography ASAP. For presentations over days/weeks, the echocardiogram can usually wait 24–72 hours, depending on the clinical status of the patient.

NB Echocardiography is not indicated for unexplained pyrexia without other features of endocarditis, e.g. new valve disease or bacteraemia

CXR

To verify pulmonary oedema/seek other causes of SOB.

ECG

- Features of chronic valve disease (LVH—AS; broad P wave—MS; AF—MS/MR)
- Fast AF/other arrhythmia?—cause of acute decompensation?
- Long PR interval?—aortic root abscess?
- Acute MI/ischaemia?

Blood tests

- FBC—anaemia causing/exacerbating SOB; high WCC indicating infection (endocarditis, chest, other)
- U&E—reduced renal perfusion, nephropathy s to endocarditis, high/low K^+ causing arrhythmia, baseline test
- ESR and CRP—infection?
- Blood cultures—if endocarditis suspected: 3/6 sets over 24–48 hours.

Box 8.2 Grading of systolic murmurs¹

Grade

- 1 Barely audible
- 2 Soft but readily detected
- 3 Prominent
- 4 Loud, usually with thrill
- 5 Very loud with thrill
- 6 So loud, can be heard with the stethoscope just off the chest

1. Levine SA. The *systolic murmur*: its clinical significance. *JAMA* 1933; **101**: 436–8.

Box 8.3 How to recognize an innocent ('flow') murmur

- Soft ejection systolic murmur
- Grade ≤ 2
- Usually heard along left sternal edge/pulmonary region; occasionally at the apex
- Normal heart sounds
- No associated thrills or added sounds
- No signs of LV dilatation
- Normal ECG and no cardiac abnormalities on CXR.
- ▶ Innocent murmurs do not need echocardiography.
- ▶ Diastolic, pan-systolic, and loud murmurs (grade 3+) are not 'innocent'.

General management

- Identify and treat cause
- Treat heart failure if present—usually diuretics (e.g. furosemide 80 mg IV or more) ± vasodilators for regurgitant lesions (ACE inhibitors, or if severe, IV nitrates/sodium nitroprusside; p.74)
- Avoid β -blockers in AR—these lengthen diastole, worsening the AR, and also prevent a compensatory tachycardia.

▶▶ Acute valve regurgitation may require urgent transfer to a tertiary centre with cardiothoracic surgical facilities—discuss with cardiologist/cardi thoracic surgeon. These patients are usually very unwell and ITU care may be required. They may require emergency valve surgery (Table 8.1).

▶ For acute-on-chronic lesions and decompensation, most patients need inpatient referral to a cardiologist for consideration of valve replacement surgery. This may be the first presentation with symptoms, which are important for deciding on surgery.

Other, lesion-specific advice is given in the relevant sections in the rest of this chapter.

Table 8.1 Indications for valve surgery**Emergency (within few hours):**

- Acute valve regurgitation with severe heart failure (NYHA 3 or 4)
- Type A aortic dissection ± AR
- Postinfarct MR
- Ruptured sinus of Valsalva aneurysm

Urgent (inpatient):

- Rapidly increasing SOB or pulmonary oedema with chronic valve lesion
- Unstable prosthetic valve
- Uncontrolled infective endocarditis despite adequate antibiotics:
 - Heart failure due to valve dysfunction
 - Valve obstruction from vegetation/thrombus
 - Fungal and other antimicrobial resistant endocarditis (e.g. *Brucella*, *Coxiella*)
 - Cardiac abscess formation (usually aortic root)
 - Persistent bacteraemia (after 7–10 days)*
 - Recurrent emboli*
 - Large (>10 mm) mobile vegetations (↑ risk of embolization)*
- Early prosthetic valve endocarditis (<2 months from implantation)

Elective:

- Severe AS (peak gradient >50 mmHg) with stable symptoms or asymptomatic LV dysfunction (EF <50%)
- Severe MR:
 - If symptomatic (NYHA ≥2)
 - If asymptomatic with reduced LV function (EF <60%) or end-diastolic diameter >7.0 cm or end-systolic diameter >4.5 cm
- Severe AR:
 - If symptomatic (NYHA ≥2)
 - If asymptomatic with reduced LV function (EF <50%) or end-diastolic diameter >7.5 cm or end-systolic diameter >5.5 cm
- Moderate–severe valve disease if other cardiac surgery planned

*Relative indication - surgery may be considered.

Further reading

- ACC/AHA 2006 guidelines for the management of patients with valvular heart disease. Bonow RO et al. *Circulation* 2006; **114**: e84–231; available at: <http://circ.ahajournals.org>
- ACC/AHA/ASE Guideline Update for the Clinical Application of Echocardiography. Cheitlin MD et al. *Circulation* 2003; **108**: 1146–62; available at: <http://circ.ahajournals.org/cgi/content/full/108/9/1146>

Emergency non-cardiac surgery

(See  p.298 for full details.)

If a patient needs emergency surgery and has a concomitant valve lesion, this needs careful assessment. In practice, regurgitant lesions are rarely a problem—the afterload reduction from anaesthetic agents and hypovolaemia tends to reduce any valve leak.


Severe aortic, pulmonary, or mitral stenosis may cause difficulties (moderate disease is mostly OK). The lack of capacity to increase cardiac output significantly is the major problem, and these patients are at higher operative risk. They require careful attention to fluid balance and haemodynamics—large shifts are to be avoided.

In some cases, valve replacement surgery may be required prior to non-cardiac surgery, but the relative risks of valve replacement, delaying the non-cardiac surgery, and proceeding with non-cardiac surgery with appropriate care should be assessed. Non-cardiac surgery for a life-threatening condition should clearly proceed, and the ↑risk accepted.

Chronic valve disease

Most valve lesions are managed conservatively, particularly if patients are well. In the absence of symptoms or progressive LV dysfunction, there is rarely a need for surgery and these patients can be managed as outpatients with follow-up, often on an annual basis. Progression to LV dysfunction/excess dilatation or development of symptoms should prompt consideration of surgery. Mild disease may not need follow-up.

Antibiotic prophylaxis

Most patients with chronic valve lesions are at a slightly ↑risk of endocarditis, but prophylactic antibiotic therapy prior to dental and surgical procedures may not significantly alter this risk, and new guidelines have emerged recently. See  p.134 for details.

This page intentionally left blank

Aortic stenosis

The commonest valve lesion; prevalence 2% at >65 years of age.

Causes

- Degenerative (most common)
- Bicuspid aortic valve (may be accelerated degeneration). Bicuspid valves also have an association with both coarctation and aortic dilatation \pm dissection, even in the absence of aortic valve dysfunction
- Previous rheumatic fever.

Clinical features

Symptoms

- May be none
- SOB, syncope, or angina may all occur and signify poor prognosis

Signs

- Harsh, musical, ejection systolic murmur best heard in aortic region, radiating to carotids
- If severe: slow-rising pulse, heaving non-displaced apex, soft or absent S₂
- LV hypertrophy on ECG.

Δ Sub-aortic obstruction, hypertrophic obstructive cardiomyopathy.

Acute problems

Acute presentation of chronic disease

- Symptom onset can be rapid (days/weeks) and should prompt consideration for aortic valve replacement (AVR)
- If LV function poor, may be in intractable pulmonary oedema—AVR is the only treatment. Many patients improve if they survive surgery.

Acute stenosis

- Rare
- Causes: thrombus on prosthetic valve, vegetation
- Usually requires prompt AVR.

Treatment

Aortic valve replacement

This is the only real 'cure' and is performed if symptomatic severe AS.

Medical (for temporary relief)

- SOB can be treated with diuretics
- β -blockers may be useful, particularly for angina
- Vasodilator drugs should be used cautiously (risk of hypotension).

Balloon valvuloplasty

May be used in younger patients (less calcified valve) as a holding measure to defer surgery (e.g. if pregnant).

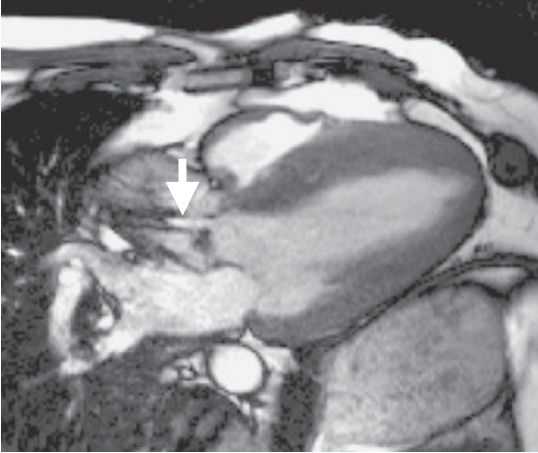


Fig. 8.1 Cardiac magnetic resonance image of severe AS, demonstrating a high velocity eccentric jet of aortic flow.

Aortic regurgitation

Causes

Acute: type A aortic dissection, aortic valve endocarditis, trauma.

Chronic: previous infective endocarditis, aortic root dilatation (including Marfan syndrome), degenerative valve, previous rheumatic fever.

Clinical features

- Acute AR causes sudden severe SOB and pulmonary oedema
- In severe chronic disease, SOB may be the only symptom.

Signs

- Early diastolic, decrescendo murmur heard at the lower left sternal edge, best in expiration
- \pm ejection systolic flow murmur (\uparrow forward flow across valve)
- In severe disease:
 - Collapsing pulse
 - Displaced, hyperdynamic apex (due to dilated LV)
 - Other eponymous signs, mostly due to widened pulse pressure (see Table 8.2).

Acute problems

🚑: Acute (sudden) regurgitation

- Patient is extremely unwell, and often in pulmonary oedema
- Needs emergency valve replacement (\pm aortic root replacement if dissection)
- Holding treatments while surgery arranged: diuretics, vasodilators, inotropes, ventilation—**not** IABP as this worsens the AR.

① Acute presentation of chronic disease

Once symptoms develop in chronic disease, AVR should be considered, so these patients fall into this category.

Mixed aortic valve disease

- True mixed aortic valve disease should be differentiated from AR with \uparrow systolic aortic flow velocity 2° to \uparrow stroke volume, and from AS with a mild leak (not uncommon).
- The relative severity of each component (stenosis/regurgitation) is variable, though predominant stenosis is more common and is the more significant problem.
- The combination of a narrowed outlet and need for \uparrow stroke volume places substantial demands on the myocardium, and the LV is often very hypertrophied and responds poorly to rapid changes. Acute problems can therefore occur more readily, e.g. deterioration with the onset of AF.

Causes

Bicuspid valve, rheumatic heart disease, endocarditis on AS, previous (partially successful) valvuloplasty for stenosis.

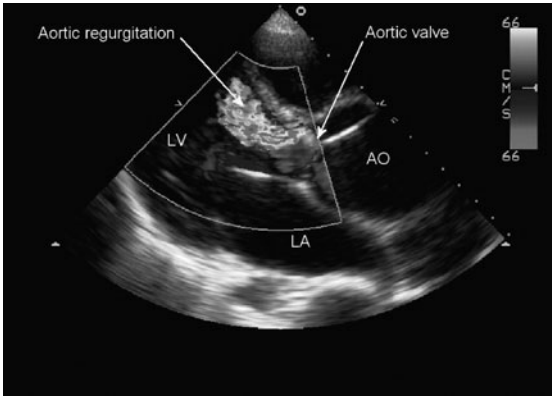


Fig. 8.2 Parasternal transthoracic echocardiogram demonstrating a broad jet of AR in a patient with a dilated aorta (AO).

Table 8.2 Eponymous signs in severe AR

Sign	Clinical features
Corrigan's	Visible carotid pulsation
de Musset's	Head bobbing with each pulse
Müller's	Visible uvula pulsation
Quincke's	Visible capillary pulsation in nail bed
Traube's	Systolic and diastolic femoral sounds ('pistol-shot' femorals)
Duroziez's	Compression of femoral artery proximally causes systolic bruit; distal compression causes proximal bruit

Mitral stenosis

Incidence has significantly declined in developed countries due to the reduction in its major cause, rheumatic fever.

Causes

- Previous rheumatic fever
- Other rare causes: congenital, bulky vegetation, atrial myxoma.

Clinical features

Acute MS is extraordinarily rare. Most present chronically—insidious onset, with SOB, fatigue, or reduced exercise tolerance.

Signs: AF not uncommon, malar flush, prominent 'a' wave in JVP

Auscultation: prominent S₁, opening snap, low-pitched mid-diastolic rumbling murmur with pre-systolic accentuation (atrial contraction)

ECG: bifid P wave (\pm peaked P wave if pulmonary hypertension), AF.

Acute problems

- Often caused by \uparrow heart rate. This is tolerated badly due to the \uparrow time required for passage of blood across the stenotic valve.
- Common causes: AF, exercise, infection (esp. chest), pregnancy
- Present with SOB \pm heart failure

① Atrial fibrillation

With acute AF, the loss of atrial contraction in addition to the sudden increase in heart rate can rapidly precipitate heart failure.

Treatment

►► The combination of heart failure and mod-severe MS is difficult to treat and expert help should be sought urgently.

- Diuretics
- Rate control (digoxin for AF; diltiazem/verapamil, β -blockers)—this is a difficult balance in a patient with heart failure
- Consider cardioversion for acute AF (not useful for chronic)
- ?Balloon valvuloplasty.

Longer-term issues

Atrial fibrillation

Permanent AF is common in MS and rate control is required.

► Anticoagulation is vital—thrombotic risk is huge (11 \times other AF).

Surgery—for symptoms, or pulmonary hypertension. Options:

- Closed valvotomy (separation of fused cusps)
- Open valvotomy (on cardiac bypass)
- Mitral valve replacement.

Balloon valvuloplasty

- For valves without significant calcification or regurgitation
- Can give moderate relief for several months/years but restenosis usually occurs
- Particularly good for acute presentations in pregnancy.

This page intentionally left blank

Mitral regurgitation

Causes

The mitral valve is a complex structure, relying on the papillary muscles, chordae, and myocardial motion for its effective function. Intrinsic valve disease may not therefore be the only cause of dysfunction, and other causes should be excluded.

Acute: infective endocarditis, MI (papillary muscle infarction, rupture, or tethering to infarcted LV wall), ruptured chordae tendinae, trauma.

Chronic: degenerative disease, mitral prolapse (Box 8.4), dilated LV, myocardial dysfunction 2° to ischaemia, previous rheumatic fever.

Clinical features

Symptoms

- Acute MR causes sudden, severe SOB and pulmonary oedema
- Chronic disease may be asymptomatic for many years
- In severe chronic disease, SOB may be the only symptom and should prompt consideration of valve replacement, especially if new.

Signs

- Pan-systolic murmur (soft, blowing) at apex, radiating to axilla
- If severe:
 - Wide splitting of S₂, due to early aortic valve closure
 - Loud S₃
 - Displaced, hyperdynamic apex.

Acute problems

⚠️ Acute (sudden) regurgitation

- Commonest cause is post-MI—papillary muscle involvement
- Patient is extremely unwell, and often in pulmonary oedema
- Needs emergency valve replacement/repair (?of papillary muscle)
- Holding treatments while surgery arranged (Box 8.5)—diuretics, inotropes, vasodilators, ventilation, IABP.

① Acute presentation of chronic disease

Like AR, once symptoms develop in chronic disease, valve replacement/repair should be considered, but it is important to exclude a 'functional' cause for MR such as a dilated LV with poor function, or ischaemia, as these should be treated directly.

In chronic MR, LV pressure is 'off-loaded' by the flow of blood into the low pressure LA. Therefore the function should appear good and, in severe MR, vigorous. A 'normal' or slightly reduced EF in the presence of severe MR may thus in fact represent early LV dysfunction. Systolic LV dilation on echocardiography (>4.5 cm) is a good indicator of LV dysfunction.

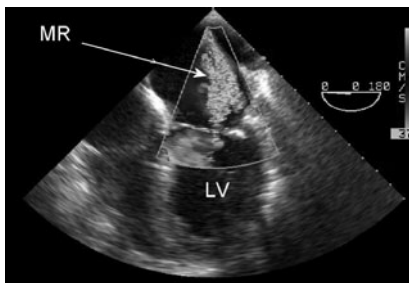


Fig. 8.3 Transoesophageal echocardiogram demonstrating MR.

Box 8.4 Mitral prolapse (floppy mitral valve)

- Usually idiopathic; prevalence 5–10% of the population but mostly benign condition
- If no or trivial regurgitation is present, does not need follow up
- \geq mild regurgitation needs follow-up but not endocarditis prophylaxis
- Symptoms sometimes from ectopic beats. Reports of atypical chest pain are inconsistent. Neither are serious
- Classical late-systolic murmur if regurgitation present
- Can degenerate to severe MR requiring surgery.

Box 8.5 Surgery in mitral regurgitation

Valve replacement: for intrinsic, severe disease unsuitable for repair. Metal prostheses are used—bioprosthetic valves tend to degenerate quickly, and are not routinely placed in the mitral position.

Valve repair: for severe MR 2° to prolapse, where the valve anatomy is otherwise reasonably normal. Rheumatic and other damaged valves are not usually suitable. Posterior leaflet repair is much more successful than anterior, though it is a technically demanding operation and both types require an experienced surgeon. Even in the best hands, repair is not always successful, and replacement is the fall-back position. Long-term results are good in selected cases, and minimally-invasive repair, utilizing robotic arms, has been successful in a handful of cases to date.

Valve ring insertion: for cases where the mitral annulus is enlarged, causing failure of coaptation of the leaflets (from either LV or LA enlargement). A 'C'-shaped ring is sewn around the valve to reduce the annular size and restore integrity of function. Commonly combined with valve repair for prolapse with dilated LA/LV and with CABG for ischaemic, dilated LV, and functional regurgitation.

Papillary muscle repair: in cases of papillary rupture (usually 2° to MI), re-attachment of the papillary muscle may be all that is required for restoration of valve function. CABG may be performed at the same sitting, to deal with the coronary stenosis, but this depends on the clinical situation.

Pulmonary stenosis

Causes

Congenital (may be in conjunction with other defects, e.g. Fallot's tetralogy), rheumatic fever, carcinoid.

Clinical features

Few symptoms—SOB if severe.

Signs: RV heave, prominent 'a' wave in JVP \pm TR, quiet P₂, soft ejection systolic murmur at upper left sternal edge.

ECG: RVH, P pulmonale.

Acute problems

Rare—rapid increase in heart rate can lead to right-sided heart failure.

Treatment

- Balloon valvuloplasty. Usual first-line treatment; effective and may be repeated in future. PR is the main side effect and is usually tolerated well.
- Surgical (open) valvotomy—very effective with good long-term results
- Pulmonary valve replacement (rarely required). Percutaneous stent-valves are an option in selected cases.

Pulmonary regurgitation

Causes

Congenital, endocarditis, 2° to pulmonary hypertension, following balloon valvuloplasty or open valvotomy

Clinical features

Tolerated extremely well mostly. SOB if v. severe, or RV failure occurs

Signs: RV heave, loud \pm delayed P₂, \pm soft pulmonary ejection murmur, diastolic decrescendo murmur at mid left sternal edge, RV failure

ECG: RVH

Acute problems

Rare—RV failure may develop and present acutely; acute pulmonary hypertension (e.g. from pulmonary embolus) may cause PR.

Treatment

- Usually none required (tolerated very well)
- Treat any RV failure
- Treat cause of pulmonary hypertension
- If severe symptoms and RV failure, pulmonary valve replacement can be considered. If suitable size and anatomy of outflow tract, a percutaneous stent-valve may be considered (bioprosthetic valve mounted inside a stent)

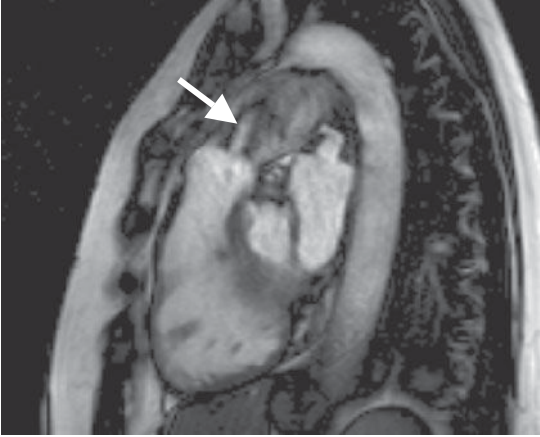


Fig. 8.4 Cardiac magnetic resonance image showing the RV outflow tract. There is significant PS (arrow indicates high velocity jet).

Tricuspid stenosis

Causes

Rare—mostly rheumatic fever (usually in association with MS), carcinoid, or very rarely due to a pacemaker lead.

Clinical features

Fatigue, SOB.

Signs: raised JVP with prominent 'a' wave, mid-diastolic murmur at left sternal edge—similar to MS but higher pitch, hepatomegaly and peripheral oedema if severe.

Acute problems

- Almost never
- Acute stenosis could occur with large infective vegetation.

Treatment

- Diuretics
- Balloon valvuloplasty or surgical valvotomy at the time of other (usually mitral) lesions are dealt with
- Valve replacement is avoided due to the difficulty with low right-sided venous pressures and the resistance to flow from a prosthetic valve

Tricuspid regurgitation

Small degrees are very common and usually unimportant.

Causes

Any cause of RV dilatation, pulmonary hypertension, congenital (including Ebstein's anomaly), Marfan syndrome, endocarditis, carcinoid.

Clinical features

- Minimal symptoms
- Right heart failure can develop if severe

Signs: Large 'v' waves in JVP, pulsatile hepatomegaly, (peripheral oedema, ascites \pm jaundice if significant RV failure), very soft pan-systolic murmur at left sternal edge.

Acute problems

- Rare
- Tricuspid endocarditis may occur in IV drug users, and is frequently staphylococcal. It follows an aggressive course and needs intensive antibiotic treatment.

Treatment

- Usually none required
- Diuretics are the mainstay of treatment for symptoms and RV failure
- Tricuspid valvuloplasty, annuloplasty, and valve replacement are rarely undertaken and long term results are disappointing.

This page intentionally left blank

Prosthetic valves

Types

Bioprosthetic

- Obtained from human cadavers (homograft), or manufactured from bovine or porcine pericardium (xenograft; e.g. Carpentier–Edwards). Pericardial valves may be suspended from 3 metal struts ('stented' valve) or contained within a covered wire frame (stentless)
- Do not require long-term anticoagulation. Usually require 6 weeks of either warfarin or aspirin post-surgery while surfaces endothelialize
- Generally last 10–15 years—for this reason, are usually implanted in:
 - Older patients, who also tend to be less active, reducing the physical burden on the valve
 - Those in whom anticoagulation is contraindicated
 - Young women who may be considering pregnancy.

Metallic

- Three main sub-types:
 - Ball and cage (e.g. Starr–Edwards)—older style, unlikely to be implanted now. Durable, and long track record, but higher resistance to flow and high thrombogenicity
 - Single tilting disc (e.g. Björk–Shiley, Medtronic Hall)
 - Bileaflet tilting disc (e.g. St. Jude, ATS 'Advancing The Standard')—commonest used today. Good track record, low resistance to flow, and low thrombogenicity
- Durable (can last >20 years) but thrombogenic, so require lifelong anticoagulation.

Clinical

- Bioprosthetic valves should sound little different from native valves, but may have a flow murmur
- Metallic valves have a distinctive 'click' as the valve either opens or closes. This should be a crisp sound—a dull or indistinct sound suggests thrombus or vegetation on the valve
- Annual follow-up is routine for patients with prosthetic valves
- For guidance on antibiotic prophylaxis, see 📖 p.134.

Echocardiography

Systolic flow velocities are in general increased with a normally-functioning prosthetic valve. Metal prostheses can have high velocities (>3 m/sec) and the normal range for that valve needs to be taken into account. The smaller the valve, the higher the forward velocity.

- **Biological:** homografts look like normal valves; pericardial valves have a smaller valve ring in general and hence have slightly ↑flow velocities, though the newer stentless type look virtually normal and have normal flow velocities
- **Metallic valves** cause echo 'shadows' which limit the available information. TOE may therefore be required on occasions to assess valve function in detail. With tilting-disc valves, it is normal to see tiny regurgitant 'wash' jets

Examples of prosthetic valves

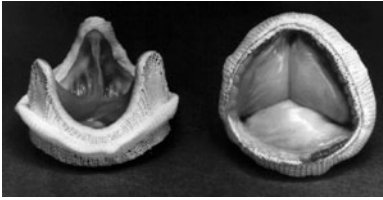


Fig. 8.5 Carpentier–Edwards bioprosthesis valve.



Fig. 8.6 Ball-and-cage valve.



Fig. 8.7 Bi-leaflet tilting valve.

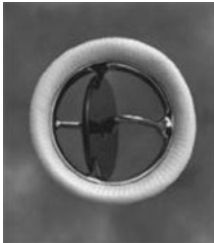


Fig. 8.8 Single tilting disc valve.

Complications

Thrombosis

Usually from inadequate anticoagulation patients. The risk is higher with mitral prostheses patients. Present with heart failure (from malfunctioning valve) or systemic emboli. Treat with heparin anticoagulation \pm thrombolysis, thrombectomy, or valve replacement.

Other anticoagulation problems

See Box 8.6

Haemolysis

- Small amounts of haemolysis are common with metallic valves. Significant haemolysis is usually 2° to valve dysfunction—paravalvular leak, valve dehiscence, or endocarditis
- Bloods: anaemia, \uparrow reticulocyte count, \uparrow LDH, \downarrow haptoglobins
- Urinary haemosiderin present
- Treat the anaemia with ferrous sulphate \pm blood transfusions and the underlying cause—may require re-do valve replacement surgery, though there are new percutaneous devices which can be used for closing paravalvular leaks.

Endocarditis

~5% patients with prosthetic valves may develop this

- Early prosthetic valve endocarditis (<2 months post-implantation) is usually due to contamination at the time of surgery or IV cannulae. Common organisms: *S. aureus*, *S. epidermidis*, Gram-negative bacteria, fungi
- Late prosthetic valve endocarditis has similar organisms to native valve endocarditis.

Box 8.6 Anticoagulation for metal valves: acute issues

In general, the risk of thrombosis on a metallic valve without anticoagulation for a few days is low, though should be minimized with heparin where possible.

Emergency surgery

- INR can be normalized with fresh frozen plasma (FFP) to allow emergency surgery. Once stable post-surgery, warfarin can be re-started.

Acute haemorrhage

- In general, the risk to the patient of an acute haemorrhage (e.g. GI or intracranial bleed) far outweighs the risk of thrombosis on a metal valve, and warfarin should be reversed with FFP \pm vitamin K until the haemorrhagic risk has subsided. Even the highest estimates of the risk of prosthetic valve thrombosis without any anticoagulation are around 30–50% *per year* (~0.5–1% per week). The short-term bleeding risk in acute haemorrhage is usually much higher than this, so the balance of risks is in favour of treating the haemorrhage and accepting a small risk of valve thrombosis.

Elective procedures requiring cessation of anticoagulation

- Some procedures (e.g. dental extraction) can be done with a lowering of the INR to ~ 2.5 rather than cessation of warfarin
- For surgery or other procedures where anticoagulation needs to stop, patients are normally admitted a few days in advance, and IV UFH substituted for the warfarin. This can then be stopped a few hours prior to the surgery and re-started when the surgeon is happy the bleeding risk is low, minimizing the time without anticoagulation. LMWH has not been adequately assessed for prosthetic valves and should be avoided. Warfarin can be restarted and the patient discharged once the INR is >2.5 .

INR above normal range

- If there are no signs of significant bleeding (check for \uparrow HR \pm \downarrow BP), the aim is a gentle return to the therapeutic range. High dose vitamin K (>2 mg) will abolish the effect of warfarin for some time and make re-anticoagulation very difficult.
 - INR <6 : reduce warfarin dose/omit tablets
 - INR 6–8: stop warfarin and restart when INR <5
 - INR >8 : stop warfarin. If risk factors for bleeding, give 0.5–2.5mg oral vitamin K (phytomenadione)
- Major bleed: stop warfarin. Give FFP \pm 5mg vitamin K (slow IV or oral). Seek expert help to manage bleed.

Acute rheumatic fever

- An immunologically-mediated systemic inflammatory illness, with significant cardiac component, several weeks after group A streptococcal infection (often a sore throat)
- Incidence now very rare in developed world, but common in Indian sub-continent, the Middle East, and Australian aboriginals
- Commonly affects children age 5–15 years, but long-term damage to cardiac valves may result in problems in later life (Box 8.7).

Presentation

Carditis

- Onset tends to be more insidious
- A pan-carditis can occur, with pericarditis, myocarditis, and endocarditis:
 - Endocarditis, affecting the valves, is the most important aspect, and acute heart failure or chronic problems are usually due to this
 - Pericarditis ± effusion is common but rarely causes problems
 - Myocarditis may cause acute LV dysfunction, but this is rare
 - AV block (usually 1°)
- Regurgitant (esp. mitral) murmur is the commonest clinical feature.

Arthritis

- More rapid onset, over hours/days
- Large-joint, migratory polyarthritis, e.g. knees, ankles, wrists, elbows
- Can be exquisitely painful—one joint tends to predominate.

Other

- Fever (common); abdominal pain (rare)
- Sydenham's chorea ('St. Vitus' dance')—rhythmic, involuntary upper limb movements. Usually after prolonged latent period (6 months) and resolves after 6 weeks (occurs up to 6 months); usually affects females.
- Subcutaneous nodules and erythema marginatum.

Δ Infective arthritis; non-specific arthralgia in feverish child.

Treatment

- Bed rest until arthritis and any heart failure have resolved
- Penicillin for any remaining streptococci: benzylpenicillin (penicillin G) 1.2 g single dose IM or phenoxymethylpenicillin (penicillin V) 250 mg PO (adults 500mg) QDS for 10 days; erythromycin if penicillin-allergic (adults 250–500 mg QDS)
- Aspirin or other NSAIDs for arthritis (usually high dose: 80–100 mg/kg/day; adults 4–8 g/day, in divided doses)
- ? Corticosteroids—often still used, but evidence for benefit is low; prednisolone 40–60 mg/day, tapering after 2–3 weeks
- Treat heart failure; consider valve replacement if severe dysfunction
- Haloperidol or other drugs for chorea.

Prevention of recurrence

2° prophylaxis is required—phenoxymethylpenicillin 250 mg PO BD (or IM benzylpenicillin 1.2 g every 3 weeks). Minimum duration: 5 years or until age 21 (whichever is later); if severe valve destruction, continue to age 30 or more.

Box 8.7 Valve disease in acute rheumatic fever**Affected valves**

- Mitral (65–70%)
- Aortic (25%)
- Tricuspid (10%, with other valves)
- Pulmonary (rare)

Acute effects

Inflammation, destruction, and valve regurgitation.

Long-term effects (30–50%; 70% if severe carditis during acute phase):

- Regurgitation
- Stenosis due to scarring and contraction following the acute inflammation
- Valves typically appear thickened, with rolled edges and tips on echocardiography.

Valve repair

If valve surgery required, valves might be suitable for repair during the acute episode, but are usually unsuitable for repair in the chronic stage.

Table 8.3 Modified Jones criteria for diagnosis of initial attack of acute rheumatic fever (1992)*

Diagnosis requires both:

Demonstration of current/recent group A streptococcal infection

(culture or serological tests e.g. anti-streptolysin O. Chorea and late-onset carditis are exempt.)

and

2 major, or 1 major plus 2 minor criteria:

Major criteria

- Carditis
- Polyarthritits
- Chorea
- Subcutaneous nodules
- Erythema marginatum

Minor criteria

- Fever
- Arthralgia
- Elevated acute phase reactants
- Prolonged PR interval

*Recurrent attacks require only 1 major or 2 minor criteria, plus evidence of recent Gp A streptococcus and no other explanation for symptoms.

This page intentionally left blank

Infective endocarditis

- Introduction 122
- Mode of presentation 122
- Clinical features 124
- Diagnosis 124
- Investigations 126
- Management 128
- Prosthetic valve endocarditis 130
- Culture-negative endocarditis 130
- Complications 132
- Prophylaxis 134

Introduction

This condition still carries a high mortality (15–20%) despite modern antibiotics. Uncomplicated viridans streptococcal infections have a better prognosis, but staphylococcal and prosthetic valve endocarditis carry a high mortality. Potential reasons for the continued high mortality are an aging population, ↑incidence of prosthetic endocarditis, ↑lifespan of patients with congenital heart disease, ↑staphylococcal and fungal infections, tricuspid valve endocarditis from IV drug use, and antibiotic resistance.

Infective endocarditis is most likely to develop where underlying structural cardiac defects are present, and preventive measures are important in susceptible individuals. Endocarditis occurring on normal valves tends to involve the more virulent organisms, especially *S. aureus*. Other factors which increase risk are: ↑susceptibility to infection (old age, chronic alcoholism, haemodialysis, diabetes, immunosuppression) and recurrent bacteraemia (e.g. inflammatory bowel disease, colon carcinoma, IV drug use).

Mode of presentation

May be acute, sub-acute, or occasionally hyper-acute:

- Sub-acute—insidious onset over months usually
- Acute—presentation over 1–4 weeks.
- Hyper-acute—rapid deterioration over hours/days, usually due to acute valve regurgitation

While the classical sub-acute presentation, with months of non-specific malaise, still occurs, there is an increasing tendency towards acute presentations, which may reflect increasing numbers of more virulent organisms, e.g. *S. aureus* or the HACEK group (📖 Table 9.1, p.125).

The presentation is usually with non-specific symptoms and can mimic many other systemic diseases. A high index of suspicion is therefore necessary. Cardiac tumours can sometimes mimic endocarditis (esp. atrial myxoma) and these should also be considered.

This page intentionally left blank


Clinical features

These can be divided into 4 areas, listed here. Potential routes of infection should also be sought (e.g. teeth, skin)

Infection

- Fever
- Night sweats
- General malaise
- Weight loss
- If longstanding: anaemia, clubbing, splenomegaly.

Cardiac involvement

- New/altered murmur (see  box 9.1)
- Signs of severe valve regurgitation
- LV failure due to valve deterioration or direct involvement of the myocardial endothelium
- Prolonged PR interval if aortic root abscess.

Emboli

- Commonly: cerebral, retinal, coronary, splenic, mesenteric, renal.
- Pulmonary in right-sided endocarditis
- May develop into abscesses, or a mycotic aneurysm.

Immunological phenomena

Need time for development, and are thus rarer in acute presentations. They also do not occur with lesions on the right side of the heart.

- Petechiae, splinter haemorrhages in nail beds, Osler's nodes (tender nodules [infarcts] on finger pulps/palms/soles), Janeway lesions (painless palm/sole erythematous macules)
- Microscopic haematuria, glomerulonephritis, systemic vasculitis, arthralgia
- Roth spots (boat-shaped retinal haemorrhages with pale centre).

Diagnosis

► The cornerstone of diagnosis is microbiological evidence of infection. Adequate blood cultures are therefore vital in diagnosis.

Although helpful, echocardiography (even TOE) does not exclude endocarditis, and can produce false positive results. It is therefore crucial that an accurate clinical picture is obtained (also to exclude other sources of infection), and that rigorous measures are taken to identify any infective organism—sufficient blood cultures are key.

The diagnosis is usually based on a bacteraemia with a likely organism, coupled with evidence of cardiac involvement (e.g. *new* regurgitant lesion or vegetation). Investigations are \therefore aimed at identifying these and assessing severity and/or complications. Other features may sometimes be helpful in reaching a diagnosis, and the widely accepted Duke criteria for diagnosis (see Table 9.1) include these.

Box 9.1 Murmurs and endocarditis...

A new murmur in the context of a feverish, unwell patient is highly suspicious for endocarditis, but is not enough for a diagnosis without other supporting evidence. Remember that innocent 'flow' murmurs can occur with any infection, due to ↑cardiac output. A practical guide is to investigate any murmur that is more than 'innocent' (📖 Box 8.3, p.97) in a patient who is unwell. Knowing whether the murmur is new or old is, in practice, less relevant as endocarditis often occurs on valves with pre-existing lesions (i.e. murmurs).

Table 9.1 Modified Duke criteria for diagnosis of endocarditis

Confirmed diagnosis is based on either:

Pathological criteria:	organisms or histological evidence of active endocarditis in a vegetation (embolized or not) or intracardiac abscess
Clinical criteria:	2 major criteria, or 1 major and 3 minor criteria, or 5 minor criteria

Major criteria

Microbiological involvement—either:

- Typical microorganism for endocarditis from two separate blood cultures (viridans streptococci; *Strep. bovis*; HACEK group[†]; community acquired *S. aureus*/enterococci in the absence of a primary focus)
- Persistently positive blood cultures with consistent organisms (drawn >12 hours apart, or ≥ 3 +ve cultures with first and last drawn >1 hour apart)
- Positive serology or molecular biology for Q-fever, *Coxiella burnetii* or other causes of culture-negative endocarditis

Evidence of endocardial involvement:

- Oscillating intracardiac mass (vegetation)
- Abscess
- New partial dehiscence of prosthetic valve
- New valve regurgitation (either clinical or echocardiographic)

Minor criteria

- Predisposing heart condition or IV drug use
- Fever >38.0°C
- Vascular phenomena (arterial emboli, septic pulmonary infarcts, mycotic aneurysm, intracranial or conjunctival haemorrhage, Janeway lesions, splinter haemorrhages, splenomegaly, newly-diagnosed clubbing)
- Immunological phenomena (glomerulonephritis, Osler's nodes, Roth spots, +ve rheumatoid factor, high ESR >1.5 × normal, high CRP >100mg/L)
- Microbiological evidence: +ve blood culture not meeting major criterion*, or serological evidence of active infection with organism consistent with infective endocarditis.
- Echocardiography findings consistent with infective endocarditis but falling short of major criterion

[†]*Haemophilus, Acinetobacillus, Cardiobacterium, Eikenella, and Kingella* spp.

*Excludes single +ve culture for coagulase -ve *Staph.* and organisms not associated with infective endocarditis

Investigations

Blood cultures

► As mentioned earlier, these are crucial to the diagnosis.

3–6 sets of blood cultures should be obtained: 6 is the norm if suspicion is high but the diagnosis unclear and the patient relatively well; 3 can be taken if the patient is very unwell and urgent antibiotics are required for a likely diagnosis of endocarditis. Each set should be taken from a different site and, ideally, spaced at intervals >1 hour.

Echocardiography

Echocardiography should be performed if there is a high clinical suspicion of endocarditis (see Box 9.2). It is valuable for diagnosis and detecting any complications, but it should be remembered that bacteria are smaller than the resolution of echocardiography(!) and a normal echocardiogram does not exclude endocarditis. Good clinical and microbiological evidence are therefore important irrespective of the echo.

Transthoracic echocardiography (TTE) has a high specificity for vegetations (98%) but low sensitivity (60%) and TOE may be required if suspicion is high. Combined TTE and TOE have a high negative predictive value (95%) but note this is not 100%, underlining the importance of the other diagnostic features.

Native valves

TTE should be the initial investigation. TOE is required when the TTE images are of poor quality, when high clinical suspicion remains despite a normal TTE, or when a prosthetic valve is involved.

Prosthetic valves

TOE is nearly always required for better visualization but important information can still be obtained from TTE, so it is normal to perform this at the same time, just prior to the TOE.

Strong echocardiographic evidence for endocarditis:

- Characteristic vegetations
- Abscesses
- New prosthetic valve dehiscence
- New regurgitation.

Other bloods

- FBC—anaemia, neutrophilia
- ESR, CRP—non-specific but raised in 90% of endocarditis cases
- U&Es—renal function needs regular assessment
- Serum for immunology for atypical organisms.

Urinalysis

- Microscopic haematuria ± proteinuria
- Red cell casts and heavy proteinuria if glomerulonephritis.

ECG

Lengthening PR interval (?aortic root abscess).

Box 9.2 Indications for echocardiography¹

—when clinical suspicion is high:

- New valve lesion (usually regurgitant murmur)
- Embolic events of unknown origin
- Sepsis (i.e. bacteraemia plus systemic features) of unknown origin
- Haematuria, glomerulonephritis and suspected renal infarction
- Fever *plus*:
 - +ve blood cultures for organisms typical for endocarditis
 - High predisposition for endocarditis e.g. prosthetic valve
 - First manifestation of heart failure
 - Newly-developed conduction disturbance or ventricular arrhythmias
 - Typical immunological manifestations of endocarditis
 - Multifocal/rapidly changing pulmonary infiltrates
 - Peripheral abscesses of unknown origin (e.g. renal, splenic, spinal)
 - Predisposition plus recent diagnostic/therapeutic intervention known to result in significant bacteraemia

NB A fever without other evidence for endocarditis is not an indication for echocardiography.

1. Baddour LM *et al.* Infective endocarditis. Diagnosis, antimicrobial therapy, and management of complications. AHA Scientific Statement. *Circulation* 2005; **111**: e394–e434; <http://circ.ahajournals.org/cgi/content/full/111/23/e394>

Box 9.3 Differentiating tumours from endocarditis

Differentiating tumours and infective vegetations can sometimes be difficult if a mass is seen on echocardiography. Tumours may also become infected, further complicating the picture.


There are no hard rules to guide diagnosis, but the following aspects are more typical for endocarditis:

- Mass attached primarily to a valve rather than myocardium
- Smaller size of mass/vegetation (<3 cm)
- Long, strand-like appearance
- Typical clinical picture
- Typical organism on blood cultures
- Resolution with successful antimicrobial therapy.

Management

General considerations

► Seek expert cardiology and microbiological advice—endocarditis is a serious condition that requires specialist management, in particular to recognize and treat the complications. A general framework is:

- Treat heart failure and shock as appropriate
- Ensure blood cultures are taken prior to starting antibiotic therapy
- Give antimicrobial therapy in adequate doses IV for 4–6 weeks
- Monitor response to therapy—both clinically and biochemically
- Consider surgery if significant complications arise (see  p.132)

Antimicrobial therapy

Choice of therapy

► This can be difficult, and requires local knowledge of sensitivities etc. In all cases, discuss with microbiology/infectious disease specialists first.

Therapy is guided by the organism (hence the importance of identification), and a *general* guide is shown in Table 9.2.

Treatment duration

In general prolonged (4–6 weeks) IV therapy in high doses is required. Occasionally, shorter courses may be appropriate for very sensitive streptococci (Box 9.4). A central venous catheter is usually inserted—either a tunnelled or peripherally inserted (PICC) line—to facilitate IV therapy and ↓infections and other complications from repeated peripheral cannulae.

Uncomplicated cases

Antibiotics should **not** be started until good evidence for the diagnosis is available; patients can normally wait 48–72 hours, allowing time for initial blood culture results. If antibiotics have been taken within the last week, wait at least 48 hours before taking blood cultures.

Severely unwell patients

Unwell patient (with sepsis, severe valve dysfunction, conduction disturbances, or embolic events) with a presumptive diagnosis of endocarditis, should receive empirical antibiotic therapy (see Table 9.3) *after* 3 sets of blood cultures have been taken. Treatment can be adjusted once culture results are known.

Valve replacement surgery (see Table 8.1 p.99)

- 30% require this during the acute episode—consider if valve function deteriorates and causes heart failure, or infection remains uncontrolled despite adequate therapy, or significant complications arise
- Although valve replacement surgery during active endocarditis carries a risk of reinfection of the prosthesis, the risk is relatively low (~5%)
- If cerebral emboli/haemorrhage have occurred, surgery should be deferred for 10 days—3 weeks if possible. This allows some time for recovery before cardiopulmonary bypass, with its risks of anticoagulation and cerebral hypoperfusion.

Table 9.2 A guide to antibiotic therapy¹

► Seek local microbiological advice in all cases, tailored to the patient. This is only a rough indication of antibiotic regimens.

Viridans streptococci and *Strep. bovis*

- Benzylpenicillin 4 weeks + gentamicin 2 weeks or ceftriaxone 4 weeks

Enterococci

- Benzylpenicillin or amoxicillin 4–6 weeks + gentamicin 4–6 weeks

HACEK group

- Benzylpenicillin or amoxicillin or ciprofloxacin 4 weeks

Staphylococci

- *Methicillin-sensitive*: flucloxacillin 4 weeks + gentamicin 3–5 days
- *Methicillin-resistant*: vancomycin 4 weeks + gentamicin 3–5 days

Prosthetic valves

- Continue benzylpenicillin/ceftriaxone for 6 weeks & gentamicin 2–6 weeks; add rifampicin for 6 weeks if staphylococci

Penicillin-allergic patients: vancomycin replaces penicillin

Doses

Benzylpenicillin	7.2–14.4 g IV daily in 4–6 divided doses, depending on penicillin sensitivity
Ceftriaxone	2 g IV daily in 1 dose
Gentamicin	3 mg/kg IV daily (max. 240 mg/day) divided into 3 doses, or given as a single dose, according to local guidelines; requires blood level checking; dose interval ↑ in renal failure
Amoxicillin	12 g IV daily in 4–6 divided doses
Flucloxacillin	8–12g IV daily in 4 divided doses
Vancomycin	30 mg/kg IV daily in 2 divided doses (infused over 2 hours), titrated to trough levels
Rifampicin	300 mg BD PO

1. Baddour LM *et al.* Infective endocarditis. Diagnosis, antimicrobial therapy, and management of complications. AHA Scientific Statement. *Circulation* 2005; **111**: e394–e434; <http://circ.ahajournals.org/cgi/content/full/111/23/e394>

Table 9.3 Empirical treatment for endocarditis (only if essential)**Be guided by the clinical setting:**

1. Onset over weeks:	Benzylpenicillin/amoxicillin + gentamicin
2. Rapid onset (days) or history of skin trauma (likely staphylococcus)	Vancomycin + gentamicin
3. Recent prosthetic valve (<1 year):	Vancomycin + gentamicin + rifampicin
4. Distant prosthetic valve (>1 year):	As for (1) + rifampicin

Box 9.4 Shorter treatment regimens (~2 weeks)

May be possible, but only in consultation with microbiology, and if *all* listed criteria apply:

- Infection with fully sensitive *Streptococcus* on native valve
- Rapid response to treatment within 1st 7 days
- Any vegetations on echocardiography <1 mm
- No cardiovascular complications
- Home situation suitable.

Prosthetic valve endocarditis

- Often requires replacement of the valve, though even then recurrence rates are high (9–20%). This is due to the difficulty of eradicating infection from prosthetic material. Bioprosthetic valves can sometimes be treated with antibiotics alone but the need for re-do surgery is still higher than for native valves
- Even with good TTE, TOE is required to visualize the valve properly due to the shadowing effect of the valve ring/metal discs
- Prolonged antibiotic therapy is required (6 weeks)
- Warfarin is often replaced with heparin, for better control of anticoagulation and potential surgical situations.

Culture-negative endocarditis

5% of all cases.

Causes

- Previous antibiotic therapy—the most common cause
- Unusual organism – HACEK group, *Brucella*, *Chlamydia*, *Coxiella* (Q fever), *Legionella*, *Bartonella*, *Mycobacteria*, *Nocardia*, fungi (*Candida*, *Aspergillus*, *Histoplasma*).

Management

- Consider other (non-cardiac) causes for fever
- If high clinical suspicion for endocarditis remains, consult with microbiology regarding:
 - Prolonged or special cultures; serology of unusual organisms
 - Recommended antimicrobial therapy
- If valve replacement surgery is required, the excised valve should be sent for culture and broad spectrum PCR for DNA identification of organisms.

This page intentionally left blank

Complications

Especially common with *S. aureus*

Cardiac

- Abscesses (20–40% native valves; 50–100% prosthetic valves)—valve ring, intramyocardial or pericardial. Usually require valve replacement + debridement of the abscess
- Valve rupture, perforation, or regurgitation
- Sinus of Valsalva rupture (2° to abscess). Requires emergency surgery
- VSD—from myocardial abscess rupture
- LV failure—due to valve dysfunction or direct myocardial involvement
- AV heart block—due to aortic root abscess
- Relapse of endocarditis
- Chronic valve regurgitation—if significant regurgitation occurs, but not enough to require urgent valve replacement, valve replacement may be required in the future (20–40% of cases). The indications are the same as for other causes of regurgitation.

Non-cardiac

Emboli (20–40%)

- Can lead to stroke, peripheral arterial occlusion, or organ infarcts
- May also cause abscesses due to infected nature of embolic material
- Abdominal abscesses should be operated on prior to cardiac surgery
- Splenic abscesses are particularly prone to rupture and splenectomy may be required.

Mycotic aneurysms (2–15%)

- Often caused by embolized infected material
- Common sites: sinuses of Valsalva; intra-cranial, mesenteric, and renal arteries
- Intracranial aneurysms have a high mortality (60%), ↑ if rupture occurs (→ sub-arachnoid haemorrhage: 80% mortality).

Renal failure

Due to multiple potential causes:

- Sepsis
- Dehydration
- Glomerulonephritis
- Emboli.

This page intentionally left blank

② Prophylaxis

Simple measures are important in preventing bacteraemia for patients at risk. Good oral and feet hygiene, and attention to cuts and skin disorders which may allow bacteria to penetrate the skin are important (especially in diabetics).

Antibiotic prophylaxis

Antibiotic prophylaxis for selected patients has been accepted practice for many years. Several recent reviews however have concluded that there is little evidence for its effectiveness. While dental or other surgical procedures cause a modest bacteraemia, this is only a tiny additional amount when compared to the background bacteraemia from normal daily activities (e.g. tooth brushing). Thus, even if antibiotic prophylaxis was 100% effective following these procedures, it would only be targeting a small proportion of the risk, and new guidelines suggest that this would not justify the use of antibiotics.

This doesn't alter the fact that certain patients are at higher risk of endocarditis, but occasional antibiotics are very unlikely to alter this risk significantly. This includes patients with native valve and other structural heart lesions, and congenital heart disease. It is more important that these patients maintain good oral and skin hygiene to minimize the risk of bacteraemia.

The 2008 National Institute for Health and Clinical Excellence (NICE) guidelines¹ in the UK suggest that antibiotic prophylaxis against endocarditis is not recommended for any patient/situation, while the revised American Heart Association (AHA) guidelines² suggest that prophylaxis would be reasonable (but not mandatory) for patients at highest risk (see Table 9.4), but not for any others.

Thus, in general, prophylaxis is no longer recommended, but for the highest risk patients, it may be reasonable.

Table 9.4 ACC/AHA guidelines²

In general, antibiotic prophylaxis is no longer routinely recommended

High-risk patients for whom antibiotic prophylaxis may be reasonable practice

- Previous infective endocarditis
- Prosthetic heart valves (including bioprosthetic)
- Uncorrected cyanotic congenital heart disease (e.g. transposition of the great arteries, Fallot's tetralogy), including palliative shunts
- Repaired congenital heart disease with prosthetic material or device in the first 6 months' postimplantation
- Cardiac transplant-related valvulopathy

Procedures that may require antibiotic prophylaxis

Dental	Procedures that involve manipulation of the gingival tissue or perforation of the oral mucosa, (e.g. extraction)
Respiratory	Bronchoscopy, if incision of the respiratory tract mucosa is involved

Antibiotic prophylaxis for patients at high risk (if required)

All should be taken 1 hour preprocedure

Standard	Amoxicillin 3 g PO
Penicillin-allergic	Cephalexin 2g PO or clindamycin 600 mg PO or azithromycin 500 mg PO or clarithromycin 500 mg PO
Unable to take orally	Ampicillin 2g IM/IV Ceftriaxone 1g IM/IV
Penicillin-allergic and unable to take orally	Ceftriaxone 1g IM/IV Clindamycin 600mg IM/IV

^aPatients already on antibiotics should receive an alternative class from the lists above.

^bPatients having procedures involving infected tissues should have antibiotic prophylaxis directed at the infection, as this is the most likely source of any endocarditis.

References

1. NICE (2008). *Prophylaxis against infective endocarditis*, Clinical Guideline 64: London: NICE; www.nice.org.uk
2. Wilson W et al. Prevention of Infective Endocarditis. Guidelines From the American Heart Association: A Guideline From the American Heart Association Rheumatic Fever, Endocarditis, and Kawasaki Disease Committee, Council on Cardiovascular Disease in the Young, and the Council on Clinical Cardiology, Council on Cardiovascular Surgery and Anesthesia, and the Quality of Care and Outcomes Research Interdisciplinary Working Group. *Circulation* 2007; **116**: 1736–54; <http://circ.ahajournals.org/cgi/content/full/116/15/1736>

This page intentionally left blank

Arrhythmias

- Bradycardia: general 138
- Sinus bradycardia 140
- Sinus arrest 142
- Junctional bradycardia 144
- Atrioventricular block 146
- AV block with atrial fibrillation/flutter 150
- Tachycardia: general 152
- Pharmacological treatment of tachyarrhythmias 154
- Sinus tachycardia 158
- Atrial fibrillation 160
- Atrial flutter 166
- Atrial tachycardia 168
- Atrioventricular nodal re-entrant tachycardia 170
- Atrioventricular re-entrant tachycardia 172
- Ventricular pre-excitation and Wolff–Parkinson–White syndrome 174
- Ventricular fibrillation 176
- Ventricular tachycardia 178
- Monomorphic ventricular tachycardia 180
- Polymorphic ventricular tachycardia/‘torsade de pointes’ 182
- Electrical storms 184
- Implantable cardioverter defibrillators in the emergency room 186

Bradycardia: general

- Definition: a heart rate of <60 bpm.
- May occur as a normal physiological variant, 2° to a disease process, or as a result of drug therapy. Bradycardia is broadly divided into sinoatrial node dysfunction, or a block at the AV node or His–Purkinje system. It can be intermittent or persistent.

Types

See Table 10.1.

Presentation

- Coincidental finding in asymptomatic patient
- Breathlessness on exertion
- Fatigue
- Pre-syncope
- Syncope.

Immediate management

Depends on:

- Haemodynamic status—BP, level of consciousness, urine output, signs of heart failure
- Associated medical conditions—MI, drug overdose, hypothyroidism, hypothermia
- Type of bradycardia.

General principles

- Treat the patient rather than the ECG
- Identify and treat potentially causative factors—correct electrolytes, thyroid status, hypothermia, stop rate-slowing medications
- Patients with haemodynamic compromise should be considered for urgent treatment to improve heart rate
- Stable patients should have cardiac monitoring and subsequent definitive treatment depending on symptoms, type of bradycardia, and prognostic implications.

Treatment options

- Pharmacologic—atropine, salbutamol/isoprenaline infusion (Table 10.2)
- Temporary pacing—transcutaneous or transvenous (Box 10.1).

Table 10.1 Types of bradycardia

Sinus node dysfunction	AV block
Sinus bradycardia (📖 p.140)	AV block (📖 p.146)
Sinus arrest (📖 p.142)	AV block associated with atrial fibrillation/flutter (📖 p.150)
Junctional bradycardia (📖 p.144)	Bi-fascicular/tri-fascicular block (📖 p.396)

Table 10.2 Drugs used to treat bradycardia

Drug	Mechanism of action	Dose (IV)
Atropine	Anti-muscarinic	500 mcg to a maximum of 1 mg
Salbutamol	β -agonist	250 mcg bolus; 3–20 mcg/min infusion
Isoprenaline	β -agonist	5 mcg bolus; 1–20 mcg/min infusion

Box 10.1 Indications for temporary pacing

► NB Temporary pacing is often a bridge to permanent pacing. Ideally, a temporary pacing wire is only required if the patient cannot wait for a permanent system.

Definite

- Recurrent, frequent asystolic pauses causing syncope
- Any bradycardia with significant haemodynamic compromise
- 2nd-degree (Mobitz type II)/3rd-degree AV block (esp. broad complex escape rhythm and heart rate < 40 bpm) with severe haemodynamic consequences (stable patients do not require temporary pacing)
- Bradycardia-induced ventricular arrhythmia.

Can be considered

- Recurrent symptomatic pauses (>3 sec)
- Incessant VT (for overdrive pacing)
- Prophylactically in acute anterior MI patients with new bi-/tri-fascicular block or alternating RBBB/LBBB.

No clear indication

- Asymptomatic AV block
- Sinus node disease with no significant symptoms.

❓ Sinus bradycardia

Symptoms

- Often an asymptomatic coincidental finding, especially if nocturnal
- Fatigue
- Exertional dyspnoea
- Less commonly, pre-syncope or syncope.

Causes

- Physiological (fit, young patients at rest) in which case it is almost always asymptomatic
- Drug treatment, e.g. β -blockers, rate slowing calcium antagonist, amiodarone
- Systemic illness, e.g. hypothyroidism, hypothermia
- Sinus node disease.

ECG diagnosis

- Heart rate < 60 bpm (R-R interval > 5 big squares) (Fig. 10.1)
- P:QRS = 1:1.

Immediate management

- Assess haemodynamic status—BP, level of consciousness, urine output, signs of heart failure
- Identify causative factors—drug history, thyroid status, electrolytes
- If haemodynamically compromised: give atropine 1 mg IV bolus.

Prognosis and subsequent management

- Good prognosis
- Irreversible, symptomatic bradycardia may require permanent pacemaker insertion.

Specific considerations

- It is very rare to require temporary transvenous pacing for sinus bradycardia, although it may be required for severe haemodynamic compromise in bradycardia that cannot be treated pharmacologically
- β -blocker and rate slowing calcium-channel blocker overdose (📖 p.313).

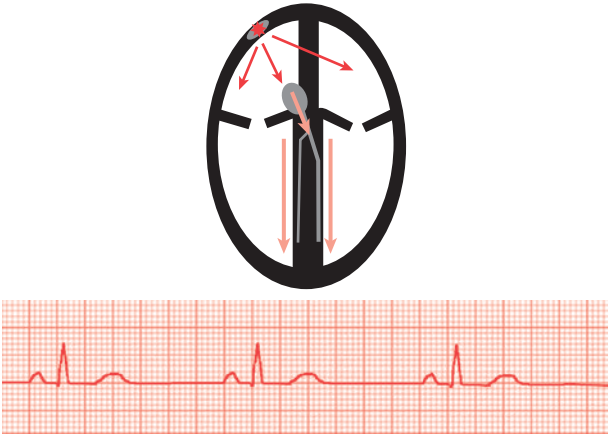


Fig. 10.1 Sinus bradycardia. The P wave and QRS have a constant relationship but the rate is slower than 60 bpm (R-R interval of >5 large squares). Red arrows indicate a compulsory part of the rhythm/circuit; pink arrows indicate bystander (non-participating) pathways.

⚠ Sinus arrest

Presentation

- Sinus arrest is often intermittent with an adequate rhythm and haemodynamic status in between episodes
- Asymptomatic, coincidental finding, especially if nocturnal (*sinus arrest is only 'significant' if pauses are > 3 sec*)
- Pre-syncope or syncope—check sinus pauses occur simultaneously/just before the symptoms, to be certain that these are the cause.

Causes

- Intrinsic sinus node disease
- Carotid sinus hypersensitivity or vasovagal reaction (📖 p.28).

ECG diagnosis

- A pause (significant if >3 sec), not preceded by ectopic beat (Fig. 10.2)
- P:QRS = 1:1

Immediate management

- Dictated by frequency and severity of pauses
- Usually no immediate management is required, even though a permanent pacemaker may be indicated in due course
- Stop potentially exacerbating medications— β -blockers, calcium-channel blockers
- Very frequent pauses resulting in severe symptoms may require temporary transvenous pacing (see 📖 Box 10.1, p.139).

Prognosis and subsequent management

- Good prognosis
- Symptomatic sinus arrest may require permanent pacemaker insertion.



Fig. 10.2 Sinus arrest. The P waves slow or stop suddenly, resulting in a pause. Significant pauses are those >3 sec, particularly when the patient is awake. Note that this pause is just under 3 sec, and is unlikely to result in symptoms, but longer pauses may occur at other times, especially if a precipitating factor (e.g. rate-slowing drug) is present.

② Junctional bradycardia

Junctional bradycardia occurs when the sinus node fails and a low atrial or AV junction pacemaker takes over. Symptoms result from bradycardia and loss of the atrial contribution to ventricular filling, particularly if atrial and ventricular contractions are simultaneous.

Presentation

- Asymptomatic coincidental finding, especially if nocturnal
- Fatigue
- Exertional dyspnoea
- Less commonly, pre-syncope or syncope.

Causes

- Drug treatment, e.g. β -blockers, calcium-channel blockers
- Systemic illness, e.g. hypothyroidism, hypothermia
- Hypokalaemia
- Sinus node disease with junctional escape.

ECG diagnosis

- Retrograde P waves may be visible just before/after QRS complex (Fig. 10.3)
- No P waves may be visible (buried within the QRS complex)
- Regular QRS complexes (usually narrow) with rate < 60 bpm
- P:QRS = 1:1 if P waves visible.

Immediate management

- Assess haemodynamic status (blood pressure, level of consciousness, urine output, signs of heart failure)
- Identify causative factors (drug history, thyroid status, electrolytes)
- If haemodynamically compromised: give atropine 1 mg IV.

Prognosis and subsequent management

- Good prognosis
- Irreversible, symptomatic bradycardia may require permanent pacemaker insertion.

Specific considerations

Temporary transvenous pacing for junctional bradycardia may be required for severe haemodynamic compromise. Single chamber ventricular pacing may not improve cardiac output and atrial or dual chamber AV sequential temporary pacing may be required – seek expert help!

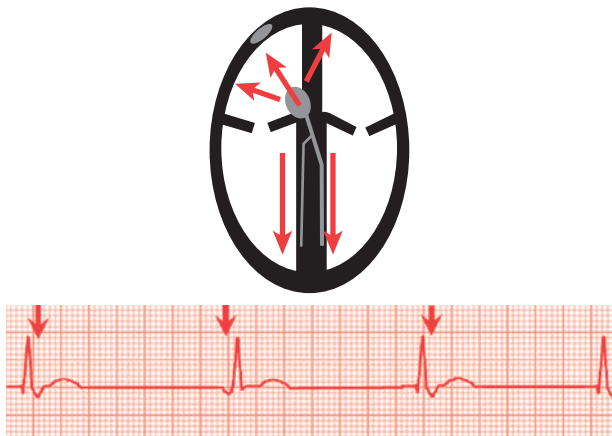




Fig. 10.3 Junctional bradycardia (see  ECG,  p.410). If the sinus node fails, the AV junction is the next in line in the pacemaker hierarchy. P waves originate from the AV node area and are therefore negative in leads II, III, and aVF. They occur just before, during, or after the QRS (arrows), depending upon which point in the AV junction they originate. There is a QRS complex, usually narrow, for every P wave.

② Atrioventricular block

Conduction delay or block between the atria and the ventricles may be within the AV node (usually narrow QRS complex, benign, and responds to increase in sympathetic tone) or the His–Purkinje system (QRS may be wide, worse prognosis, and doesn't respond to autonomic changes).

Classification

By ECG criteria into:

1st-degree AV block

- Slight delay of AV conduction, but each atrial stimulus is still conducted to the ventricles.

2nd-degree AV block (further divided into type I and type II)

- Increasing AV conduction block such that not all atrial stimuli are conducted to the ventricles.

3rd-degree AV block (also called complete heart block)

- No atrial stimuli are conducted to the ventricles. Ventricular activity is driven by myocardial tissue below the region of block.

Presentation

- Asymptomatic, coincidental finding
- Fatigue, exertional dyspnoea or low cardiac output state
- Pre-syncope or syncope.

Causes

- High vagal tone—usually benign and asymptomatic, often has a narrow complex escape rhythm
- 1° conduction tissue disease
- Myocardial disease (ischaemia, infarction, fibrosis, infiltration)—usually affects His–Purkinje system and has a wide complex escape rhythm
- Congenital
- Drugs, e.g. β -blocker and calcium-channel blocker combination.

ECG diagnosis

1st-degree AV block (Fig. 10.4)

- Prolonged PR interval (>200 msec or 5 small squares)
- 1:1 relationship between P and QRS
- QRS complex usually narrow.

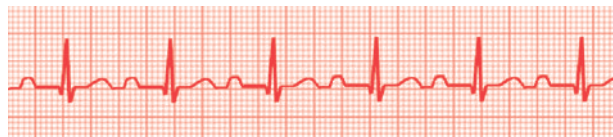

Fig. 10.4 1st-degree AV block.

2nd-degree AV block (Mobitz type I/Wenckebach phenomenon) (Fig. 10.5)

- Progressive lengthening of PR interval until a P wave is not conducted. PR interval then returns to normal for subsequent beat.
- Narrow QRS (usually)
- P:QRS is > 1:1.

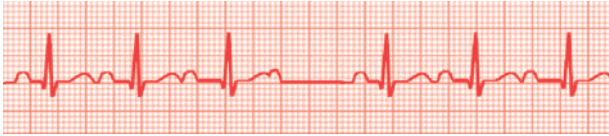

Fig. 10.5 2nd-degree AV block: Mobitz type I/Wenckebach phenomenon.

2nd-degree AV block (Mobitz type II) (Fig. 10.6)

- No variation in PR interval
- Intermittent failure in conduction to ventricles, with missing QRS complex(es) following P wave
- Narrow QRS (usually)
- Can be regular dropped QRS, e.g. 2 or 3 P waves for each QRS (termed 2:1 or 3:1 block etc.)
- P:QRS >1:1, and can be 2:1 or 3:1.

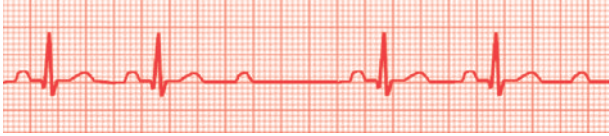

Fig. 10.6 2nd-degree AV block: Mobitz type II.

3rd-degree AV block (or complete heart block) (Fig. 10.7)

- Complete dissociation between P and QRS, i.e. no relationship
- P waves and QRS are usually regular but at different rates
- QRS complexes are often wide, but can be narrow if the AV block is high and the ventricular escape rhythm arises from the His–Purkinje system.

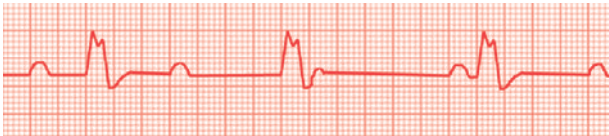

Fig. 10.7 3rd-degree AV block: complete heart block.

Management

- Stop any rate-slowing medications
- Treat any precipitating causes—acute MI, drug overdose, abnormal electrolytes.

1st-degree and Mobitz type I (Wenckebach) 2nd-degree block

- Do not normally require intervention.

Mobitz type II 2nd-degree block and complete AV block

- Atropine (1 mg IV) will improve AV node conduction in the setting of high vagal tone but will have little effect on conduction disturbances due to His–Purkinje disease. Effects may last up to 3 hours
- Consider temporary transvenous pacing, especially if the QRS complexes are broad and the heart rate is <40 bpm. Temporary pacing is required if there is a low cardiac output state with reduced perfusion or recurrent syncope
- Complete heart block with mild or infrequent symptoms may be observed until permanent pacing is performed, especially if the QRS complex is narrow.
- IV isoprenaline or other sympathomimetic drugs rarely improve conduction.

Prognosis and subsequent management

- Good prognosis if due to AV nodal block (narrow QRS, escape rhythm >45 bpm) and reversible cause
- Irreversible Mobitz type II 2nd-degree block or complete heart block due to His–Purkinje disease has an ↑mortality and usually requires permanent pacemaker insertion, whether symptomatic or not.

⚠ **Box 10.2 MI and AV block**

Inferior MI

In the setting of acute inferior MI, thrombolysis or 1° angioplasty should not be delayed by the management of AV block unless the patient is severely haemodynamically compromised. AV block is usually transient as the right coronary artery often supplies the AV node and reperfusion often results in restoration of normal conduction. If conduction returns to normal within 48 hours, permanent pacemaker insertion is not usually required. Temporary pacing is rarely required, and recovery of AV conduction can occasionally take >1 week.

Anterior MI

2nd/3rd-degree AV block in the setting of acute anterior MI carries a poor prognosis as the extensive infarction involving the anteroseptal wall results in damage to the conduction system. Hence, insertion of a temporary transvenous pacing wire should be considered.

► Temporary transvenous pacing in the setting of acute MI carries a risk of myocardial perforation (of the pacing wire through the infarcted tissue), but if pacing is indicated, the risk of not pacing is greater than that of perforation and so should be performed despite the ↑risks.

Box 10.3 AV block after cardiac surgery

Complete AV block is common after certain cardiac operations, e.g. aortic valve replacement. This may be due to damage to the AV conducting tissue during surgery or may be reversible due to oedema. It is usual to perform temporary pacing and observe for up to 7 days. Most patients would already have epicardial pacing leads *in situ* to facilitate this if required, and transvenous pacing is needed only if the epicardial leads fail. Persistent AV block after a week usually indicates the need for permanent pacemaker.

② AV block and atrial fibrillation/flutter

High grade AV block with atrial fibrillation/flutter may result in symptoms due to a slow ventricular response, either persistent bradycardia or symptomatic pauses. Pauses (R-R intervals) of <3 sec are not significant (particularly at night)

Causes

- Intrinsic conduction tissue disease
- Coexisting cardiac disease—*ischaemia*, infarction, fibrosis, infiltration
- Drugs—particularly β -blocker and calcium-channel blocker combination.

ECG diagnosis

AF and complete AV block

- No clear P waves
- Often coarse, fibrillatory baseline—F waves
- Regular ventricular escape rhythm—QRS can be narrow or broad
- Differential diagnosis: junctional bradycardia.

Atrial flutter with high grade AV block

- Saw-tooth baseline (flutter waves) especially in the inferior leads
- Flutter wave: QRS usually >4:1.

Immediate management

- Treat any precipitating causes—acute MI, drug overdose, abnormal electrolytes
- Stop any rate-slowing medications
- Atropine (1 mg IV) will improve AV node conduction in the setting of high vagal tone but will have little effect on conduction disturbances due to His–Purkinje disease
- Temporary pacing is required only if there is a low cardiac output state with reduced perfusion or recurrent syncope
- Slow ventricular rates with mild or infrequent symptoms may be observed until permanent pacing is performed.

Prognosis and subsequent management

- Discontinue exacerbating antiarrhythmic medications
- Irreversible high-grade AV block due to His–Purkinje disease has an \uparrow mortality and usually requires permanent pacemaker insertion, whether symptomatic or not.

This page intentionally left blank

Tachycardia: general

- Definition: a heart rate of >100 bpm.
- Tachycardia may be broadly divided into appropriate (normal physiological response to certain conditions) or inappropriate (an arrhythmic process). The origin of the tachycardia may be from re-entrant circuits or foci in the atria (supraventricular) or ventricles. Symptoms are generally due to impaired cardiac perfusion and reduced cardiac output.

To aid with diagnosis and management, a tachycardia is usually subdivided into (Table 10.3):

- Narrow complex—regular, QRS duration <120 ms
- Broad complex—regular, QRS complex >120 ms
- AF with rapid ventricular response—irregular rhythm, may be narrow or broad complex.

Presentation

- May be asymptomatic
- Breathlessness
- Chest pain
- Palpitations
- Pre-syncope
- Syncope.

Immediate management

Depends on:

- Haemodynamic status—BP, level of consciousness, urine output, signs of heart failure
- Symptoms of cardiac ischaemia—chest pain, SOB
- Associated medical conditions—MI, drug overdose, hyperthyroidism, PE
- Type of tachycardia.

General principles

- Treat the patient rather than the ECG
- Treat potentially exacerbating factors—correct electrolytes, hypoxia, acid–base disturbances, dehydration, thyroid status
- Identify and treat underlying cause—MI, PE
- Stable patients should have cardiac monitoring and treatment to control heart rate or restore sinus rhythm.

► Patients with haemodynamic compromise/significant symptoms due to the arrhythmia should be considered for urgent treatment to restore normal sinus rhythm.

Treatment options

- Vagal manoeuvres—carotid sinus massage, Valsalva
- Adenosine (📖 p.156)
- Antiarrhythmic drugs (📖 p.154)
- Synchronized DC cardioversion or defibrillation
- Overdrive pacing via transvenous temporary wire (📖 p.185).

Table 10.3 Types of tachycardia

	Narrow complex tachycardia	Broad complex tachycardia
Regular	Sinus tachycardia Atrial tachycardia AVNRT AVRT Atrial flutter (regular block)	VT Any regular NCT with bundle branch block
Irregular	AF Atrial flutter (variable AV block)	Pre-excited AF Polymorphic VT Ventricular fibrillation Any irregular narrow complex tachycardia with bundle branch block

Pharmacological treatment of tachyarrhythmias

Drugs are used in the treatment of tachyarrhythmia for 3 main reasons:

- To aid diagnosis, e.g. adenosine
- To restore normal rhythm, i.e. antiarrhythmic drugs, adenosine (Box 10.4)
- To reduce heart rate, e.g. certain antiarrhythmic drugs acting on the AV node.

Antiarrhythmic drugs

These drugs are classified according to their mechanism of action in the Vaughan–Williams classification (Table 10.4). They work by blocking certain ion channels or receptors in the heart to restore and/or maintain normal sinus rhythm.

General tips for choosing antiarrhythmic drugs

Ischaemia and heart failure

- Class I agents (flecainide and propafenone) are mostly contraindicated in patients with ischaemic or structural heart disease
- Caution with using calcium-channel blocker or β -blocker in acute decompensated heart failure
- Amiodarone and digoxin are generally safe in ischaemic or structural heart disease.

Combinations

- The combination of β -blocker and calcium-channel blocker (especially when used intravenously) may result in bradycardia or even AV block
- Amiodarone potentiates the effects of digoxin and vice versa
- Digoxin has a slow onset of action and is less effective in hyperadrenergic states, e.g. postoperation, sepsis, exertion, thyrotoxicosis.

► Remember—most antiarrhythmic drugs can have pro-arrhythmic effects.

► With the exception of digoxin, most antiarrhythmic drugs can cause \downarrow BP.

Commonly used antiarrhythmic drugs are listed in Table 10.5.

Box 10.4 Administration of IV amiodarone

The IV bolus and infusion of amiodarone should be administered through a central venous catheter whenever possible. If it has to be given peripherally then ensure that amiodarone is given through a newly sited, large-bore cannula in a large peripheral vein (e.g. in the antecubital fossa) as extravasation of amiodarone may result in severe tissue damage. Thrombophlebitis is a recognized complication of peripheral amiodarone.

Table 10.4 Vaughan–Williams classification of antiarrhythmic drugs

	Mechanism of action	Examples
Class I	Sodium-channel blocker	Lignocaine Flecainide Propafenone
Class II	β -blocker	Bisoprolol Atenolol Sotalol
Class III	Potassium-channel blocker	Amiodarone Sotalol
Class IV	Calcium-channel blocker	Verapamil Diltiazem

Table 10.5 Commonly used antiarrhythmic drugs

Drug name	Dose
Amiodarone	Cardiac arrest dose 300 mg as IV bolus Slow IV bolus 150 mg over 10 min (in 100–250 mL 5% dextrose). IV infusion to total 1.2 g in 500 mL 5% dextrose over 24 hours through central line Oral 200–400 mg TDS for 5–7 days then 200 mg maintenance
Digoxin	IV loading 0.75–1 mg over 2 hours in 5% dextrose or 0.9% saline Oral loading 0.75–1.5 mg over 24 hours, split into 2–3 doses given 8-hourly Oral maintenance 62.5–250 mcg daily
Esmolol	Urgent IV bolus 1 mg/kg over 30 sec IV infusion 10 mg/mL in 5% dextrose or 0.9% saline. Load with 0.5 mg/kg/min for 1 min only. Maintenance with 0.05–0.3 mg/kg/min, starting at 0.05 mg/kg/min
Flecainide	IV 2 mg/kg to a maximum of 150 mg over 15 min Oral 50–150 mg twice daily
Lidocaine	IV bolus 50–100 mg over 1–2 min Infusion 4 mg/min for 30 min, 2 mg/min for 2 hours, then 1 mg/min
Magnesium sulphate	IV bolus 8 mmol (2g) over 10–15 min in 100 mL 5% dextrose Infusion 2–4 mmol (0.5–1 g)/hour. Concentration should not exceed 20%
Procainamide	IV loading 20 mg/min infusion up to a maximum total dose of 17 mg/kg. Maintenance infusion 20–80 mcg/kg/min
Verapamil	IV 5–10 mg over 2–3 min. Additional 5 mg after 5 min if necessary Oral 40–120 mg TDS

The role of adenosine

Adenosine is a very short-acting IV drug that specifically blocks the specialized conducting tissue of the AV node, with lesser effects on the sinus node and atrial myocardium. It can be very useful in the treatment and diagnosis of tachyarrhythmia (see Table 10.6).

Termination of arrhythmias

- The principal effect is to cause transient AV nodal block. Any tachycardia dependent on AV node conduction will therefore terminate when AV node block occurs. (On rare occasions, the arrhythmia may reinitiate after a few beats of sinus rhythm, in which case a second dose of adenosine is often helpful)
- Tachycardias that are not dependent on AV node conduction for their maintenance (AF, flutter) will continue, although the ECG appearance may transiently change, aiding diagnosis
- Rarer ectopic atrial tachycardias and idiopathic VTs may, however, be terminated with adenosine.

Other effects

- High doses of adenosine may induce AF in 5–10% of patients
- Adenosine administration often results in ventricular ectopy but it is rare for it to provoke sustained VT
- To reverse the effects of adenosine, give IV aminophylline.

Indications during tachycardia

Narrow complex regular tachycardia

- May terminate if AVNRT/AVRT. May reveal flutter waves if atrial flutter, or P waves if atrial tachycardia

Broad complex tachycardia

- When the patient is haemodynamically stable *and*
- No definite ECG/clinical characteristics to suggest VT *and*
- There is a likelihood of SVT with bundle branch block.

Administration

- ▶ Always record a continuous ECG immediately before, during, and after adenosine administration.
- Administer as a rapid IV bolus through a large cannula placed as centrally as possible
- Follow immediately by at least 10 mL flush of saline
- Ideally, connect the adenosine and flush syringes to the cannula through a 3-way tap to facilitate administration
- Start with a 6 mg bolus, and if no effect, increase to 12 mg, and in large patients, consider 18 mg or higher. Wait a few minutes between doses
- Patients will experience transient chest tightness, sweating and flushing during administration. Warn them!

Contraindications

- Severe asthma—adenosine is reported to be safe in mild asthmatics
- Dipyridamole use—inhibits adenosine uptake and potentiates its effect
- Caution with severe sinus node disease and cardiac transplant recipients.

Table 10.6 Effects of adenosine of different arrhythmias

Arrhythmia	Effect of adenosine
Sinus tachycardia	Transient slowing of sinus rate. Transient AV block with ongoing P waves. As adenosine wears off sinus tachycardia rate may increase
Atrial tachycardia	60% will show transient AV block with ongoing P waves. In some cases the atrial rate may also transiently slow. 10% of automatic atrial tachycardias are adenosine sensitive and will terminate. No effect in the remainder
Atrial fibrillation	Transient AV block. Fibrillatory baseline still visible up until AV conduction returns
Atrial flutter	Transient AV block. Flutter waves become clearly visible up until AV conduction returns
AVNRT	Tachycardia terminates and sinus rhythm returns
AVRT	Tachycardia terminates and sinus rhythm returns
AF and pre-excitation through accessory pathway	⚠ QRS complexes transiently widen and ventricular rate may increase further, possibly resulting in ventricular fibrillation
VT	Usually no effect, however some idiopathic VTs in normal hearts may terminate

❓ Sinus tachycardia

- Sinus tachycardia is a physiological response, usually to physical, emotional, or physiological stress
- Heart rate is typically 100–160 bpm usually with subtle variation in rate
- There is almost always an identifiable underlying cause
- Inappropriate sinus tachycardia is a rare condition marked by dramatic increases in heart rate with minimal exertion and a mean resting rate >100 bpm
- Sinus node re-entrant tachycardia is also rare and may mimic sinus tachycardia but often has a sudden onset and termination and responds to IV adenosine.

Common causes

- Pain
- Anxiety
- Dehydration
- Sepsis
- Shock
- Hypoxia
- PE
- Heart failure
- Anaemia
- Thyrotoxicosis
- Stimulants—caffeine, amphetamines, inotrope infusions.

ECG diagnosis

- P waves are the same morphology as those in sinus rhythm—these may be hard to identify at a fast rate (Fig. 10.8)
- PR interval is usually normal
- P:QRS = 1:1.

Treatment

Identify and treat the underlying cause—the tachycardia is 2° to this and is not itself a problem.

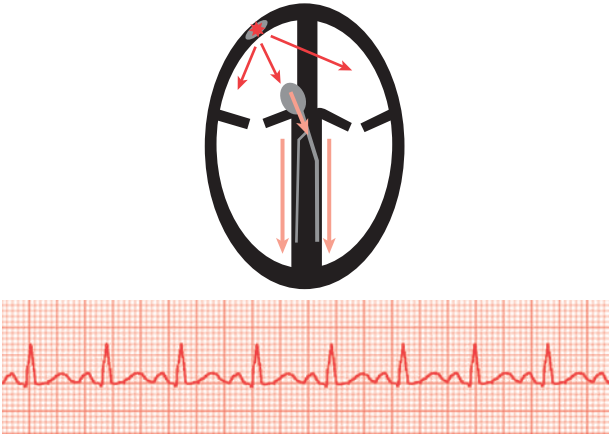


Fig. 10.8 Sinus tachycardia. The P wave is a normal shape and axis and precedes each QRS with a normal PR interval. There are often subtle variations in the heart rate. Red arrows indicate a compulsory part of the rhythm/circuit; pink arrows indicate bystander (non-participating) pathways.

Atrial fibrillation

- The commonest clinical arrhythmia, affecting 1% of the population
- Characterized by very rapid and disorganized atrial activity, usually resulting in a fast and irregularly irregular ventricular rate
- AF may be *paroxysmal* (will spontaneously revert to sinus rhythm); *persistent* (requires pharmacologic or electrical cardioversion to restore sinus rhythm); or *permanent* (no plan to restore sinus rhythm).


Main causes

Hypertension, valvular heart disease, cardiomyopathy (ischaemic, dilated or hypertrophic), acute infection, thyrotoxicosis, post-surgery, 'lone' AF.

Presentation

- A wide spectrum. Patients may be asymptomatic, have palpitation, chest pain, dyspnoea, pre-syncope, syncope, or frank pulmonary oedema
- Symptoms result from a rapid, irregular ventricular rate and loss of atrial contribution to ventricular filling (and thus cardiac output).

ECG diagnosis


- Irregularly irregular ventricular rhythm (Fig. 10.9)
- No discrete atrial activity (although lead V1 often has a coarse, rapid fibrillatory baseline). See  ECG, p.414

Treatment: general principles

- Assess patient's haemodynamic status and symptoms
- Treat potentially exacerbating factors—correct electrolytes, hypoxia, acid–base disturbances, dehydration, thyroid status
- Identify and treat any underlying cause—acute MI, PE
- Postsurgical patients are often dehydrated, hypoxic, in pain, or any combination of these, and mostly respond to treatment of the underlying factors. They still require heparin to reduce thrombus formation \pm rate control if heart rate >100 bpm, but rarely require cardioversion.

The principal aspects of treatment are:

- Restoration of sinus rhythm vs. ventricular rate control
- An assessment of thromboembolic risk.

► Specific treatment is highly dependant on the status of the patient (see  Treatment: specific conditions, p.162).

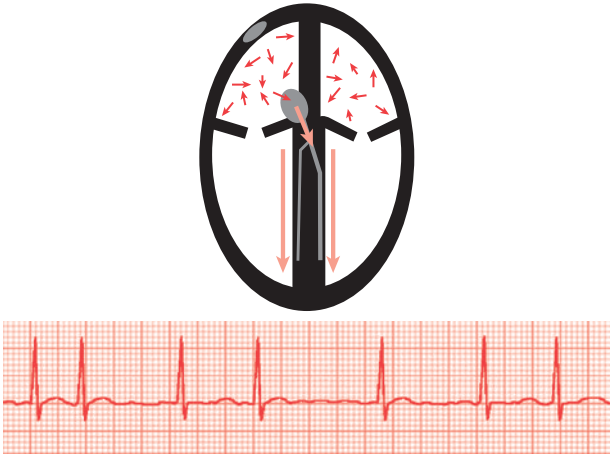


Fig. 10.9 AF. Irregular QRS complexes. No obvious discrete P wave activity, although it is not unusual to see more organized activity in lead V1 with sharp bumps every 4–6 small squares. Red arrows indicate a compulsory part of the rhythm/circuit; pink arrows indicate bystander (non-participating) pathways.

Treatment: specific conditions (Fig. 10.10)**⊕ AF with severe haemodynamic compromise**

(Hypotension and hypoperfusion, reduced conscious level, pulmonary oedema, cardiac ischaemia.)

Regardless of duration of onset

- Oxygen
- Heparin IV (5000–10,000 IU)
- Synchronized DC shock under sedation/general anaesthesia using 200–360J monophasic or 150–200J biphasic energy.

Ⓢ Symptomatic AF with mild–moderate compromise

(Breathlessness, palpitation and/or mild hypotension.)

Onset <48 hours

- Heparin IV (5000–10,000 IU) then SC LMWH
- Consider pharmacological cardioversion:
 - Flecainide if no known structural heart disease and patient <50 years
 - Amiodarone is the safer option in patients with heart disease but takes longer to work and needs to be given IV via a central line.
- Alternatively, consider synchronized DC cardioversion under sedation/GA
- If immediate electrical cardioversion is not available, start treatment with amiodarone while waiting.

Onset >48 hours

- SC LMWH and consider anticoagulation
- Rate control with 1 or more of the following:
 - β -blocker and calcium-channel blockers are usually most effective, but are relatively contraindicated if there is acute heart failure
 - Digoxin is most helpful for resting tachycardia in the elderly but is slow to work, ineffective in high adrenergic states (e.g. postoperation, sepsis, thyrotoxicosis), and its effect may be lost once the patient becomes active and mobile
 - Amiodarone may be used but takes 12–24 hours to control ventricular rate when given IV, followed by high-dose oral loading (400mg TDS for 1 week). Amiodarone may result in cardioversion so should be avoided in inadequately anticoagulated patients
- If still symptomatic and cardioversion is necessary, then TOE to exclude left atrial appendage thrombus followed by DC cardioversion, otherwise, outpatient cardioversion following a period of anticoagulation.

Ⓢ Minimally symptomatic AF with no compromise

Onset <48 hours

- Heparin (5000–10,000 IU IV) then SC LMWH
- 2 options:
 - 'Watch and wait' as spontaneous cardioversion often happens
 - Cardioversion: pharmacological or electrical.

Onset >48 hours

- Anticoagulation and rate control (if required) initially
- Consider elective DC cardioversion once anticoagulated
- In some cases, the decision may be made to accept AF as permanent.

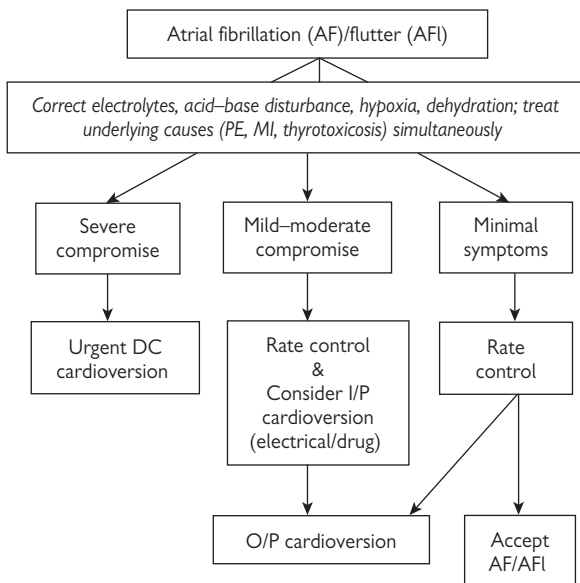


Fig. 10.10 Flowchart summarizing general treatment strategies for acute atrial fibrillation/flutter. DC, direct current; I/P, inpatient; O/P, outpatient.

🚑 Box 10.5 Pre-excited AF

Pre-excited AF (📖 p.415) occurs in patients with an accessory pathway (📖 p.174) and can result in a very rapid, irregular, broad complex tachycardia producing severe symptoms. Sinus rhythm should be restored as soon as possible, usually with urgent DC cardioversion. If not possible, IV flecainide 2 mg/kg (max. 150 mg) over 10–15 min slows conduction through the accessory pathway. Avoid drugs that block AV node conduction and increase accessory pathway conduction (e.g. digoxin, verapamil and adenosine).

⚠️ Box 10.6 Rapid control of ventricular rate in the Emergency Room or ICU

May be achieved with a continuous infusion of the IV β -blocker esmolol. This has the advantage of being short acting and can be titrated up and down depending upon heart rate and BP response.

Subsequent management

- Echocardiography to look for underlying heart disease
- If previous episodes of compromising AF, a future antiarrhythmic strategy may be appropriate (antiarrhythmic drugs or catheter ablation) to prevent recurrence
- Consider long-term anticoagulation
- If AF is accepted as permanent, consider rate control if heart rate >100bpm in addition to anticoagulation decision.

Thromboembolic risk

The thromboembolic risk that results from the development of AF and following the restoration of sinus rhythm needs to be considered when assessing the various treatment strategies. Left atrial thrombus results from loss of atrial contractility and ↑stasis and pooling of blood in the left atrial appendage. Restoration of sinus rhythm restores atrial contractile function and may result in embolism of any thrombus present. This risk should be considered the same whether electrical or pharmacological cardioversion has occurred.

AF onset <48 hours:

- Safe to cardiovert patient without any anticoagulation
- Usual to give IV or LMWH as it allows more time to assess patient and make therapeutic decisions.

AF onset >48 hours or uncertain:

- If there is a need to perform urgent cardioversion, it is safer after a TOE has excluded a left atrial appendage thrombus
- Otherwise, a 4-week period of anticoagulation with INR >2 is necessary before scheduling outpatient cardioversion
- In this group of patients, anticoagulation is also usually needed for at least 3 months after cardioversion.

Long-term anticoagulation

This depends on the risk of AF recurrence and an estimate of thromboembolic risk (the CHADS₂ score—see Box 10.7 and Table 10.7):

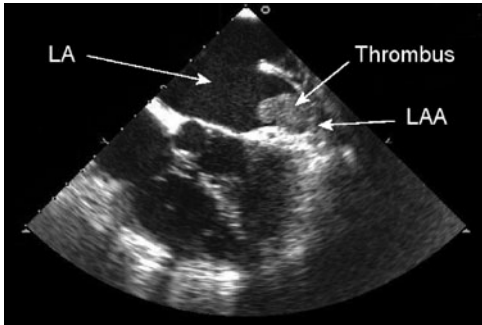


Fig. 10.11 TOE of the left atrium (LA) demonstrating a thrombus in the left atrial appendage (LAA). It is believed that >90% of strokes in AF result from emboli originating in the LAA.

Box 10.7 Assessing thromboembolic risk: the CHADS₂ score

The CHADS₂ score is a quick and simple scoring system for assessing a patient’s stroke risk. Points are scored according to risk profile to a maximum of 6:

- **C**ongestive heart failure 1
- **H**ypertension 1
- **A**ge >75 years 1
- **D**iabetes mellitus 1
- Prior **S**troke/TIA/embolism 2

The risk of stroke per year for each score is:


- 0: 1.9%
- 1: 2.8%
- 2: 4.0%
- 3: 5.9%
- 4: 8.5%
- 5: 12.5%
- 6: 18.2%.

Table 10.7 CHADS₂ score, thromboembolic risk, and treatment

Score	Risk	Treatment
0	Low	Suitable for aspirin 75mg OD
1 or 2	Intermediate	Either aspirin or warfarin (INR 2–3) can be considered
>2	High	Warfarin is recommended (INR 2–3)

Atrial flutter

Atrial flutter is a re-entrant atrial tachycardia (in the right atrium) with an electrical wavefront that rotates around the tricuspid valve, although other, less common circuits may present as atypical flutters.

- The atrial rate is usually a regular 280–320 bpm, with the ventricles activated in a 2:1 fashion due to filtering via the AV node
- Higher degrees of AV block may occur spontaneously or with the addition of drug therapy
- Rarely, 1:1 conduction may occur, leading to extremely rapid ventricular rates and severe symptoms
- Like AF, atrial flutter may be paroxysmal, persistent, or permanent
- As with AF, the thromboembolic risk needs to be considered when considering the various treatment strategies (see  p.164).


Presentation

Patients may: be asymptomatic; have palpitations, chest pain, or dyspnoea; pre-syncope, syncope, or frank pulmonary oedema.


Principle causes

Idiopathic, hypertension, mitral valve disease, cardiomyopathy (ischaemic, dilated, or hypertrophic), acute infection, postoperative.

ECG diagnosis

- Typical atrial flutter has a ‘saw-tooth’ baseline with flutter waves at 300 bpm with mainly negative deflections in leads II, III, and aVF (Fig. 10.12)
- When there is 2:1 conduction to the ventricle, flutter waves may be hard to see as alternate flutter waves are hidden in the QRS complex
- Ventricular rate is usually regular at approximately 150 bpm (see  ECG, p.416).

Treatment

- Essentially as for AF (but see Box 10.8)
- Two strategies are available—restoration of sinus rhythm, or ventricular rate control. Some pharmacological treatments may address both
- The treatment strategy should be based on duration of onset, haemodynamic compromise, and thromboembolic risk as for the management of AF ( p.162, 164).

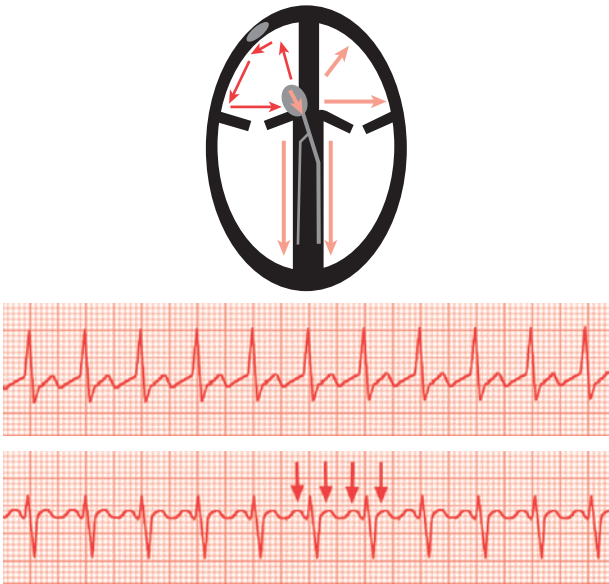


Fig. 10.12 Atrial flutter. Regular QRS complexes, typically at 150 bpm. Rapid, regular atrial activity usually between 280–320 bpm (1 flutter wave every large square). During 2:1 AV conduction alternate flutter waves may be hidden in QRS complexes. Lead V1 is often a good lead for spotting atrial activity (arrows). In typical flutter the flutter waves are negative in leads II, III, and aVF (saw-tooth pattern). Red arrows indicate a compulsory part of the rhythm/circuit; pink arrows indicate bystander (non-participating) pathways.

Box 10.8 Special considerations for atrial flutter

► Flecainide should not be given to patients in atrial flutter without additional AV nodal blocking drugs (e.g. β -blockers). Flecainide and other Class 1c drugs may slow the flutter rate within the atrium, allowing 1:1 conduction through the AV node and a paradoxical increase in ventricular rate with worsening of symptoms.

- Atrial flutter is easier to cardiovert electrically but does not cardiovert easily with drugs
- Rate control with digoxin is less effective than with β -blockers
- Recurrent atrial flutter can be treated with radiofrequency ablation of the cavotricuspid isthmus.


Atrial tachycardia

- Sometimes called ectopic or focal atrial tachycardia and results from a discrete focus firing automatically at a rate greater than the sinus node
- Common sources of tachycardia are the pulmonary veins in the left atrium, the crista terminalis in the right atrium.
- The ventricle is often activated in a 1:1 fashion unless the atrial rate is particularly fast (>200 bpm) or AV nodal blocking drugs are being used
- Symptoms result from the rapid ventricular rate and usually manifest as palpitation, dyspnoea, pre-syncope, or chest pain.

Principle causes

Often occurs in the setting of an acute illness or trauma (sepsis, surgery, injury). In children and young adults, the heart is often structurally normal. In older patients it is most likely to be associated with structural heart disease


ECG diagnosis

- Discrete P waves, often a different shape to P waves in sinus rhythm (Fig. 10.13)
- Often has a normal PR interval (often categorized as a 'long RP tachycardia' when P to R wave shorter than R wave to next P wave)
- P:QRS is usually 1:1, but can be 2:1 or more (see  ECG, p.417).

Treatment

Treatment should address any underlying cause (e.g. infection, trauma) and optimizing electrolytes, fluid balance, hypoxia, acid–base balance

Severe haemodynamic compromise

- Restore sinus rhythm with synchronized DC 200–360J shock under sedation/GA
- However, if the underlying cause is still present, there is a high chance of recurrence. Hence, antiarrhythmic treatment is usually necessary:
 - Amiodarone—oral or IV
 - β -blockers, e.g. esmolol infusion ( p.196), especially in ITU.

Mild to moderate haemodynamic compromise

- Attempt to cardiovert pharmacologically:
 - In general, amiodarone and β -blockers are safest
 - Flecainide may be considered if there is no known structural/ischaemic heart disease
- However, due to ongoing underlying cause (e.g. sepsis), acute cardioversion may not be successful and concurrent treatment to control rate is important:
 - β -blockers and calcium-channel blockers (if no hypotension or decompensated heart failure)
 - Digoxin is safe in LV dysfunction and can be added for better rate control
- If the atrial rate is >200 bpm, atrial contraction can be impaired and thromboembolic risk is \uparrow (i.e. like atrial flutter). If duration >24–48 hours, consider anticoagulation with LMWH.

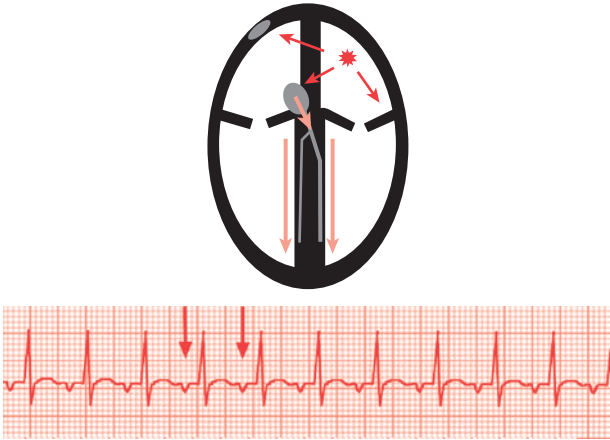


Fig. 10.13 Atrial tachycardia. A focal, automatic tachycardia producing a discrete P wave, although the shape is usually different from the P wave shape seen during sinus rhythm. Usually 1:1 AV conduction unless a very rapid atrial rate or drugs have been given. May have subtle variations in heart rate. Red arrows indicate a compulsory part of the rhythm/circuit; pink arrows indicate bystander (non-participating) pathways.

ⓘ Atrioventricular nodal re-entrant tachycardia

- The commonest form of re-entrant tachycardia in adults
- The AV node is a critical component of the re-entrant circuit which comprises the 'fast' and 'slow' pathways within the AV node
- It may present at any age and be sustained or non-sustained
- Heart rates are typically between 150–250 bpm
- In the typical form, the atria and ventricles are depolarized (and therefore contract) simultaneously
- Atrial contraction against closed AV valves can result in rapid, visible pulsation of the neck veins
- AVNRT is most often seen in a structurally normal heart.


Presentation

Usual symptoms are rapid palpitations with sudden onset and termination, dyspnoea, chest tightness, and pre-syncope.


Principle causes

Attacks may be precipitated by exertion and physical or emotional stress, but are often spontaneous with no obvious cause.

ECG diagnosis

- Usually regular narrow complex tachycardia (may be broad complex if there is bundle branch block (RBBB/LBBB) or rate-related aberrancy)
- P waves are usually hidden in the QRS and are not visible (Fig. 10.14)
- Sometimes, P wave may appear as a 'pseudo-R' wave at the end of each QRS complex (esp. lead V1). See  ECG, p.418.

Treatment

- Tachycardia stops if the re-entrant circuit is interrupted, i.e. AV nodal block:
 - Vagal manoeuvres—carotid sinus massage, Valsalva manoeuvre, ocular pressure, ice application
 - Adenosine IV bolus (see  p.156 for dose and administration)
- If 12 or 18 mg adenosine has no effect after being given appropriately, reconsider the diagnosis
- If tachycardia reinitiates immediately after terminating transiently with above treatment, consider IV verapamil/esmolol (caution in hypotension or LV dysfunction) followed by oral verapamil/ β -blockers
- Other possible antiarrhythmic drugs:
 - Flecainide, sotalol (consult cardiologist)
- Rarely, DC cardioversion if pharmacological treatment fails or if there is severe haemodynamic compromise.

Subsequent management

- First episodes do not usually require prophylactic drug therapy
- Referral for radiofrequency ablation if frequent symptomatic episodes as procedure is low risk and has high success rates (>90%).

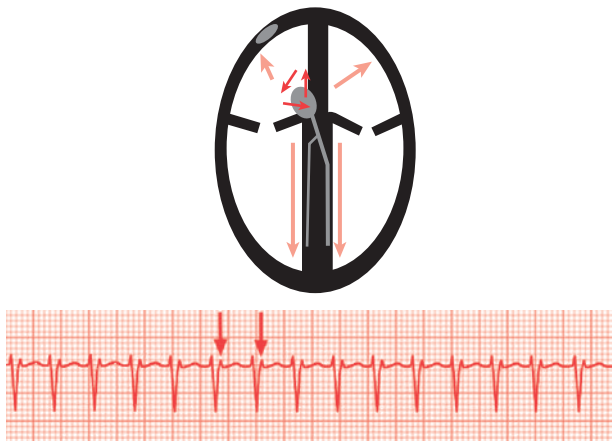


Fig. 10.14 AVNRT. A rapid, regular tachycardia. Usually narrow complex (unless bundle branch aberrancy occurs). Retrograde P wave occur during the QRS complex and are difficult to see, although typically appear as a 'pseudo-R wave' in lead V1 (arrows). Red arrows indicate a compulsory part of the rhythm/circuit; pink arrows indicate bystander (non-participating) pathways.

ⓘ Atrioventricular re-entrant tachycardia

- AVRT is the result of an accessory pathway that connects the atria to the ventricles across the tricuspid or mitral valve annuli
- The AV node is also a critical component of the re-entrant circuit which comprises the AV node, the accessory pathway, and the adjoining atria and ventricular tissue
- Approximately 1/3 of accessory pathways are able to conduct antegradely from the atrium to the ventricles during sinus rhythm, producing ventricular pre-excitation (see Wolff–Parkinson–White syndrome 📖 p.174)
- The remaining 2/3 can only conduct retrogradely from ventricles to atria (concealed accessory pathways)
- The usual form of tachycardia is antegrade conduction from atria to ventricles through the AV node and bundle branches (with normal ventricular depolarization) and retrograde conduction from the ventricles to the atria through the accessory pathway (orthodromic reciprocating tachycardia, Fig. 10.15)
- Antidromic reciprocating tachycardia (Fig. 10.16) is much less common and results from antegrade conduction from the atria to the ventricles through the accessory pathway and retrograde conduction up through the AV node. Antidromic tachycardia can therefore only occur in those patients with ventricular pre-excitation
- AVRT is usually seen in structurally normal hearts, although there is an association with Ebstein's anomaly and hypertrophic cardiomyopathy.

Presentation

Usual symptoms are rapid palpitations with sudden onset and termination, dyspnoea, chest tightness, and pre-syncope or, rarely, syncope.

Principle causes and symptoms

Attacks may be precipitated by exertion and physical or emotional stress, but are often spontaneous with no obvious cause.

ECG diagnosis

- Usually regular narrow complex tachycardia (may be broad complex if there is bundle branch block (RBBB/LBBB) or rate-related aberrancy)
- Retrograde P waves are often visible in the ST segment (sometimes categorized as a 'long RP tachycardia' when P to R wave shorter than R wave to next P wave). See Figs. 10.15 and 10.16; also 📖 ECG, p.419.

Treatment

As for AVNRT (see 📖 p.170).

Subsequent management

- As for AVNRT (see 📖 p.170)
- In patients with ventricular pre-excitation see 📖 p.174.

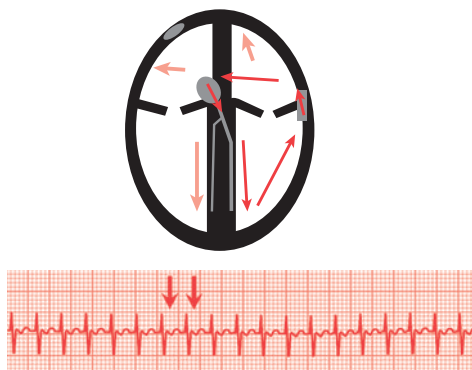


Fig. 10.15 Orthodromic tachycardia. A rapid, regular rhythm. The circuit goes from atrium to ventricle through the AV node and bundle branches so any delta wave disappears and the QRS is narrow (unless there is bundle branch block aberrancy); then from ventricle to atrium through the accessory pathway. The retrograde P wave occurs after the QRS (arrows). Red arrows indicate a compulsory part of the rhythm/circuit; pink arrows indicate bystander (non-participating) pathways.

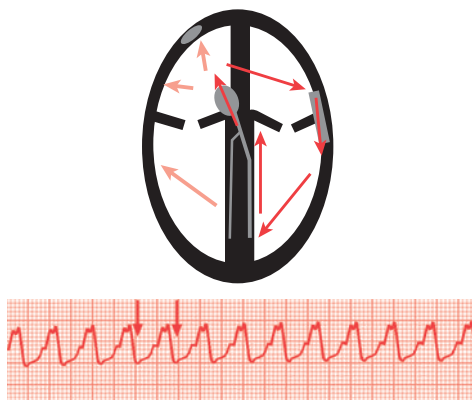


Fig. 10.16 Antidromic tachycardia. Much less common. A rapid, regular rhythm. The circuit goes from atrium to ventricle through the accessory pathway so the ventricle is totally pre-excited and the QRS is very wide; then from ventricle to atrium through the bundle branches and AV node. The retrograde P wave occurs at the end of the QRS (arrows). Red arrows indicate a compulsory part of the rhythm/circuit; pink arrows indicate bystander (non-participating) pathways.

❓ Ventricular pre-excitation and Wolff–Parkinson–White syndrome

- Ventricular pre-excitation occurs when there is an accessory pathway capable of antegrade conduction. A portion of the ventricle becomes activated before AV conduction, which creates the delta wave. This fuses with the normal activation through the AV node, forming the resultant QRS complex (see fig 10.17 & p.420)
- The accessory pathway may form part of a re-entrant circuit, resulting in AVRT (📖 p.172)
- WPW syndrome refers to patients with:
 - Ventricular pre-excitation due to an accessory pathway
 - Palpitation 2° to SVT (AVRT)
- The accessory pathway capable of antegrade conduction may also result in atrial activity during atrial tachyarrhythmias being conducted rapidly to the ventricles (e.g. pre-excited AF, see 📖 p.415).

Presentation

- Asymptomatic ventricular pre-excitation
- Symptoms due to AVRT (📖 p.172)
- May be pre-syncope/syncope/sudden death with fast pre-excited AF.

ECG diagnosis

Ventricular pre-excitation

- Short PR interval (<5 small squares 0.2 sec)
- Delta wave (slurred onset of QRS) resulting in broader QRS complexes.

Prognosis and subsequent management

- Patients with WPW syndrome have an ↑risk of AF, which can lead to VF.
- The risk of sudden death in patients with WPW is about 0.15%/year
- Asymptomatic ventricular pre-excitation has a much better prognosis
- Avoid AV blocking agents in maintenance treatment
- Most patients with WPW syndrome should be referred for risk stratification and consideration for electrophysiological studies ± ablation of accessory pathway.

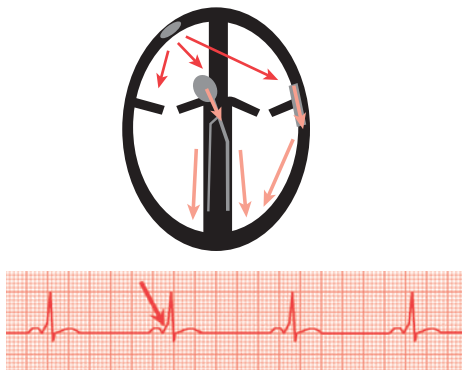


Fig. 10.17 Sinus rhythm and pre-excitation. There is a short PR interval and delta wave at the beginning of the QRS (arrow). Red arrows indicate a compulsory part of the rhythm/circuit; pink arrows indicate bystander (non-participating) pathways.

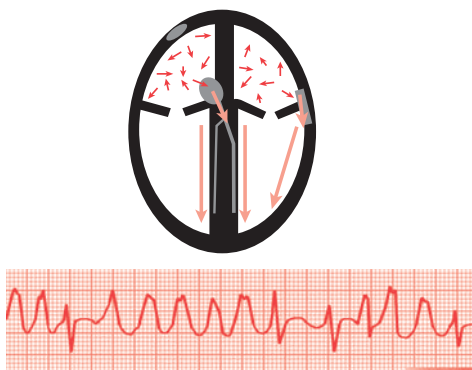






Fig. 10.18 Pre-excited AF. AF is conducted to the ventricles through a combination of the AV node (narrow complexes) and the accessory pathway (wide, pre-excited complexes). The accessory pathway tends to dominate producing a very rapid ventricular rate (p.415). Also see Management, p.163. Red arrows indicate a compulsory part of the rhythm/circuit; pink arrows indicate bystander (non-participating) pathways.

Ventricular fibrillation

Presentation

Complete cardiovascular collapse/cardiac arrest.



Causes

- Often 2° to ischaemic heart disease (ACS, MI); structural heart disease (HCM, cardiomyopathies) and ion channelopathies (Brugada syndrome,  p.177)
- Other cardiac precipitants include:
 - Pre-excited AF ( p.175, 415)
 - VT ( p.178)
 - Bradycardia/long QT induced torsade de pointes ( p.182)
- Non cardiac causes include:
 - Metabolic—severe electrolytes/acid–base disturbance
 - Respiratory—PE, tension pneumothorax
 - Neurology—massive intracranial event.

ECG diagnosis

Coarse irregular deflections—varying morphology, amplitude, and frequency (Fig. 10.19).

Immediate management

- Needs immediate defibrillation using standard ALS algorithms ( p.5)
- If VF is resistant to attempts at defibrillation then consider giving amiodarone 300mg IV and using a different defibrillator
- Treat reversible causes—correct K^+ , Mg^{2+}
- Repeated episodes of VF (electrical storms) require specialist input (see  p.184).

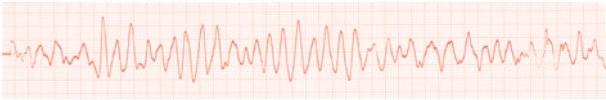


Fig. 10.19

Brugada syndrome

A collection of inherited defects in cardiac cell membrane ion channels which cause increased susceptibility to ventricular tachyarrhythmias (VT, VF), and can result in syncope or sudden death. The commonest affected gene is the SCN5A gene, encoding one of the sodium ion channels. The 12-lead ECG can show characteristic features of partial RBBB and right precordial (V1-3) ST-segment elevation (see p.407), though there are several variants and some require provocation with sodium channel blockers (e.g. ajmaline or flecainide) to reveal the changes (NB this is a specialised procedure for expert hands!). There is some evidence that environmental factors (e.g. exercise, dehydration) contribute to the arrhythmogenic potential. Implantable defibrillators may be required for selected patients.

Inherited long QT syndrome

A group of inherited defects in cardiomyocyte ion channels (predominantly the potassium channel) which lead to prolongation of the QT interval on the ECG, and a pre-disposition to ventricular arrhythmias, causing syncope or sudden death. It can be associated with Romano-Ward or Jervell-Lang-Nielsen syndromes. Several ECGs ± ambulatory ECG monitoring may be required for diagnosis. Exercise may be a precipitant for arrhythmias, and strenuous exertion should be avoided. Treatment is with B-blockers to reduce adrenergic drive and propensity to arrhythmias, pacemakers to prevent significant bradycardia and/or implantable defibrillators. See also p.344 for drug-induced QT prolongation.

⊕ Ventricular tachycardia

VT is usually a re-entrant arrhythmia that results from diseased or scarred myocardium 2° to ischaemic heart disease or non-ischaemic cardiomyopathy. It may also occur in the setting of acute myocardial ischaemia or even a 'normal heart', where the mechanism may result from automaticity or triggered activity (abnormal 'firing' of a ventricular focus).

- The ventricular rate may be anywhere between 100–300 bpm
- Tachycardia may be sustained (> 30 sec) or non-sustained
- The majority of episodes of VT are monomorphic, i.e. the circuit is consistent and stable and the QRS morphology does not change
- There is a subgroup of idiopathic monomorphic VT (including fascicular and RVOT tachycardia) that are believed to have a more benign prognosis (see Box 10.9)
- Polymorphic VT results in a beat-to-beat variation in QRS morphology and in the setting of a prolonged corrected QT interval (QTc) on the sinus rhythm ECG, is called 'torsade de pointes'
- Polymorphic VT usually causes collapse and is more often non-sustained although it may sustain and degenerate into VF.

ECG diagnosis of broad complex tachycardia

ΔThe differential diagnosis of a regular broad complex tachycardia is:

- VT
- SVT with bundle branch block (BBB).

▶A broad complex tachycardia should be assumed to be VT until proven otherwise. If in doubt, it is safer to mistreat an SVT as VT rather than treat a VT as an SVT.

▶80% of broad complex tachycardia will turn out to be VT; this increases to 95% if there is a prior history of MI or IHD.

▶Always make the diagnosis on a 12-lead ECG, not a rhythm strip.

▶Clinically, the rate and the degree of haemodynamic compromise are not good discriminators.

- The following clinical characteristics support a diagnosis of VT:
 - Old age
 - History of ischaemic or structural heart disease
 - Impaired LV function
- The following ECG features may suggest SVT with bundle branch block:
 - Typical RBBB/LBBB
 - Especially if the QRS morphology and axis is identical to that in sinus rhythm
 - Otherwise, broad complex tachycardia should be assumed to be VT.
- Adenosine is sometimes useful for diagnosis (see p.156).

Box 10.9**Fascicular VT**

- Typically has a QRS of 0.12–0.14 msec
- RBBB and leftward axis
- Usually responds to IV verapamil.

RVOT VT

- Typically has a QRS of 0.12–0.15 msec
- LBBB and inferior axis
- Usually respond to β -blocker therapy
- Can respond to IV adenosine.

Table 10.8 VT vs. SVT with bundle branch block

	Definitely VT	Probably VT	May be SVT with BBB
ECG criteria	AV dissociation Capture or fusion beats	Extreme axis deviation Concordance QRS duration >160 ms QRS not typical of RBBB/LBBB	Typical RBBB/LBBB QRS morphology and axis identical to that in sinus rhythm
Clinical characteristics	Older patient Known ischaemic or structural heart disease Impaired LV function		Younger patient (<35 years) Terminated with adenosine/vagal manoeuvres

BBB, bundle branch block

⊕ Monomorphic ventricular tachycardia

Presentation

Symptoms range from none to palpitation, chest pain, and dyspnoea; pre-syncope to haemodynamic collapse and cardiac arrest.

Principle causes

- Ischaemic heart disease—acute or chronic
- Non-ischaemic cardiomyopathies—DCM, HCM, ARVC
- Idiopathic—fascicular, RVOT.

ECG diagnosis


Regular broad complex tachycardia (Fig. 10.20). See  p.178 for ECG diagnosis of broad complex tachycardia).

Management

- Correct electrolytes (K^+ , Mg^{2+}) and treat underlying cause, e.g. MI
- VT that appears well tolerated has the potential to deteriorate rapidly, particularly in patients with known or suspected impairment of LV function.

Severe haemodynamic compromise

(Reduced conscious level, pulmonary oedema, cardiac ischaemia, hypotension with poor perfusion.)

- Oxygen
- Immediate synchronized DC shock under sedation/GA
- If pulseless, follow ALS algorithm ( p.5).


Mild–moderate haemodynamic compromise

(Adequate perfusion, mild chest tightness or SOB, alert and orientated.)

- Only consider adenosine if the arrhythmia is well tolerated and there is a high likelihood of SVT based on history or ECG
- Inform anaesthetist and prepare for back-up synchronized DC cardioversion
- In the meantime, attempt cardioversion with:
 - IV β -blockers or amiodarone
 - Consider lidocaine if BP stable.

▶ For recurrent episodes of VT, see  Electrical storm p.184.

Subsequent management

- Cardiac investigations, e.g. echocardiography, coronary angiography, MRI
- Consider maintenance drug therapy with β -blockers and/or amiodarone
- In cases of RVOT or fascicular VT ( p.179), consider verapamil
- Seek urgent cardiology review (ICD therapy may be indicated)
- Catheter ablation for VT is occasionally an option.

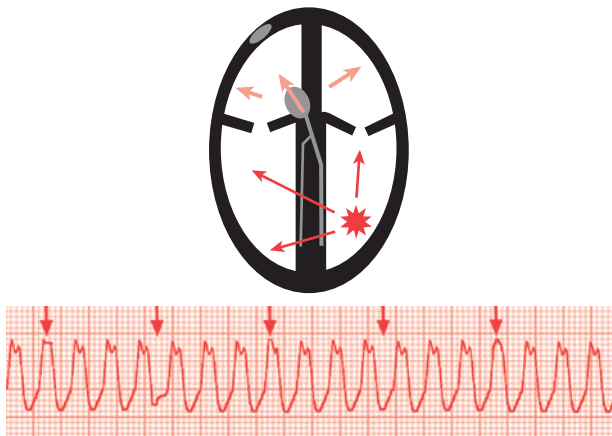


Fig. 10.20 Monomorphic VT. A regular, wide complex tachycardia. The QRS shape is constant although may be distorted by the independent P-wave activity if there is visible AV dissociation (arrows). Red arrows indicate a compulsory part of the rhythm/circuit; pink arrows indicate bystander (non-participating) pathways.

Polymorphic ventricular tachycardia/‘torsade de pointes’

Torsade de pointes is associated with long QTc, bradycardia, or pauses and is typically initiated following ‘R on T’ ectopic phenomenon.

Presentation

- Usually haemodynamic collapse/cardiac arrest if sustained
- May still be cardiovascularly stable if episodes are non-sustained.

Causes

- Congenital—long QT syndrome (see p.177)
- Drugs—see Box 10.10 and p.344
- Electrolyte abnormalities—low K^+ , low Mg^{2+}
- Bradycardia/pause-induced
- Myocardial ischaemia
- Others—significant metabolic derangement, subarachnoid haemorrhage.

ECG diagnosis

- Irregular broad complex tachycardia
- Regular variation of QRS morphology and axis (‘twisting of the point’ about the isoelectric baseline).

Immediate management (Fig. 10.22)

▶▶ Haemodynamic collapse is usually present or imminent if the arrhythmia is sustained. Urgent DC cardioversion is indicated. If pulseless, follow ALS algorithm (📖 p.5).

▶ Even if conscious and stable, or polymorphic VT is repetitive and non-sustained, prompt treatment is required as patients may deteriorate quickly:

- Check and correct electrolytes, especially Mg^+ , K^+ (aim >4.5 mmol/L)
- Treat possible underlying causes simultaneously, e.g. cardiac ischaemia
- If there is evidence of bradycardia/pause-initiated VT or if QTc in sinus rhythm >0.45 msec, treatment is geared towards increasing heart rate and reducing QTc:
 - Stop any precipitating drugs
 - IV magnesium is useful even if there is no hypomagnesaemia—give 1–2g (4–8 mmol) over 5–10 min in 100 mL 5% dextrose, then 0.5–1 g/hour infusion
 - Consider atropine/isoprenaline as a temporary measure
 - Temporary pacing at 90 bpm (see 📖 p.368)
- Amiodarone may make things worse by increasing QTc
- If the sinus rhythm QTc is normal and no bradycardia (in this case, usually due to myocardial ischaemia or obvious systemic cause):
 - Consider IV amiodarone or esmolol
 - Lidocaine can also be considered.

Subsequent management of polymorphic VT

- Potassium should be kept >4.5 mmol/L
- Avoid QT prolonging drugs
- Seek urgent cardiology review.

Box 10.10 Common QT prolonging drugs (see  p.344)

- Antiarrhythmic drugs—class I agents, sotalol
- Antimicrobials—macrolides, moxifloxacin, ketoconazole
- Psychiatric drugs—phenothiazines, tricyclic antidepressants, lithium.

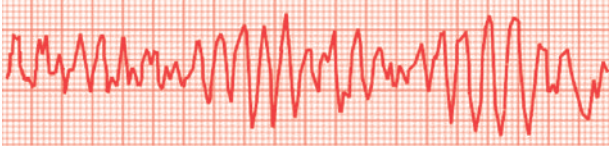


Fig. 10.21 Polymorphic VT. An irregular, broad complex tachycardia. With torsade des pointes QRS axis twists around the baseline.

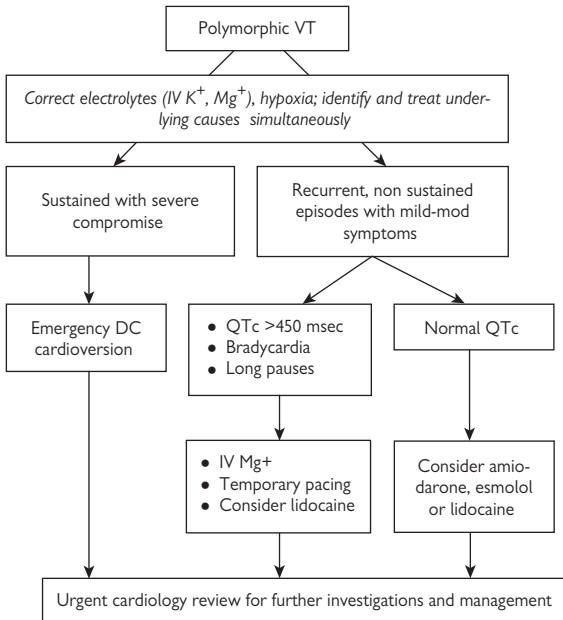


Fig. 10.22 Flowchart of management of polymorphic VT.

⚡ Electrical storms

- ▶ Seek early expert cardiology advice.
- VT or VF electrical storms are characterized by multiple, frequent, repetitive episodes of VT or VF, usually associated with significant haemodynamic compromise.

Immediate management

- Correct the correctable—electrolytes, myocardial ischaemia, drug intoxication
- Sedation with anaesthetist cover, often require intubation and ventilation to alleviate distress, increase oxygen delivery, and reduce the hyper-adrenergic state that may accompany repeated cardioversion
- Episodes may need to be terminated by repeated electrical cardioversions
- Antiarrhythmic drugs should be given, often >1 is necessary:
 - IV amiodarone and β -blockade are the mainstays of treatment
 - Alternative antiarrhythmic therapies include lidocaine or procainamide as an IV infusion (see 📖 p.155)
- ▶ Amiodarone/sotalol/procainamide should be avoided in torsade des pointes 2° to prolonged QTc
- Temporary pacing for overdrive and antitachycardia pacing (see Box 10.11).

Subsequent management

- Seek urgent cardiology advice
- If there is ongoing cardiac ischaemia, consider insertion of IABP \pm coronary intervention
- Rarely, it is necessary to put patients on bypass/ECMO to allow electrical storm to settle.

Box 10.11 Overdrive pacing

- Sustained monomorphic VT may be terminated painlessly by antitachycardia pacing in 80–90% of cases
- After positioning a transvenous pacing wire in the right ventricle (📖 p.368), pacing is performed at a rate 15–20 bpm faster than the VT
- On many temporary pacing boxes there is a 'x 3' setting on the rate for this reason
- A high output (5–10 V) may be required
- Capture of the VT is indicated by a change in QRS morphology and an increase in heart rate on the monitor to the pacing rate
- Pacing is abruptly terminated after 5–10 sec of ventricular capture
- ► There is a risk that acceleration of the VT may occur with degeneration to pulseless VT or VF so operators must be prepared for immediate defibrillation
- Once sinus rhythm has been restored, constant background pacing at 90–110 bpm may be performed to prevent recurrent attacks. This is particularly useful with polymorphic VT and a prolonged QT interval, especially in the setting of pauses or bradycardia
- Constant ventricular pacing may result in ↓cardiac output due to the loss of AV synchrony, particularly in the setting of poor LV function. This may be overcome with dual chamber AV sequential pacing.

ⓘ Implantable cardioverter defibrillators in the emergency room

ICDs are increasingly being implanted in certain patients (esp. ischaemic cardiomyopathy) to reduce the risk of sudden death due to ventricular tachyarrhythmia. They are programmed to recognize ventricular rates that exceed programmed parameters and are also able to deliver antitachycardia pacing (ATP), which is painless, or shocks (which can be painful) within seconds of the tachycardia commencing.

- It is common to programme ICDs to attempt ATP for VT that is more likely to be haemodynamically tolerated, e.g. rates between 150–180 bpm. Shocks will be delivered if ATP fails or the VT accelerates
- Fast VT (rates > 180 bpm) or VF will often be treated by immediate shock therapy
- ICDs are able to deliver up to 6 shocks during a single VT or VF episode; however, if sinus rhythm is transiently restored the counter returns to zero and recommences if VT or VF reinitiates
- Although ICDs try to distinguish between SVT and VT, if the device is uncertain, it will always assume the worst and treat as if it is VT. Patients may therefore receive inappropriate shocks for sinus or atrial tachycardias with rapid ventricular rates.

Presentation

- Usually well between shocks
- In addition to experiencing shocks, patients may be unwell with chest pain, dyspnoea, syncope, fever, etc.

Immediate management

- Patients who are completely well after 1 isolated shock do not require hospital admission, particularly if this is not the first time. They can be seen in ICD clinics within a few days
- It is important to exclude possible exacerbating causes especially for patients with multiple shocks or additional symptoms
 - Correct electrolytes, thyroid status
 - Treat myocardial ischaemia, sepsis, etc.
- Interrogation of the ICD is then useful to determine if shocks are:
 - Appropriate (ICD giving therapy for ventricular tachyarrhythmia) or
 - Inappropriate (device or lead failure, failure to recognize sinus/atrial tachyarrhythmia)
- Patients with inappropriate shocks should be monitored, with their ICDs disabled via the programmer
- Patients with multiple appropriate shocks should be treated for electrical storm (📖 Electrical storms, p.184). It is often useful to temporarily disable the ICD with a magnet.

Subsequent management

- Refer to cardiologist—may need new leads, programming changes, etc.
- Patients with appropriate shocks usually require drug changes.

Box 10.12 Use of a magnet

ICD shocks may be disabled by placing a magnet over the generator and securing with tape. This may be useful with repetitive inappropriate shocks due to device or lead failure or rapidly conducted atrial arrhythmias. It may also be appropriate as a temporary measure during electrical storms when VT is haemodynamically tolerated but resulting in frequent painful therapies.

► The patient must be monitored once a magnet is used as episodes of VF will not be treated by the ICD. The magnet does not disable the bradycardia functions of the ICD.

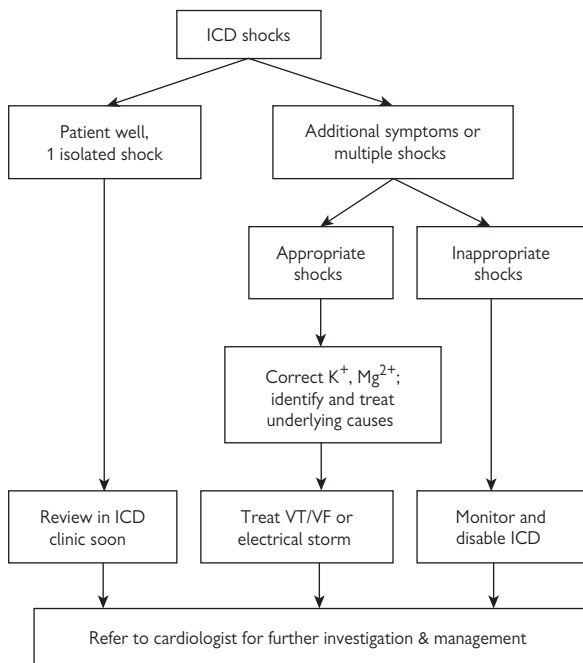


Fig. 10.23 Flowchart of the management of patients presenting with shocks from their ICD.

This page intentionally left blank

Aortic dissection

Introduction	190
Presentation	192
Clinical signs	192
Differential diagnosis	192
Investigations	192
Imaging	194
Management	196
Complications	198
Prognosis	198
Follow-up	198
Acute thoracic syndromes	200

Introduction

A tear in the aortic intima through which blood enters the aortic wall and strips the media from the adventitia

- The dissection may result in fatal aortic rupture or propagate distally generating a blood-filled space between the dissected layers
- The blood supply to major branches (including the coronary arteries) may be compromised
- If the aortic root is involved, the aortic valve may become incompetent and retrograde propagation to the pericardium may result in cardiac tamponade

The commonest site for aortic dissection is in the proximal ascending aorta within a few centimetres of the aortic valve or in the descending aorta just distal to the left subclavian artery. See Box 11.1 for causes

Classification is usually made according to the Stanford classification (Fig. 11.1) that influences subsequent management:

📍: **Type A** aortic dissection involves the ascending aorta and management is usually a surgical emergency. Don't dawdle!

① **Type B** aortic dissection spares the ascending aorta and management is initially medical.

Box 11.1 Causes and associations

- Hypertension (70%)
- Bicuspid aortic valve (7–14%)
- Marfan syndrome (5–9%) (📖 p.199)
- Aortic coarctation (📖 p.262)
- Trauma—particularly deceleration injury
- Iatrogenic—angiography.

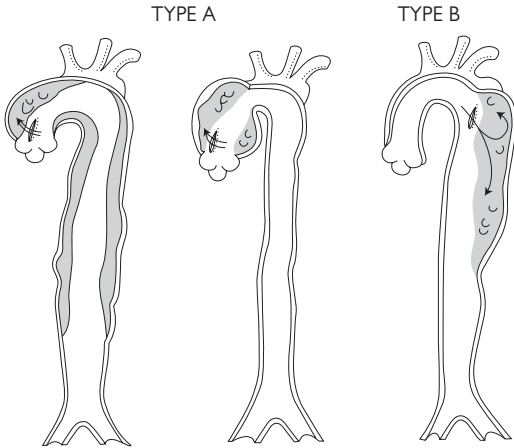


Fig. 11.1 Stanford classification of aortic dissection. Type A: all dissections involving the ascending aorta. Type B dissection does not involve the ascending aorta.

Presentation

► The cardinal symptom is *pain* and is usually instantaneous, of cataclysmic severity, pulsatile or tearing, in the anterior thorax or interscapular region, and migrates as the dissection propagates.

The history \pm background hypertension are important for suspecting the diagnosis, as signs may be minimal.

Clinical signs

- ► There may be none
- The patient may appear shocked but BP can be normal or elevated
- Pulmonary oedema can occur due to severe AR
- Absent or reduced pulses occur in 20% of patients (but can fluctuate)
- Signs of AR or pericardial tamponade can occur in type A aortic dissection
- A left pleural effusion is occasionally seen.

Differential diagnosis

- Intramural haematoma (📖 p.200)
- Penetrating atherosclerotic ulcer (📖 p.200)
- Acute coronary syndromes (📖 p.39).

Investigations

CXR

- An abnormal aortic silhouette appears in up to 90% of cases (NB 10% of CXRs will appear normal)
- Separation of the intimal calcification that occurs in the aortic knob by >1 cm (the 'calcium sign') is suggestive of aortic dissection
- Left-sided pleural effusions can occur and are more common with descending dissections.

ECG

- Non-specific ST and T wave changes are common
- ECG changes of LV hypertrophy may occur in patients with long-standing hypertension
- Coronary artery involvement is uncommon but more commonly affects the right coronary artery (resulting in inferior ST elevation).

Blood tests

See Box 11.2.

Box 11.2 Blood tests

- ► May delay diagnosis so do not await results before arranging further imaging.
- Blood should be taken for FBC, creatinine, cardiac enzymes, and group and save
- A mildly raised white cell count is common
- Haemoglobin level may be reduced if there has been a significant bleed
- Lactate dehydrogenase can be elevated if there has been significant haemolysis
- D-dimers are usually elevated
- Cardiac troponin levels may be elevated and are associated with a worse in-hospital outcome
- Immunoassays of monoclonal antibodies to smooth muscle myosin heavy chains have a high sensitivity and specificity for the diagnosis of aortic dissection, but are rarely available in the time required.

Imaging

Imaging should be performed as quickly as possible using the most accessible and accurate modality that your hospital can provide. This is usually with CT and TTE. Aspects to look for are:

- The entry site of the dissection—ideally, but not always seen
- If the aortic valve is competent
- If there is a pericardial effusion or tamponade
- Any involvement of the coronary arteries.

Computed tomography

With modern spiral scanners, this has a sensitivity and specificity of 96–100% and is the standard investigation for suspected aortic dissection.

Magnetic resonance imaging

Sensitivity and specificity of nearly 100%. Non-invasive. Availability and reduced access to an unwell patient are the main limitations on its use. See Fig. 11.2.

Tranoesophageal echocardiography

Useful for imaging the proximal ascending aorta, identifying involvement of coronary ostia, and examining the aortic valve (Fig. 11.3). Sensitivity of ~98% and specificity of ~95%. Patients usually require sedation. It is ideally performed immediately prior to surgery after surgical consent has been obtained.

Transthoracic echocardiography

Can determine the involvement of the aortic valve, LV function and identify pericardial effusions. Sensitivity of 59–85% and specificity of 63–96% for identifying dissection.

► A normal transthoracic echocardiogram does not exclude aortic dissection.

Aortography

Invasive procedure with associated risks. Requires contrast material and takes time to perform. Sensitivity of 77–88% and specificity of 94%. It is now rarely performed as other imaging techniques are quicker and safer.

Coronary angiography

Not routinely performed in patients with aortic dissection. Chronic coronary disease is seen in a quarter of patients with aortic dissection but this has not been shown to have a significant impact on outcome.

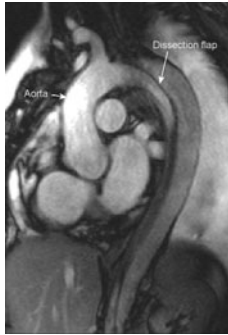

Fig. 11.2 MRI of a type B aortic dissection. There is a dissection flap in the descending aorta

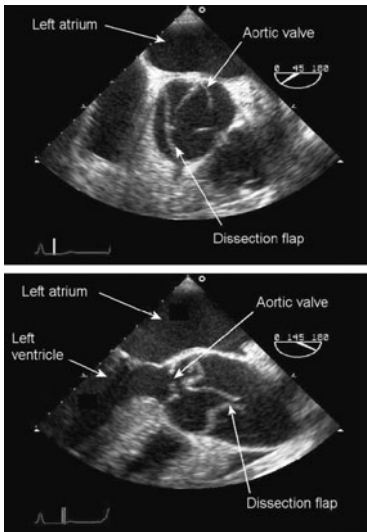


Fig. 11.3 TOE showing a type A aortic dissection. Just above the aortic valve in the proximal ascending aorta is a dissection flap. Top: transverse view. Bottom: longitudinal view

Management

Immediate management

- ► Opiate analgesia should be given to eliminate pain.
- ► Lower systolic BP to <120 mmHg with IV antihypertensive drugs:
 - β -blockers and the vasodilator sodium nitroprusside are the traditional first-line therapies (see Box 11.3)
 - IV isosorbide dinitrate and oral nifedipine are alternatives in patients with contraindications to β -blockers
- In hypotensive patients, it is important to exclude pericardial tamponade and check the BP in both arms before commencing fluid resuscitation
- ⚠ Pericardiocentesis should be performed in the operating theatre if possible as it can precipitate irretrievable haemodynamic collapse
- Cross-match blood (at least 6 units)
- Urinary catheter and monitoring of urine output
- Transfer patient to ICU for close observation.

Subsequent management

► *Type A* aortic dissections (involving the ascending aorta) should be considered for emergency surgery. Surgery usually involves excision of the intimal tear in the ascending aorta and interposition of a Dacron™ graft. Discuss type A dissections with the cardiothoracic team.

► *Type B* aortic dissections are usually managed medically. Surgery for type B dissections should be considered if there is evidence of proximal extension, progressive aortic enlargement, or ischaemic complications from major branch artery involvement, though is rarely undertaken as an emergency. Surgical risk is high, with paraplegia from spinal artery damage a particular concern. An alternative treatment if intervention is required is endovascular stenting—see Box 11.4 and Fig. 11.4.

Contact the local tertiary cardiac centre for advice about type B dissection management if necessary.

Box 11.3 IV antihypertensive therapy

- **Labetalol** is a β -blocker with α -blocking effects at high doses. It is given as an IV injection of 50 mg over 1 min followed by a continuous infusion of 1–2 mg/min
- **Esmolol** is a short-acting β -blocker. It is administered as a bolus of 500 mcg/kg and as an infusion of 50–200 mcg/kg/min
- **Propranolol** is given as an IV injection of 1 mg over 1 min and repeated every 5 min until an adequate response has been achieved or a total of 10 mg has been given. Additional propranolol should then be given every 4 hours
- **Sodium nitroprusside** is given as an infusion of 0.5–1.5 mcg/kg/min increasing in steps of 0.5 mcg/kg/min every 5 min. Dose range 0.5–8 mcg/kg/min. It is usually given with a β -blocker to prevent reflex tachycardia.

Box 11.4 Endovascular aortic stenting

Endovascular stenting is a percutaneous procedure that may be considered for aortic dissection starting distal to the left subclavian artery or to treat the complications of penetrating aortic ulcers. A large covered stent can be delivered within the descending aorta to cover the intimal tear (Fig. 11.4). In suitable cases this obliterates flow into the false lumen, relieving branch ischaemia and preventing further aneurysmal dilatation.

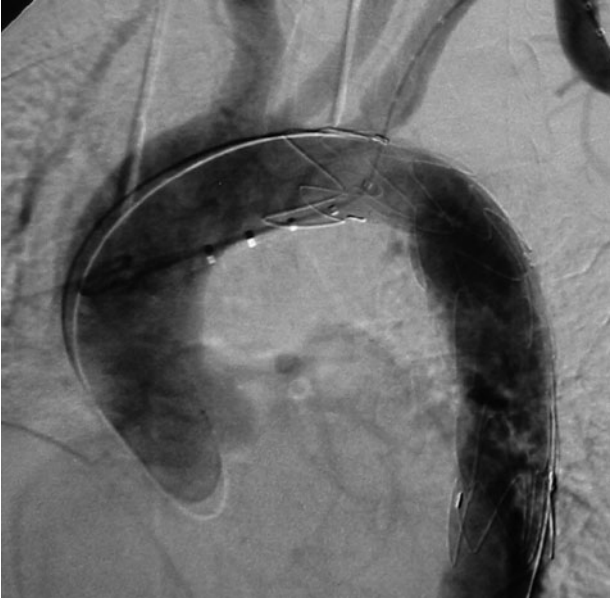

Fig. 11.4 Aortography during implantation of a covered stent in a patient with limited rupture of the descending aorta. The stent is carefully positioned just distal to the left subclavian artery.

Complications

Type A dissection

- Death from aortic rupture
- Myocardial ischaemia/infarction
- Pericardial tamponade
- Aortic valve incompetence
- Cerebrovascular event.

Type B dissection

- Visceral ischaemia
- Limb ischaemia
- Renal failure.

Prognosis

- The mortality from aortic dissection is initially as high as 1% per hour
- The in-hospital mortality for type B aortic dissection is correlated to the aortic diameter
- The surgical mortality is about 10–15% for type A dissection and slightly higher for type B
- The long-term survival for patients with either surgically-treated type A or medically-treated type B dissections is about 75% at 5 years
- The false lumen commonly remains patent during long-term follow-up

Follow-up

- Long-term oral antihypertensive therapy should be initiated to maintain a systolic BP <130 mmHg
- Drug therapies include β -blockers, ACE-inhibitors, and calcium antagonists
- Surveillance is recommended for all patients using the imaging modality with which there is the most local expertise, particularly in the first 2 years after presentation
- Surgery or endovascular stenting should be considered if there is evidence of progressive aortic enlargement

Further reading

1. Nienaber CA et al. Aortic dissection: New frontiers in diagnosis and management. Part I: From etiology to diagnostic strategies. *Circulation* 2003; **108**: 628–35.
2. Nienaber CA et al. Aortic dissection: New frontiers in diagnosis and management. Part II: Therapeutic management and follow-up. *Circulation* 2003; **108**: 772–8.

Box 11.5 Marfan syndrome

- Autosomal dominant connective tissue disease with a prevalence of at least 1 in 10,000
- Common cardiovascular features include:
 - Mitral valve prolapse (75%)
 - Dilatation of the aortic sinuses (90%)
- Aortic dilatation is usually limited to the proximal ascending aorta (Fig. 11.5) with loss of the sinotubular junction and a flask-shape appearance
- AR is common when the aorta reaches 50 mm in diameter (normal diameter <40 mm)
- The risk of dissection increases with the diameter of the aorta but occurs relatively infrequently below a diameter of 55 mm. Aortic dissection in Marfan syndrome is usually type A and begins just above the coronary ostia. 10% of cases begin distal to the left subclavian artery (type B)
- Long-term β -blockade has been shown to reduce the rate of aortic dilatation and reduce the risk of aortic dissection
- Angiotensin antagonists may reduce aortic dilatation, but trials are ongoing in this area
- Surgery is usually considered when the aorta reaches 50 mm

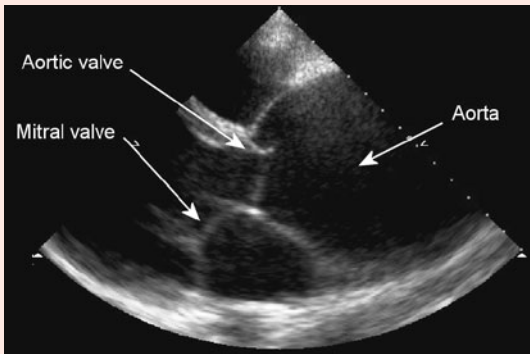


Fig. 11.5 TTE of an enlarged ascending aorta in a patient with Marfan syndrome

Weblink

The Marfan Foundation: www.marfan.org

Acute thoracic syndromes

See Fig. 11.6.

🚫 Intramural haematoma

- The result of haemorrhage within the media and adventitia of the aortic wall. The aortic intima remains intact
- Believed to be due to rupture of the aortic vasa vasorum
- Presentation can mimic aortic dissection
- Patients are typically elderly, with a history of hypertension and many have aortic atherosclerosis
- The diagnosis is made by excluding an intimal tear
- CT or MRI is the investigation of choice. A non-contrast-enhancing crescent along the aortic wall with no false lumen or associated atherosclerotic ulcer is usually demonstrated
- There is increasing evidence that an intramural haematoma may be a precursor of aortic dissection
- Treat as for aortic dissection with analgesia and IV antihypertensive agents
- Surgery is indicated when the ascending aorta is involved.

⚠️ Penetrating atherosclerotic ulcer

- Ulceration of an atherosclerotic lesion of the aorta that penetrates the elastic lamina of the aorta allowing haematoma formation within the media
- Usually in the descending aorta in elderly smokers
- Clinical presentation is similar to aortic dissection with chest or back pain
- In up to 25% of cases, penetration through to the adventitia results in false aneurysm formation and transmural aortic rupture occurs in up to 10% of cases
- Aortography is the diagnostic standard, but increasingly CT or cardiac MR are used for diagnosis.
- Standard treatment is surgery but this is not often required and there has been increasing success with endovascular stenting.

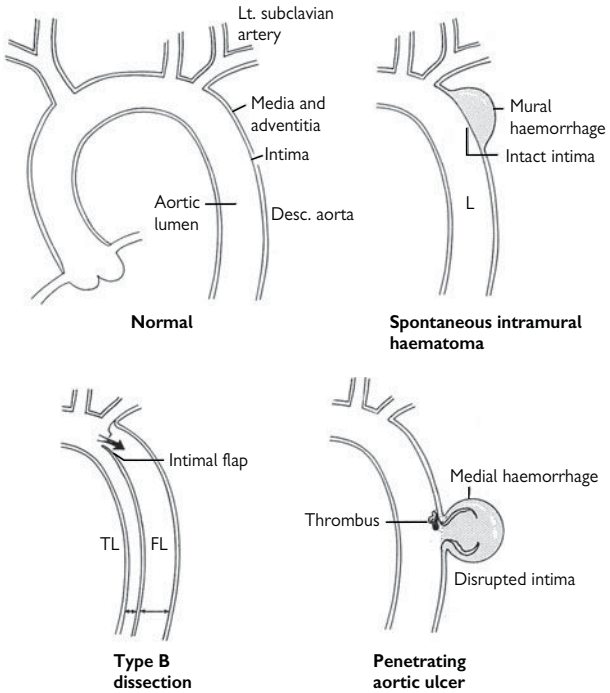


Fig. 11.6 Acute thoracic syndromes. An intramural haematoma is characterized by an intact intima. Type B aortic dissection usually starts distal to the left subclavian artery. A penetrating aortic ulcer involves a disrupted intima and haemorrhage into the media.

This page intentionally left blank

Pericardial disease

Pericarditis 204

Pericardial effusion and tamponade 208

Constrictive pericarditis 210

❓ Pericarditis

Inflammation of the pericardium; may involve adjacent myocardium ('perimyocarditis').

See Box 12.1 for causes.



Presentation

- Chest pain (📖 p.14 for differential diagnosis)
 - Typically retrosternal soreness/ache; can be sharp
 - Sometimes positional—worse on lying flat when visceral and parietal pericardium rub together; better sitting up
 - ± radiation to shoulder / scapula / back
 - Can be worse with deep inspiration.
 - Onset over hours, occasionally minutes/sudden.
- ± SOB—usually mild
- May be history of coryzal illness in preceding 1–3 weeks.

Clinical signs

- Often none
- Pericardial rub—rough sound 'like feet crunching on snow' or 'saw-like' in both systole and diastole; best heard at the left sternal edge. Similar to pleural rub, but synchronized to cardiac cycle. *Clinches the diagnosis!*
- Rarely, signs of tamponade may be present (📖 p.208).

Box 12.1 Causes of pericarditis

- Often idiopathic
- Viral (e.g. Coxsackie, Epstein–Barr)—history of recent mild generalized illness is not uncommon but specific virus rarely identified
- Bacterial—tuberculous, acute rheumatic fever, pneumonia
- Uraemia
- Autoimmune—SLE, rheumatoid arthritis
- Post-MI—2 time periods:
 - Acute: few days post MI, esp. if large
 - Later: 2–8 weeks (as part of Dressler syndrome, see  p.58)
- Post-cardiac surgery
- Hypothyroidism
- Chest radiotherapy
- Trauma, e.g. blunt chest injury (see  p.350)

Investigations

- ECG (can be normal in 10%)—2 main patterns (Fig. 12.1):
 - 1. 'Scooped' or 'saddle-shaped' ST elevation in several leads; may not correspond to coronary artery distribution (ECG p.404)
 - 2. Non-specific T-wave inversion
- Look for PR segment depression. It is highly specific for pericarditis (p.207) and believed to be due to underlying atrial myocarditis
- Blood tests—FBC, CRP, blood cultures (?infection), U&E (?uraemia), thyroid function (?hypothyroid), ASO titre (?rheumatic fever), ± autoimmune screen
- Cardiac troponin—may be raised in pericarditis; more common if ST elevation on ECG and probably represents peri-myocarditis
- Echocardiography—should be considered in all patients with pericarditis, particularly in those who are systemically unwell and/or hypotensive (?pericardial effusion, ?myocarditis). It can also be useful to exclude acute MI in difficult cases (MI: regional LV dysfunction corresponding to coronary artery territory)
- Not all pericardial effusions need to be drained
- Pericardial fluid can be sent for Ziehl–Nielsen staining (for TB), cytology, protein, LDH (see p.000 for pericardiocentesis)

Diagnostic clues

- History, especially the character of pain
- Patient often younger and usually relatively well compared to typical MI patient, not clammy/grey/sweaty
- The ECG can sometimes look like an acute MI but does not have reciprocal changes, and the history and well appearance of the patient are usually clues against this. The correct diagnosis is important, as giving thrombolysis to a patient with pericarditis can risk haemorrhagic tamponade. If in real doubt, an echocardiogram can be helpful
- Cardiac troponins are not a discriminator between MI and pericarditis (troponin I can be elevated to double figures)

Management

- Analgesia—NSAIDs/aspirin often very effective (e.g. diclofenac 50 mg TDS PO or ibuprofen 400 mg TDS PO). Others include paracetamol ± codeine (e.g. co-codamol 500/30 2 tabs QDS)
- Colchicine 500 mcg BD PO can be used for recurrent attacks, with low-dose corticosteroids or immunosuppressants used for resistant recurrent episodes
- Treat any identified cause
- Observe for tamponade if large pericardial effusion present—drain if necessary
- Uncomplicated cases do not need hospital admission.

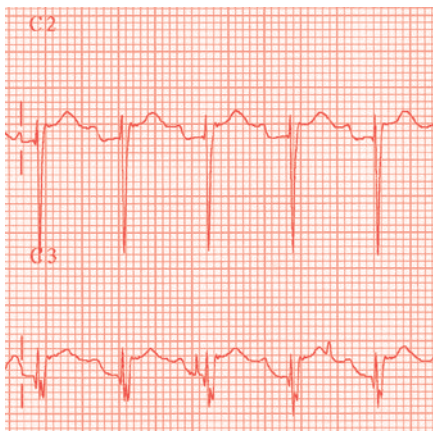


Fig. 12.1 ECG of leads V1 and V2 showing PR segment depression and ST elevation in pericarditis.

Pericardial effusion and tamponade

① **Pericardial effusion:** abnormal accumulation of fluid in the pericardial sac (Box 12.2).

⚠ **Cardiac tamponade:** occurs when a pericardial effusion causes haemodynamic compromise. Tamponade usually occurs following a relatively rapid increase in fluid accumulation—a gradual increase can be better tolerated (even large effusions), so the volume of pericardial fluid is not a reliable indicator of tamponade.

Presentation

- Chest discomfort—as per pericarditis (see 📖 p.204)
- Breathlessness
- Cough and dysphagia.

If tamponade:

- Faintness and syncope
- With signs of its complications due to reduced cardiac output—renal failure, hepatic ischaemia, etc.

Clinical signs (all indicate tamponade)

- Tachycardia (>100 bpm) is almost universal. May be lower in hypothyroid and uraemia
- Reduced pulse pressure
- Hypotension—may be normal in pre-existing hypertension
- Jugular venous distension—rises on inspiration - Kussmaul's sign
- Pulsus paradoxus (see Box 12.3)—the normal systolic pressure difference between inspiration and expiration is ↑ to >10 mmHg. Clinically the pulse fades on inspiration
- Muffled heart sounds, non-palpable apex beat
- Dyspnoea or tachypnoea with clear lungs.

Investigations

- ECG—reduced voltages, changing axis (as the heart swings in the fluid)
- CXR—globular heart, convex or straight left heart border
- Echocardiography—confirms effusion (Fig. 12.2). Common findings of **tamponade:**
 - Diastolic collapse of RV free wall and RA
 - Dilated IVC with no inspiratory collapse and reversed flow with atrial contraction
 - Tricuspid flow increases during inspiration
 - Mitral flow decreases during inspiration

Management

Uncomplicated effusions

Usually resolve with time and generally do not require pericardiocentesis unless this is helpful for identifying the cause. The cause should be sought and regular echocardiography arranged to ensure resolution.

Cardiac tamponade

- Pericardiocentesis should be performed urgently (📖 p.372)—removing a small amount of fluid can improve haemodynamics considerably
- Fluid resuscitation—but do not delay pericardiocentesis.

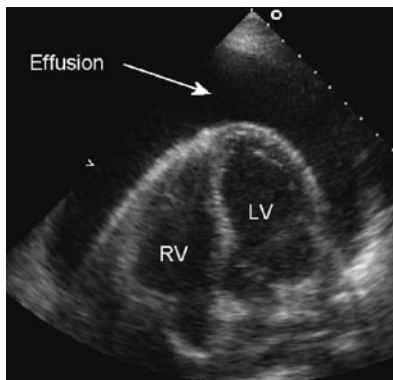



Fig. 12.2 TTE demonstrating a large pericardial effusion overlying the left (LV) and right (RV) ventricles

Box 12.2 Causes of pericardial effusion

- As per pericarditis (see  Box 12.1, p.205)
- May occur as a complication of PCI and electrophysiology procedures. Often results in tamponade due to the rapid rate of fluid accumulation—be aware in the hypotensive patient just returned to the ward
- Large effusions are commonly associated with malignancy, uraemia, or TB
- Effusions without inflammatory signs (pain, friction rub, fever, diffuse ST elevation) are usually associated with a malignant effusion.

Box 12.3 How to look for pulsus paradoxus

Pulsus paradoxus is an exaggeration of normal physiology, despite the name! Normally, there is a small BP difference between inspiration and expiration (negative intrathoracic pressure during inspiration reduces flow into the LA causing a slight ↓ in BP). In cardiac tamponade, the heart is more volume-dependant and a small fall in filling pressure → larger falls in output than normal. This results in a larger variation in BP during the respiratory cycle, which can be felt if severe.

Technique

- Inflate a BP cuff to above the highest systolic pressure
- Reduce the cuff pressure very slowly, listening carefully to the sounds
- When the 1st sounds are heard, they will be in expiration only, with silence during inspiration—note the cuff pressure
- Reduce the cuff pressure again slowly until the sounds are heard throughout the whole respiratory cycle—note this 2nd pressure
- The difference between the 2 BP measurements is the 'paradox'. Normally this is <10 mmHg. In pulsus paradoxus, it is >10 mmHg.

② Constrictive pericarditis

Imprisons the heart. Resembles congestive cardiac failure but the clinical picture is not due to heart 'failure', rather the cardiac function has been impeded due to impaired filling. See Box 12.4 for causes.

Presentation and signs

- SOB is the usual symptom
- Chronic venous congestion with prominent x and y descents in the JVP
- Peripheral oedema—lungs often clear
- Abdominal distension—ascites, hepatosplenomegaly
- Hypotension
- Loud or palpable S₃ due to rapid ventricular filling—pericardial knock
- Atrial arrhythmias are common.

Investigations

- Exclude TB—Mantoux, early morning sputum and urine
- ECG—non-specific T-wave changes, low voltages, broad P wave, AF
- CXR—pericardial calcification (lateral films), pleural effusions

Echocardiography

- Pericardial thickening and calcification with biatrial enlargement
- Rapid early filling—↑E:A ratio
- Dilated venae cavae and hepatic veins with ↓respiratory fluctuation
- Paradoxical ventricular septal movement in diastole—flattening of the septum on inspiration
- ↑tricuspid flow and ↓mitral flow on inspiration—as for tamponade
- Normal tissue Doppler velocities—differentiates from restrictive cardiomyopathy.

CT/MRI

Pericardial thickening (>6 mm) and calcification, biatrial enlargement, dilated venae cavae, diastolic septal flattening.

Cardiac catheterization

Often no longer required for diagnosis, but a characteristic pressure pattern can sometimes be seen:

- LV end-diastolic pressure = RV end-diastolic pressure throughout respiration (different by >7 mmHg in restrictive cardiomyopathy). Both are elevated and have a 'dip and plateau' (square root) configuration (Fig. 12.3)
- Atrial pressures are high and equal with prominent x and y descents.

Management

- Diuretic therapy, salt restriction
- Surgical pericardectomy can be considered for severe symptoms.

Box 12.4 Causes of constrictive pericarditis

- Most cases are idiopathic—the initial acute episode may be subclinical
- Viral, TB, and pyogenic infections
- Therapeutic irradiation
- Post cardiac surgery.

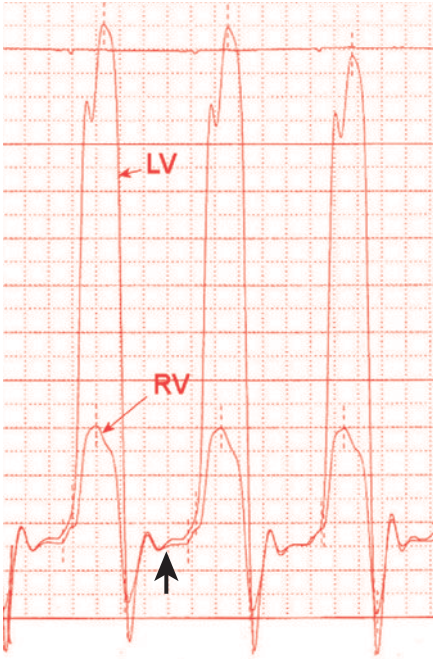


Fig. 12.3 Pressure trace during simultaneous left and right heart catheterization in a patient with pericardial constriction. Left (LV) and right (RV) ventricular traces show equal and raised diastolic pressures (thick arrow) with a 'dip and plateau' appearance.

This page intentionally left blank

Pulmonary vascular disease

Pulmonary embolism 214

Pulmonary hypertension 220

Cor pulmonale 224

! Pulmonary embolism

The annual incidence of PE is 60–70/100,000 with half of cases occurring in hospital. In-hospital mortality ranges from 6–15%. The most common cause is VTE but non-thrombotic causes include air, fat, amniotic fluid, tumour fragments, and septic emboli.

The diagnosis of PE should be based on a combination of clinical assessment and appropriate imaging.

Presentation and signs

- Most patients with PE are breathless (80% of cases) and/or tachypnoeic (respiratory rate >20/min, 60% of cases)
- Patients may also present with chest pain (50% of cases), cough, syncope and haemoptysis
- Tachycardia and fever are common
- There may be symptoms or signs of an underlying malignancy
- Massive PE may present as cardiac arrest or shock
- Chronic recurrent PEs may present with signs and symptoms of pulmonary hypertension and progressive right heart failure
- Elevated JVP with prominent a- and v-waves, loud P₂, TR, hypotension, gallop rhythm, pleural rub, peripheral oedema, and cyanosis may occur.
- Also see Box 13.1.

Clinical probability

Patients should be carefully assessed based on history, physical examination, and known risk factors (Box 13.2) into low, intermediate, and high clinical probability of PE.

- The patient must have clinical features of PE—breathlessness and/or tachypnoea with or without chest pain and/or haemoptysis
- 2 other clinical factors are sought:
 - a) The absence of another reasonable clinical explanation and
 - b) The presence of a major risk factor
- Where (a) and (b) are true the probability is *high*
- If only 1 is true the probability is *intermediate*
- If neither is true the probability is *low*.

! Massive PE

- Massive PE is highly likely if all the features listed are present:
 - Collapse/hypotension
 - Unexplained hypoxia
 - Engorged neck veins
 - RV gallop.

Box 13.1 Symptoms and signs in suspected PE**Symptoms**

- Dyspnoea 80%
- Chest pain (pleuritic) 52%
- Chest pain (substernal) 12%
- Cough 20%
- Haemoptysis 11%
- Syncope 19%

Signs

- Tachypnoea (20/min) 70%
- Tachycardia (>100/min) 26%
- Signs of DVT 15%
- Fever (>38.5°C) 7%
- Cyanosis 11%

Box 13.2 Risk factors**Major risk factors**

- Major abdominal/pelvic surgery
- Recent hip/knee replacement
- Lower limb fracture
- Varicose veins
- Recent Caesarean section
- Postpartum period
- Abdominal/pelvic malignancy
- Advanced/metastatic malignancy
- Prolonged hospitalization/institutional care
- Previous venous thromboembolism
- Inherited thrombophilia.

Minor risk factors

- Congestive cardiac failure
- Congenital heart disease
- Hypertension
- Advanced age
- Acute medical illness
- Superficial venous thrombosis
- Indwelling central venous catheter
- Oral contraceptive pill
- Hormone replacement therapy
- Chemotherapy
- COPD
- Thrombotic disorders
- Long-distance sedentary travel
- Obesity.

Investigations

Blood tests

- Arterial blood gases—hypoxaemia, hypocapnia, mild respiratory alkalosis, metabolic acidosis due to tissue hypoperfusion
- FBC, U&E, D-dimer
- Cardiac troponin may be elevated due to right heart strain but is not of diagnostic value.

D-dimer assay

- Should only be performed following assessment of clinical probability
- Need not be performed in those with a high clinical probability of PE
- A negative assay reliably excludes PE in patients with low or intermediate clinical probability
- High rates of false positive from advancing age, inflammatory states, pregnancy, surgery, and malignancy.

Thrombophilia screen

Testing for thrombophilia should be considered in patients aged <50 with recurrent PE or in those with a strong family history of proven VTE. Testing should be performed from samples pre-anticoagulation treatment or after the completion of treatment

CXR

- Used to exclude conditions that mimic PE—chest infection, pneumothorax
- May show wedge-shaped peripheral infarcts, pulmonary effusions, pulmonary oligoemia, enlarged proximal pulmonary arteries.

Diagnostic imaging

- CT pulmonary angiography (CTPA) is the recommended imaging tool
- Isotope lung scanning may be considered following a normal CXR if good quality facilities and reporting are on site and the patient has no significant concurrent cardiopulmonary disease. A non-diagnostic isotope lung scan should be followed by further imaging. There is also a high false positive rate. If isotope lung scanning is normal then PE is reliably excluded
- Venous ultrasonography—in patients with co-existing DVT, leg ultrasound is often sufficient to confirm VTE. A single normal leg ultrasound does not exclude subclinical DVT however
- Conventional pulmonary angiography can be considered in selected cases on advice from a cardiologist or radiologist (see Fig. 13.2).

Echocardiography

- Can be abnormal in massive PE (right heart dilatation and global hypokinesia with sparing of apex) and can provide non-invasive information on pulmonary artery pressures
- May provide an alternative diagnosis—aortic dissection, pericardial tamponade, myocardial dysfunction
- There is little additional benefit from TOE.

ECG

- The most common finding is sinus tachycardia (see Fig. 13.1).
- Non-specific ST and T wave changes and atrial arrhythmias are common
- Incomplete or complete RBBB and RV strain pattern occur.
- The classic S₁Q₃T₃ pattern is rare.

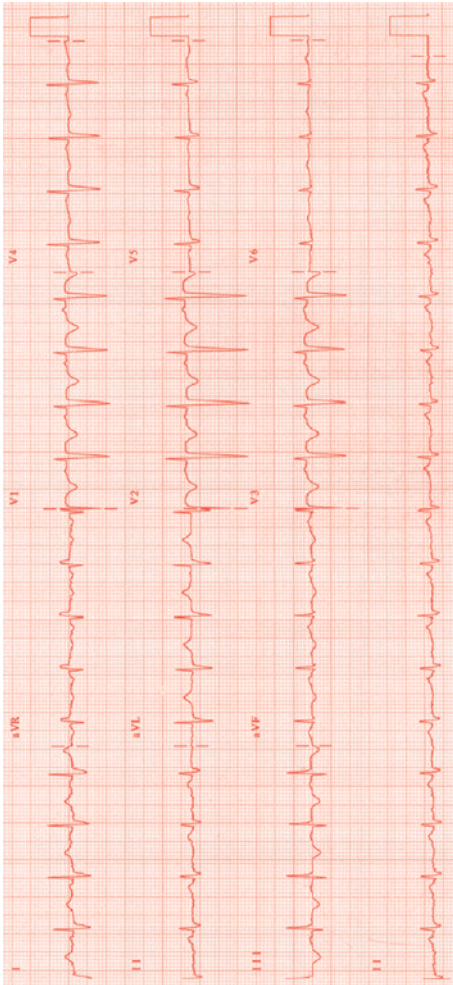


Fig. 13.1 ECG in massive PE. Sinus tachycardia with widespread T-wave inversion. There is a large S wave in I with a Q wave and T inversion in lead III.

Management

- Institute resuscitation measures according to haemodynamic status:
 - Oxygen
 - Analgesia—opiates or NSAIDs such as ibuprofen or diclofenac if pleuritic pain
 - Cautious volume expanders if hypotensive
 - Dobutamine for right-side heart failure and shock
- LMWH should be commenced before imaging if clinical probability of PE is high or intermediate
- There is good evidence showing LMWH to be superior to UFH
- Use UFH when rapid reversal of anticoagulation is considered or in patients with massive PE when thrombolysis/ invasive intervention is considered
- Oral anticoagulation should be started once VTE is confirmed, target INR is 2–3
- Current recommendations for duration of anticoagulation are:
 - 4–6 weeks for temporary risk factors
 - 3 months for 1st idiopathic PE
 - At least 3 months for other causes.

Thrombolysis

- Evidence for reduction in mortality is sparse and thrombolysis should not be used as 1st-line treatment in non-massive PE
- In patients with massive, life-threatening PE refractory to haemodynamic support with fluids give alteplase (rt-PA) 50 mg bolus
- Thrombolysis may be instituted on clinical grounds alone if cardiac arrest is imminent
- In stable patients with confirmed massive PE, dose of rt-PA for thrombolysis is 100 mg over 90 min
- Should be followed by UFH as an infusion
- Invasive approaches as an alternative or adjunct to thrombolysis (thrombus fragmentation or thrombectomy) should be considered on advice from a cardiologist or radiologist.

Invasive procedures

Right heart catheterization (with potential direct delivery of thrombolysis to the pulmonary circulation ± mechanical disruption of thrombus) and surgical pulmonary embolectomy have been used, but are of unproven value in general, and only considered for the most extreme cases.

Further reading

British Thoracic Society guidelines for the management of suspected acute pulmonary embolism. *Thorax* 2003; **58**: 470–84.

Torbicki A et al. Guidelines on the diagnosis and management of acute pulmonary embolism: The Task Force for the Diagnosis and Management of Acute Pulmonary Embolism of the European Society of Cardiology (ESC). *Euro Heart J* 2008; **29**:2276–315.

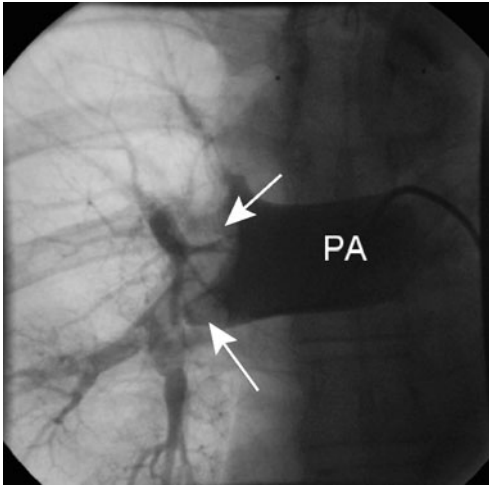


Fig. 13.2 Pulmonary angiography of the right pulmonary artery (PA) demonstrating large filling defects (arrowed) in keeping with massive pulmonary emboli.

② Pulmonary hypertension

- An increase in mean pulmonary arterial pressure >25 mmHg at rest or >30 mmHg with exercise
- Classified by the World Health Organization according to common pathobiological features (see Box 13.3)
- Primary pulmonary hypertension is the diagnosis in patients with pulmonary arterial hypertension of unexplained aetiology
- Is usually already established when the patient presents

Presentation

- Breathlessness is the usual complaint although some patients present with exertional syncope (fixed or reduced cardiac output), peripheral oedema or angina (from RV ischaemia)
- Angina may also be due to dynamic compression of the left main stem coronary artery from an enlarged pulmonary artery
- Signs include:
 - Elevated JVP with a large a wave—large v wave if severe TR
 - Low volume pulse
 - RV heave—left parasternal
 - Loud pulmonary component of the S_2
 - Split S_2 —widens as RV fails or with RBBB
 - Systolic murmur—TR
 - Diastolic murmur—PR
 - Central and peripheral cyanosis
 - Pulsatile liver, peripheral oedema, ascites
 - Signs of associated disease, e.g. sclerodactyly in scleroderma

Investigations

- **ECG**—RV hypertrophy (📖 p.406) is highly specific but has a low sensitivity. RBBB with anterior ST abnormalities can occur. Prominent P waves (P pulmonale) suggest right atrial enlargement. See Fig. 13.3
- **CXR**—enlargement of the pulmonary artery and its major branches. Tapering of peripheral arteries. Enlarged RA and RV. Underlying disorder may be apparent
- **Bloods**—FBC, U&E, LFTs, ESR, arterial blood gases, thrombophilia screen, autoimmune profile
- **Echocardiography**—enlarged RV with septal flattening. Doppler estimate of pulmonary artery systolic pressure
- Further specialist investigations include:
 - High resolution CT scan
 - Lung perfusion scintigraphy
 - PFTs—particularly gas transfer
 - Hepatitis and HIV serology and viral titres
 - Exercise testing
 - Nocturnal oxygen saturation studies
 - Cardiac catheterization and pulmonary angiography after specialist advice—↑risk.

Box 13.3 Classification and causes of pulmonary hypertension***Pulmonary arterial hypertension***

- 1° pulmonary hypertension (sporadic/familial)
- Associated with connective tissue disease, portal hypertension, HIV, drugs/toxins, other.

Pulmonary venous hypertension

- Left-sided atrial or ventricular heart disease
- Left-sided valvular disease
- Extrinsic compression of central pulmonary veins.

Pulmonary hypertension associated with respiratory disease/hypoxaemia

- COPD
- Interstitial lung disease
- Sleep disordered breathing
- Alveolar hypoventilation disorders
- Chronic exposure to high altitude.

Pulmonary hypertension due to chronic thrombotic/embolic disease

- Thromboembolic obstruction of proximal pulmonary arteries
- Obstruction of distal pulmonary arteries—PE, *in situ* thrombosis, sickle cell.

Pulmonary hypertension due to pulmonary vascular disorders

- Inflammatory—schistosomiasis, sarcoidosis, other
- Pulmonary capillary haemangiomas.

Management

- Making the initial diagnosis of pulmonary hypertension is important but the actual cause may be difficult to identify quickly and is made after appropriate advice and investigation
 - The management of patients presenting *de novo* with pulmonary hypertension includes appropriate use of oxygen to correct hypoxaemia, anticoagulation, and diuretic therapy.
- Specialist advice is important, both for long-term management and for patients known to have pulmonary hypertension who present unwell. This is a difficult condition to treat for the non-expert.

Long-term management

- Lifestyle changes—graded exercise activities
- Anticoagulation with warfarin—INR 2.5
- Diuretics—often high doses of loop diuretics are needed
- Supplemental oxygen therapy.

Therapeutic options (according to the underlying cause)

- Vasodilator therapy (<10% of patients benefit, see Box 13.4)—high-dose calcium-channel blockers such as nifedipine (up to 240 mg/day) and diltiazem (up to 700 mg/day) are used
- Prostacyclins—continuous infusion of epoprostenol
- Endothelin receptor blockers, e.g. bosentan 125 mg BD
- Phosphodiesterase inhibitors, e.g. sildenafil, tadalafil
- Digoxin—to improve RV function
- Atrial septostomy
- Pulmonary thromboendarterectomy
- Heart–lung and lung transplantation.

Box 13.4 Vasodilator therapy in 1° pulmonary hypertension

During right heart cardiac catheterization, pulmonary haemodynamics are measured. Short-acting vasodilator therapy is used (inhaled nitric oxide, nebulized prostacyclin, or IV adenosine). A positive response is defined as a >20% reduction in mean pulmonary artery pressure or pulmonary vascular resistance without a decrease in cardiac output. Patients who respond and who have a cardiac index >2.1 L/min/m², and/or mixed venous oxygen saturation >63% and/or right atrial pressure < 10 mmHg should be considered for calcium-channel blockers.

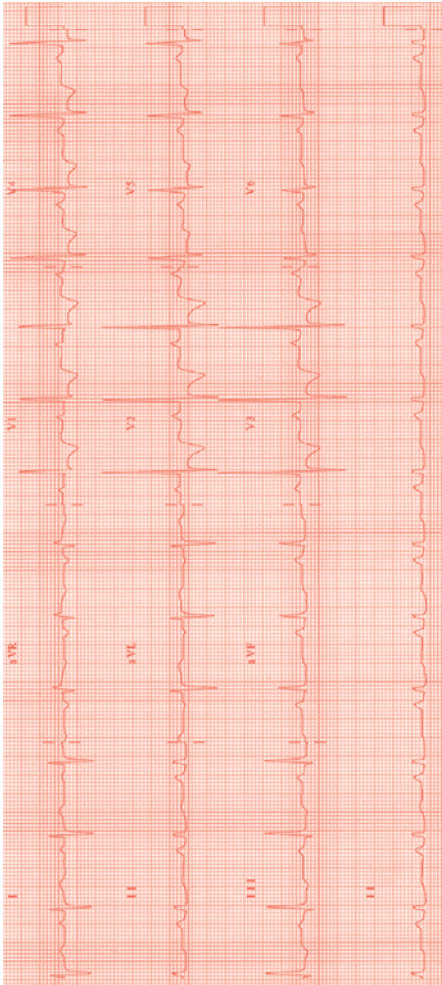


Fig. 13.3 ECG in chronic severe pulmonary hypertension. RV hypertrophy is demonstrated by right axis deviation, large R waves with T-wave inversion in leads V1–V3, and a prominent p wave (p pulmonale)

❓ **Cor pulmonale**

An alteration in the structure and function of the RV due to diseases affecting the lung or its vasculature. See Box 13.5 for causes.

Presentation

- Cor pulmonale usually has a chronic and slowly progressive course with symptoms of dyspnoea, cough, fatigue, and peripheral oedema
- Acute deterioration can occur with symptoms and signs of left and right heart failure
- Patients may be barrel-chested with distended neck veins, oedema, cyanosis, and physical signs of the underlying lung disease. Ascites can be seen.

Investigations

- **ECG**—sinus tachycardia, right-axis deviation, RV hypertrophy. Prominent P waves (P pulmonale) suggest RA enlargement. Atrial arrhythmias are common
- **CXR**—cardiomegaly, pleural effusions, pulmonary artery enlargement, pulmonary disease
- **Bloods**—FBC (polycythaemia), U&E, LFTs, BNP, arterial blood gases, ANAs (collagen vascular disease), tests for alpha-1 antitrypsin deficiency
- **Echocardiography**—enlarged RV with reduced right heart function. Septal flattening. Doppler estimate of pulmonary artery systolic pressure
- Further specialist investigations include:
 - PFTs
 - Lung perfusion scintigraphy or CTPA if PE suspected (📖 p.214)
 - Abdominal ultrasound to examine for hepatic engorgement and ascites.
 - Left and right heart catheterization (uncommon).

Management

Management of patients with cor pulmonale centres on improving oxygenation, RV contractility, as well as decreasing pulmonary vascular resistance and vasoconstriction. This is principally with oxygen and diuretics.

- **Oxygen therapy:**
 - As well as having a short-term acute symptomatic benefit, long-term oxygen therapy (at least 15 hours a day) improves survival in chronically hypoxaemic patients (PaO_2 of $<7.3\text{kPa}$)
- **Diuretics:**
 - Use loop diuretics such as furosemide 40–80 mg orally or IV in the acutely unwell
 - Some patients may respond to the addition of spironolactone 25–50mg PO
 - Particularly useful in RV volume overload
 - Excess volume depletion can lead to a decline in cardiac output
 - Watch renal function and K^+ levels.

- Vasodilators:
 - Not routinely used
 - There may be a role in specialist hands in patients with severe and persistent pulmonary hypertension despite adequate oxygen and bronchodilator therapy
- Digoxin:
 - Not routinely used
 - Studies have suggested a modest effect of digoxin on the failing right heart in cor pulmonale
- Theophylline:
 - Not routinely used
 - May improve LV and RV contractility and reduce pulmonary artery pressures
 - Reasonable to use in severe cases of cor pulmonale 2° to COPD.

Box 13.5 Causes of cor pulmonale

- The most frequent cause of cor pulmonale is COPD due to chronic bronchitis or emphysema
- Acute cor pulmonale can occur due to thromboembolic pulmonary disease
- Patients with COPD who develop cor pulmonale have a 30% 5-year survival.

This page intentionally left blank

Systemic emboli

Introduction	228
Causes	228
Presentation	228
Investigations	228
Management	228
Echocardiography	230
Paradoxical embolism	232

Introduction

Embolization of material, usually thrombus or vegetation, leading to signs and symptoms of obstruction of a coronary, cerebral or peripheral artery.

Causes

See Box 14.1 for causes.

Presentation

- TIA/stroke—common
- Acute ischaemia of a limb—painful, pulseless, pale, paralysis
- MI or ACS
- Acute small bowel ischaemia (superior mesenteric artery embolism)—abdominal pain, hypovolaemia, few abdominal signs
- Acute renal failure—rare.

Investigations

- ▶ Should be guided by history and examination
- FBC (anaemia, platelet count/clumping), U&Es
- ESR and D-dimer
- Coagulation screen
- ECG—AF, MI
- CXR—cardiomegaly
- CT head if stroke—to exclude haemorrhage, intracranial mass
- Carotid/peripheral artery Doppler ultrasound
- Doppler ultrasound of leg veins—DVT
- Echocardiography (📖 p.230)

Management

- Management of the presenting condition may be necessary before investigation of the source of embolism, e.g. acute limb ischaemia, small bowel ischaemia
- Patients should be anticoagulated if a cardiac source of embolism is demonstrated
- The use of early anticoagulation in embolic stroke is controversial and should be according to local policy
- PFO/ASD—device closure or surgery if appropriate.
- Patients with systemic embolus, DVT, and a PFO with contraindications to warfarin would be a good group for percutaneous PFO closure or IVC filter

Box 14.1 Causes of systemic emboli

- Carotid atheroma—common
- Left atrial thrombus—usually from the atrial appendage
 - AF
 - MS
 - Impaired atrial function
- LV thrombus—post infarct, cardiomyopathy, LV aneurysm, non-compaction
- Left heart valves:
 - Prosthetic (endocarditis, thrombosis)
 - Native (aortic stenosis, mitral stenosis)
- Cardiac shunt with paradoxical embolism:
 - ASD
 - PFO
 - Ventricular septal defect—with raised RV pressure
- Aorta:
 - Atheroma
 - Dissection (📖 p.189)
- Cardiac tumours (📖 p.352):
 - Myxoma
 - Other 1° and 2° tumours—rare.

Echocardiography

Echocardiography can be useful in the investigation of systemic emboli, to look for reduced LV function (predisposes to thrombus), apical LV thrombus, or a PFO—requires saline contrast.

Indications for TTE

- Unexplained systemic embolism
 - TTE is also indicated if there are clinical signs of endocarditis (📖 p.124) or myxoma (📖 p.350)
- ▶ In the absence of a cardiac history, ECG abnormalities, or clinical signs, TTE is unlikely to be useful

Indications for TOE

- Non-diagnostic TTE
- Endocarditis suspected and not confirmed on TTE
- Suspected prosthetic valve dysfunction
- Suspected PFO or ASD.

Indications for ICE

- Suspected right heart endocarditis/thrombus (e.g. on a pacemaker lead) and paradoxical embolus (see p.232), with a non-diagnostic TOE
- During interventional closure of PFO/atrial septal defect.

Saline contrast echocardiography

Can be performed with either TTE or TOE to look for a PFO.

- A small volume of normal saline (~5mL) is drawn into a 10 mL syringe, mixed with 1–2 mL air and agitated by passing it through a 3-way tap to another 10 mL syringe and back again, repeatedly for ~1 min
- Rapid injection during echocardiography imaging will assess evidence of right-to-left shunting
- In a normal study no bubbles should cross to the left heart—viewing the LA and RA is best for this. The study is positive if >3 bubbles are seen appearing in the LA within a few cardiac cycles of appearing in the RA (Fig. 14.1)
- The injection should be repeated using the Valsalva manoeuvre to increase RA pressure.
- False negatives may occur:
 - TTE due to poor image quality
 - TOE due to poor Valsalva manoeuvre and failure to increase RA pressure
- Injecting saline contrast via the femoral vein increases the diagnostic accuracy—blood is directed via the Eustachian valve towards the PFO
- If a TTE contrast study is positive, a TOE may be required to assess the atrial septum for suitability of device closure (Fig. 14.2).

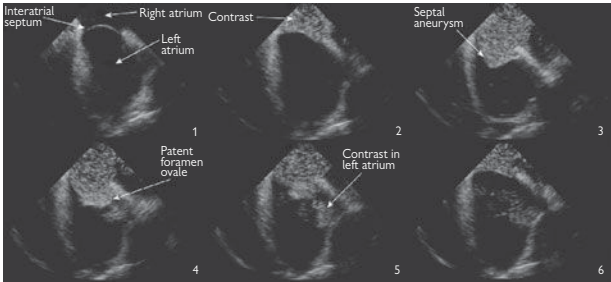


Fig. 14.1 Intracardiac echocardiogram demonstrating passage of agitated saline contrast from the RA through a PFO into the LA. The interatrial septum is aneurysmal.

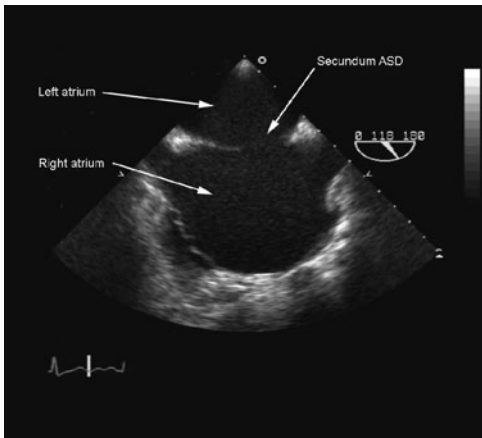


Fig. 14.2 TOE study demonstrating a large secundum ASD in a patient with a paradoxical embolism.

❗ Paradoxical embolism


Systemic embolism from the venous system crossing an abnormal communication within the heart (usually via an ASD or PFO)

- Approximately 15–20% of the normal population will have a PFO
- A PFO is also (or therefore) the commonest cardiac abnormality found in young patients with unexplained stroke
- For a PFO to cause a systemic emboli the following triad is required:
 - The presence of the PFO
 - Raised RA pressure—permanent or transient e.g. coughing, straining
 - Venous source of thrombosis—usually a DVT
- Treatment options where there is proven or presumed paradoxical embolism through a PFO or ASD include percutaneous device closure or lifelong anticoagulation. Trials to compare these treatments are ongoing
- See Fig. 14.3.

Box 14.2 Migraine with aura and PFO

- There is an ↑prevalence of PFO with right-to-left shunting in patients suffering from migraine, particularly those with associated aura—up to 50% of patients
- The unresolved question: *is this causal or coincidental?*
- Retrospective, non-randomized observational studies have indicated a reduction in frequency and severity of migraine in some patients following PFO closure
- Migraine with aura may be caused by paradoxical microembolization of air, thrombi, or vasoactive mediators normally filtered by the lungs
- The MIST trial (randomized, placebo using sham, controlled trial) however failed to show a significant benefit of PFO closure
- Further larger trials are underway

Weblink

- MIST trial results at the Migraine Action website:  <http://www.migraine.org.uk/index.php?sectionid=261>

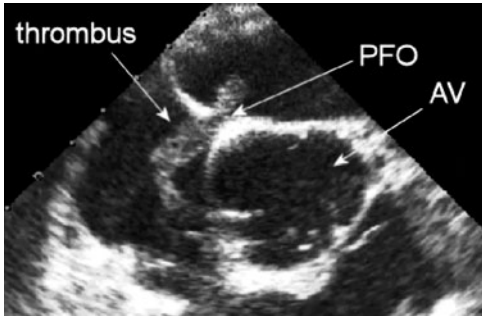


Fig. 14.3 TOE demonstrating a large thrombus trapped in a patent foramen ovale (PFO) close to the aortic valve (AV) in a patient with systemic embolism.

This page intentionally left blank

Cardiac issues in pregnancy

- Introduction and general principles 236
- Heart failure in pregnancy 238
- Hypertrophic cardiomyopathy 238
- Acute myocardial infarction in pregnancy 240
- Valvular heart disease in pregnancy 242
- Arrhythmias in pregnancy 244
- Aortic disease in pregnancy 246
- Hypertension in pregnancy 248
- Pulmonary embolism in pregnancy 250
- Anticoagulation in pregnancy 252

Introduction and general principles

► For patients with known cardiac disease, thorough preconception counselling should take place, to consider both short- and long-term risks to the mother and fetus. In some cases it may be appropriate to alter or stop treatment prior to conception (e.g. ACE inhibitors) or as soon as pregnancy is confirmed (e.g. warfarin). See Box 15.1.

Pregnancy may also be associated with new presentations of heart disease. It can unmask pre-existing conditions, exacerbate pre-existing conditions, and precipitate new conditions.

Death during pregnancy is rare (~1 per 50,000 pregnancies) but cardiac disease is the most common cause in the UK (e.g. cardiomyopathy, aortic dissection, MI, complications of pulmonary hypertension). Deaths due to cardiac disease are increasing in the UK, and the majority occur in women without known pre-existing disease. Vigilance to recognize and act upon new symptoms is therefore paramount.

► The management of pregnant patients with cardiac problems generally requires expert advice! See Box 15.2.

Normal physiological changes in pregnancy

One of the challenges in diagnosing pregnancy-related heart disease is to distinguish pathological features from adaptive changes in cardiovascular function. Circulating volume, heart rate, stroke volume, and consequently cardiac output increase markedly in the first 16 weeks, plateau, and then increase further in the weeks before term. Systemic vascular resistance is reduced during pregnancy.

The following are all consistent with normal pregnancy:

- Fatigue
- SOB
- Palpitation, re-entrant SVT
- Atrial and ventricular premature beats
- Raised JVP
- Pedal oedema
- Sinus tachycardia ~100 bpm
- Full volume, collapsing pulse
- S₃
- Systolic flow murmur.

Clinical indicators of pathological states

- Chest pain
- Severe dyspnoea
- Orthopnoea, paroxysmal nocturnal dyspnoea
- Sinus tachycardia >100 at rest
- AF/atrial flutter
- VT
- Hypotension
- Pulmonary oedema
- Pleural effusion.

Box 15.1 General principles of cardiac management

- Avoid drugs if possible, and use the fewest drugs in the smallest doses

but

- Do not deny appropriate management because of pregnancy
- In particular, do not withhold imaging involving radiation if the woman may have a life-threatening condition, e.g. PE, aortic dissection
- ► Remember, if the mother is compromised, so is the fetus
- ► Obtain EARLY advice from:
 - 'High-risk' obstetrician
 - Cardiologist with expertise in pregnancy.

Box 15.2 Particularly hazardous conditions in pregnancy

(Pregnancy should be avoided, and termination considered if occurs.)

- Significant pulmonary hypertension (40–50% maternal mortality)
- Cyanotic congenital heart disease
- Severe heart failure—NYHA class >2
- Severe cardiac dysfunction—LV ejection fraction <30%
- Severe AS or MS
- Marfan syndrome with a dilated aortic root (>4 cm).

❗ Heart failure in pregnancy

Accounts for 25% all cardiac deaths in pregnancy. Mortality is up to 10% where LV ejection fraction is $\leq 20\%$. Consider termination if heart failure occurs early in pregnancy.

Causes

- Dilated cardiomyopathy
- Underlying structural conditions e.g. valvular disease
- Peripartum cardiomyopathy.

Acute management

- Similar to other forms of heart failure—bed rest, oxygen
- Diuretics
- Vasodilators—hydralazine is safe in pregnancy
- ⚠ ACE inhibitors contraindicated until delivery (risk of renal agenesis). (There are however special circumstances where the benefits of ACE inhibitors outweigh their risks—consider on a case-by-case basis)
- Anticoagulation with LMWH
- Inotropes and IABP in severe situations
- β -blockade may be helpful if introduced cautiously—need fetal growth monitoring, and heart rate monitoring during delivery.

❓ Hypertrophic cardiomyopathy

- Generally a good outcome during pregnancy for both mother and fetus, including spontaneous vaginal delivery
- Some women may experience a deterioration in symptoms
- Prenatal counselling \pm family screening are important.

Management

- Maintain good fluid intake (the LV is stiff and responds poorly to dehydration) and avoid excessive fluid shifts as much as possible
- β -blockers for symptoms or outflow tract obstruction—but watch for fetal growth retardation
- Diuretics if fluid congestion/heart failure occur
- Epidural anaesthesia has been used successfully during labour and is probably safe in patients without outflow tract obstruction.

Box 15.3 Peripartum cardiomyopathy

Risk factors for development: very young/old age, twin pregnancy, hypertension, multiparous, African ethnicity.

Clinically indistinguishable from other dilated cardiomyopathies but, by definition, occurs only in the last month of pregnancy or up to 6 months' postpartum, *in the absence of any other cardiac pathology*. LV dysfunction persists in 50% and there is a significant risk of recurrence in subsequent pregnancies even when LV function has initially returned to normal. If LV function does not return to normal, the risk of death in any subsequent pregnancy is ~20%.

⊕ Acute myocardial infarction in pregnancy

Acute MI in pregnancy is rare, occurring in 1:10,000. Increasing incidence may be due to rising maternal age, ↑obesity, and ↑diabetes. However, mortality is high (around 5%), particularly if the infarct occurs late in pregnancy. Risk factors for pregnancy-related MI have been identified as hypertension, diabetes, smoking, transfusion, postpartum infection, thrombophilia, and age >30 years.

The pathology is usually atheromatous, although coronary artery dissection is more common in the pregnant state.

The diagnosis is made using conventional criteria (see 📖 p.44). Troponin I is not affected by normal pregnancy and is the marker of choice for myocardial necrosis in pregnancy.

Acute management

- There are few data to guide treatment. The risk from MI needs to be weighed against the risks of treatment (to both mother and fetus).
- ► Urgent cardiological assessment is essential
- Aspirin 75 mg OD
- β-blockers
- 1° PCI is the treatment of choice, since the consequences of not treating carry a high risk of both maternal and fetal death. This approach will also allow diagnosis and treatment of coronary artery dissection. Although there are little data on the use of newer antiplatelet agents in pregnancy, 1° angioplasty has resulted in the successful completion of pregnancies.

⚠ Systemic thrombolysis should not be given late in pregnancy because of the risk of premature labour and potentially catastrophic bleeding. However, in the presence of a large anterolateral acute MI, thrombolysis should be considered if 1° angioplasty is not available, since the consequence of not treating carries such a high risk of maternal and fetal demise.

This page intentionally left blank

② Valvular heart disease in pregnancy

Aortic stenosis

Usually due to a bicuspid aortic valve in the Western world; other parts of the world have a higher incidence of rheumatic fever. Patients are usually diagnosed pre-pregnancy. The ↑cardiac output required early in pregnancy can lead to problems due to the fixed LV outflow.

Symptoms include SOB, syncope, chest pain.

Management

Asymptomatic patients can be treated conservatively.

When symptoms occur with severe AS, and simple measures such as bed rest and cautious β -blockade fail, consider:

- Delivery (if gestation allows) and then treat the AS
- Palliative balloon valvuloplasty. This should be performed by an experienced operator after thorough assessment of the valve anatomy. Complications include acute severe AR, causing acute maternal decompensation, and the maternal and fetal risk of emergency aortic valve surgery is very high
- Surgical aortic valve replacement—rarely performed.

Mitral stenosis

Usually due to rheumatic disease, MS is often undiagnosed until unmasked by pregnancy. Mild or moderate MS is usually well tolerated. More significant disease may cause problems and patients are susceptible to the ↑heart rate (causing ↓diastolic filling time) and ↑circulating volume of pregnancy, both increasing LA pressure and which can precipitate acute pulmonary oedema. New or rapid AF will have similar effects.

Treatment (if SOB or heart failure occurs)

- Diuretics (avoid excessive diuresis—risk of hypovolaemia)
- β -blockers for rate control to allow time for ventricular filling
- Anticoagulate with heparin—if AF and/or LA dilatation
- Percutaneous (balloon) mitral valvuloplasty by an experienced operator for severe MS refractory to medical treatment.


Valvular regurgitation

MR and AR are generally well tolerated during pregnancy, and the decreased afterload is often beneficial in reducing the degree of regurgitation. When symptoms occur, diuretics are the mainstay of treatment. ACE-inhibitors should be avoided.

Antibiotic prophylaxis during labour

Antibiotic prophylaxis for valve disease during labour (to prevent infective endocarditis) is no longer required generally. See p.134 for more detail.

Box 15.4 Murmurs in pregnancy

Systolic flow murmurs are common during pregnancy due to the ↑cardiac output. An 'innocent' murmur should be typical for a flow murmur (soft, ejection systolic, aortic region/left sternal edge;  p.97), and without any other signs of valve disease. Diastolic murmurs, loud murmurs ($\geq 3/6$), thrills, and radiation of the murmur are not 'normal' and suggest a significant lesion, which requires echocardiography.

Who to refer for echocardiography

- Patients with a significant murmur that isn't clearly a flow murmur
- Anyone with other signs of valve disease
- Patients with significant breathlessness.

Arrhythmias in pregnancy

Hormonal and haemodynamic changes may predispose pregnant women to arrhythmias and may also render clinically silent paroxysmal tachycardias symptomatic. Acute treatment of the haemodynamically compromised patient should be the same as if non-pregnant. Note that DC cardioversion is safe in pregnancy (see Box 15.5).

Oral therapy (e.g. β -blockers) may be used to prevent recurrence during pregnancy if arrhythmias result in significant compromise.

Re-entry tachycardias (i.e. SVT)

Treat as for non-pregnant (📖 p.170):

- Vagal manoeuvres
- Adenosine, verapamil, and flecainide have been used successfully
- DC cardioversion for severe haemodynamic compromise

Atrial fibrillation/flutter

(See 📖 p.160 for general management.)

- Involve the cardiologist
- Anticoagulate with LMWH
- Rate control with β -blockers
- Patients will often revert to sinus rhythm spontaneously within 48 hours, and conservative treatment is usually appropriate, i.e. heparin and rate control
- Flecainide may be used for pharmacological cardioversion with caution; there is a potential risk of fetal toxicity (though not yet seen in humans), but there have been several reports of its safe use. (Dose: oral 50–150 mg BD; IV 2 mg/kg up to 150 mg total over 15 min.)
- Cardiovert if compromised
- Underlying cardiac disease is likely and should be investigated

Ventricular tachycardia

- DC cardioversion (Box 15.5)
- Requires further evaluation of underlying cause
- Subsequent management depends on underlying disease
- Involve cardiologist and high-risk obstetrician.

Box 15.5 DC cardioversion in pregnancy

- Place a wedge under the right hip to avoid IVC compression*
- Use lowest energy shock
- Direct the paddles away from fetus
- No reports of iatrogenic fetal VF
- ...**but** check fetal heart rate post-cardioversion.

*Procedures or investigations that usually require the patient to be supine should be done in a left lateral position or with the aid of a wedge to support the pelvis and avoid IVC compression, by the gravid uterus, with consequent syncope.

Aortic disease in pregnancy

The major concern is aortic dissection which is usually associated with underlying aortic disease.

Causes and associations

- Marfan syndrome (Box 15.6), especially with aortic root >4.0 cm (p.199). (Also Ehlers–Danlos type 4 and Loeys–Dietz syndrome)
- Turner's syndrome (assisted conception) or mosaic Turner's ~2% risk of dissection in pregnancy
- Aortic coarctation—whether repaired or not
- Bicuspid aortic valve with dilated aortic root. The risk of dissection in pregnancy is only slightly higher than in the general population.

General management

- Patients at risk should have preconception evaluation of the aorta with echocardiography and/or MRI
- Patients with previous aortic coarctation repair or other known aortic disease **must** have the aorta assessed for recoarctation or aneurysm formation (ideally with MRI) and monitored further during pregnancy
- Careful monitoring of BP throughout pregnancy is essential.
- β -blockers through pregnancy are advised to reduce the risk of root dilation—fetal monitoring scans are required
- Surgery for a dilated aorta is rarely undertaken because of the risk to the mother and fetus, but may be considered
- If aortic dilatation is present, Caesarean section should be undertaken to minimize haemodynamic stresses.

Acute aortic dissection in pregnancy

► See p.196 for general management. This is an emergency!

Additional factors in pregnancy:

- ► Urgent liaison between high-risk obstetrician and cardiologist
- During supine imaging use a pelvic wedge to prevent IVC obstruction. CT or MRI are the modalities of choice—MRI is ideal but not the best environment for a sick patient. Do not withhold investigations involving radiation (i.e. CT) because of pregnancy.
- BP control should be with β -blockers and hydralazine. Sodium nitroprusside risks fetal toxicity and should not be used
- Consider delivering the fetus—Caesarean section.

Box 15.6 Marfan syndrome in pregnancy

The major risk during pregnancy is aortic dissection (mostly of the ascending aorta)—hormonal and haemodynamic changes combine with the aortic wall changes in Marfan syndrome to increase the risk of new/further aortic dilation and of dissection in already dilated aortic roots. An ascending aortic dissection while pregnant is a catastrophic situation, with very high risk to the mother and fetus from the emergency cardiac surgery required, and should be avoided at all costs. The following is therefore advised:

- ► Women with Marfan syndrome and a dilated aortic root (>4.0 cm) are at significant risk of dissection and should be strongly advised against pregnancy, with good provision of suitable contraception. Termination should be offered if pregnancy occurs
- Women with Marfan syndrome and a non-dilated aortic root should be monitored closely during pregnancy, with very close attention to BP control, and regular imaging of the aortic root with echocardiography/CMR/CT. If dilation occurs, this a difficult situation and expert advice should be sought urgently

Hypertension in pregnancy

There are 3 broad types of hypertension in pregnancy (BP > 140 mmHg systolic or 90 mmHg diastolic):

🔗 **Chronic hypertension**

Control of chronic hypertension (i.e. diagnosed prior to or in early pregnancy) often requires an alteration to treatment and the hypertension may also deteriorate during pregnancy.

- Methyldopa is usually used for BP control—250 mg TDS PO initially, increasing to max. 1 g TDS
- β -blockers and calcium antagonists as 2nd-line agents
- ACE inhibitors are contraindicated in pregnancy and should be discontinued prior to conception.

🔗 **Gestational hypertension**

Gestational hypertension occurs late in pregnancy (last trimester). Its treatment is broadly similar to chronic hypertension, though may not require longer-term antihypertensive medication.

⚠️ **Pre-eclampsia**

Pre-eclampsia tends to occur in younger women after 20 weeks' gestation. Abrupt onset oedema and proteinuria with raised plasma uric acid distinguish pre-eclampsia from chronic hypertension. Resolution following delivery is the rule.

Management

- ▶ Obtain expert advice.

Severe cases

- Delivery of the fetus if gestational age allows. This resolves the problem and provides maximum safety for both mother and fetus
- Inpatient treatment for close monitoring of mother and fetus if delivery not planned
- Hydralazine (5–10 mg IV, repeated after 30 min in severe hypertension or infusion) or labetalol infusion (20 mg/hour, doubled every 30 min to max. 160 mg/hour)
- Avoid nitroprusside because of fetal toxicity
- Magnesium sulphate infusion to prevent convulsions—4 g (16 mmol) in 100 mL 5% dextrose over 10–15 min followed by 1 g/hour; concentration should not exceed 20%.

Mild cases

- May be managed at home but with twice-daily monitoring and rapid access to healthcare
- Methyldopa—250 mg TDS PO initially, increasing to max. 1 g TDS


🚑 **Eclampsia (fitting/seizure)**

- ▶▶ This is an emergency and needs urgent expert help
- Deliver the fetus—liaise with obstetricians
- Additional 2 g of magnesium sulphate over 10–15 min.

This page intentionally left blank

Pulmonary embolism in pregnancy

VTE is the 2nd commonest cause of maternal death, and poor management is implicated in many. Patients should be anticoagulated (with heparin) pending a confirmed diagnosis.

In general, investigation and management is the same as for a non-pregnant patient (see  p.214). Specific issues in pregnant women are indicated here:


Investigations (p.216)

- Appropriate investigations should not be withheld because of pregnancy. CTPA and perfusion scans carry a low risk to the fetus
- D-dimers may be raised in a normal pregnancy, but normal D-dimers make a PE unlikely.

Acute management (p.218)

- LMWH should be used but altered pharmacokinetics in pregnancy mean that doses are ↑ compared to the non-pregnant state. Give enoxaparin 1 mg/kg BD
- For life-threatening massive PE, consider (after specialist advice) intra-pulmonary thrombolysis, catheter (percutaneous) disruption of embolus, or surgical thrombectomy.

Ongoing management

- Anticoagulation is important—see  p.250 for options during pregnancy
- Where embolic episodes continue despite therapeutic anticoagulation, consider a temporary caval filter.

This page intentionally left blank

Anticoagulation in pregnancy

Anticoagulation in pregnancy, particularly for prosthetic valves, presents a difficult problem, with few data available for guidance. Warfarin risks teratogenicity (1st trimester), fetal haemorrhage (especially in 3rd trimester), and fetal loss throughout pregnancy. Heparin use has been implicated in prosthetic valve thrombosis. LMWH is preferred to UFH, because anti-Xa levels can be monitored and it has a longer half-life so levels are more stable. It should be given as a BD regimen.

- For most women, warfarin should be discontinued once pregnancy is confirmed, and LMWH started (e.g. enoxaparin 1 mg/kg BD)
- For women at greatest risk of thrombosis—i.e. those with mechanical valves—there is no perfect regimen: the interests of the mother and fetus are in conflict. If LMWH is used, anti-Xa levels **must** be monitored and maintained >1.0 IU/mL
- The 3 main options are:
 - LMWH plus aspirin throughout pregnancy
 - Warfarin throughout pregnancy, changing to heparin at 38 weeks
 - LMWH plus aspirin in 1st trimester, changing to warfarin until 38 weeks when heparin is recommenced.
- ► Specialist advice should be sought from haematologist, cardiologist, obstetrician, and obstetric anaesthetist, and decisions made after consideration of case-specific issues.
- Delivery requires careful planning to reduce the risk of intra- and post-partum haemorrhage and valve thrombosis.

Adult congenital heart disease

- Introduction 254
- Atrial septal defect 256
- Ventricular septal defect 258
- Atrioventricular septal defect 260
- Patent ductus arteriosus 260
- Aortic coarctation 262
- Transposition of the great arteries 264
- Congenitally corrected transposition of the great arteries 268
- Tetralogy of Fallot 270
- The single ventricle 272
- The patient after Fontan operation 274
- The cyanosed patient 276
- Eisenmenger syndrome 278
- Arrhythmias 280
- Syncope 282
- Heart failure 284
- Glossary of common surgical procedures 286

Introduction

Congenital heart disease occurs in ~0.8% of newborn infants. There are currently ~250,000 adults with congenital heart disease (ACHD) in the UK and a worldwide *annual* incidence of 1.5 million. These numbers are growing as more children survive to adulthood, and this has important implications for physicians practising in adult medicine.

Common presentations in emergency situations include:

- Arrhythmia
- Heart failure
- Endocarditis

—all potentially with high morbidity and mortality.

The diagnostic and therapeutic approach towards emergencies in ACHD is not necessary identical to the approach towards patients with acquired cardiac disease. Special expertise and input may be required for optimal management.

This page intentionally left blank

Atrial septal defect

An ASD is a direct communication between the atria that permits blood flow (usually from LA to RA—see Fig. 16.1). There is consequent enlargement of the RA and RV and ↑pulmonary blood flow. Many can remain asymptomatic for decades.

The unoperated patient

Clinical features result from:

- ↑pulmonary blood flow
- Inability to increase cardiac output adequately because of the systemic-to-pulmonary shunting
- Paradoxical thrombembolism
- AF or atrial flutter, related to RA dilatation.

Presentation

- Many are asymptomatic
- Symptomatic adults usually present with SOB or palpitation, age 20–40
- May present as an emergency with stroke, heart failure, or fast AF.

Signs

- Fixed splitting of the S₂
- Pulmonary ejection murmur due to ↑flow
- Rarely—cyanosis, i.e. Eisenmenger syndrome. Occurs at a late stage in large defects, if pulmonary hypertension has occurred.

Investigations

- CXR—cardiomegaly, RA dilatation, and prominent pulmonary arteries are common with large shunts
- ECG:
 - Right axis deviation and incomplete RBBB are typical findings in patients with significant defects
 - Atrial arrhythmia—AF, atrial flutter, SVT.

Management

- Emergencies are very rare. Acute management of stroke, heart failure, or AF as in the non-ACHD setting
- An ASD that causes RA and RV enlargement should be closed either surgically or with a percutaneous technique irrespective of symptoms. This does not need to be done urgently however
- Patients with cryptogenic TIA or stroke with either an ASD or PFO would also benefit from elective closure of the defect
- Small ASDs without chamber enlargement may not need intervention.
- If large defect with established pulmonary hypertension, cyanosis ± Eisenmenger syndrome, closure may be too hazardous.

The operated patient

After ASD closure, patients are usually symptom free. However, they can present with atrial arrhythmias and heart failure especially when the defect has been closed late in life and the pulmonary artery pressure elevated prior to surgery. Complete heart block or sinus node dysfunction can also occur after closure.

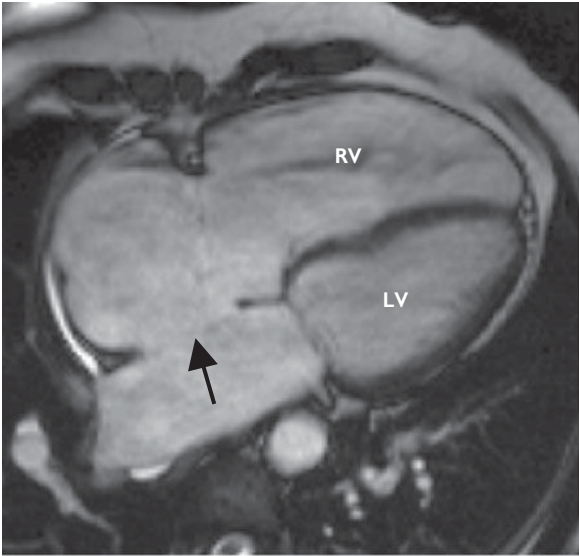




Fig. 16.1 CMR image of an ASD. Note the partial absence of atrial septum (arrowed) and the dilated RV.

Ventricular septal defect

A VSD permits blood flow between the ventricles (usually from left to right) leading to an increase in pulmonary blood flow and enlargement of the LA and LV. The size of the VSD and the pulmonary vascular resistance determine the degree and direction of the shunt (see Box 16.1).


The unoperated patient—problems

- Pulmonary hypertension if large defect (significant left-to-right shunt); may become permanent due to chronic pulmonary vascular changes
- Cyanosis occurs when ↑pulmonary vascular resistance eventually leads to a right-to-left shunt (see  Eisenmenger syndrome, p.278), or where a large VSD allows mixing of arterial and venous blood
- Heart failure from LV dysfunction due to long-term volume overload
- Atrial and ventricular arrhythmias due to chamber enlargement
- AR (see p.104), even with small VSDs, due to the potential proximity of the defect to the aortic valve
- ↑risk of endocarditis—all patients with VSDs
- Pregnancy is usually well tolerated in patients with a small or moderate VSD but carries a high risk in patients with pulmonary vascular disease ( Eisenmenger syndrome, p.278)

Acute presentation

Endocarditis, atrial and ventricular arrhythmias, or heart failure.

Signs

- Coarse pansystolic heart murmur at left sternal border ('the louder the VSD murmur, the smaller the defect')
- LV ± RV heave
- Cyanosis if Eisenmenger syndrome has developed ( p.278)

Investigations

- CXR—normal (small defect), cardiomegaly, ↑pulmonary markings (moderate defect), oligemic lung fields, enlarged proximal pulmonary arteries (large defect with Eisenmenger syndrome)
- ECG—broad P wave, signs of LV enlargement or RV hypertrophy (Eisenmenger syndrome), arrhythmia.

Management

- Acute presenting problems managed as in the non-ACHD setting
- Nearly all VSDs should be closed to alleviate LV enlargement, prevent the development of irreversible pulmonary artery disease, and to reduce the risk of AR and bacterial endocarditis (exception: small uncomplicated VSDs).

The operated patient

- Usually symptom free but can present with atrial or ventricular arrhythmia or heart failure, especially when the defect has been closed late in life and the pulmonary artery pressure has been elevated
- Complete heart block can occur after closure
- Pulmonary vascular disease can progress, regress, or remain stable postoperatively.

Box 16.1 Restrictive and non-restrictive VSD

Restrictive VSDs 'restrict' the flow across the defect. They are thus small ($<1/3$ of the aortic root diameter), and there is a pressure gradient between the LV and RV. RV pressures and pulmonary resistance are normal.

Moderately restrictive VSDs are about half the size of the aortic root, with moderate–severe shunting early in the disease process. RV pressures are \uparrow , but not to systemic levels. Pulmonary resistance can be raised, and the LA and LV can be dilated due to volume overload.

Non-restrictive VSDs are large, resulting in equal LV and RV pressures. The pulmonary circulation is subject to systemic pressure and significantly \uparrow flow, which leads to \uparrow pulmonary resistance within the 1st years of life. This reduces the left-to-right shunt and continued pulmonary vascular changes ultimately result in reversal of the shunt (right-to-left) and Eisenmenger syndrome (see p.278).

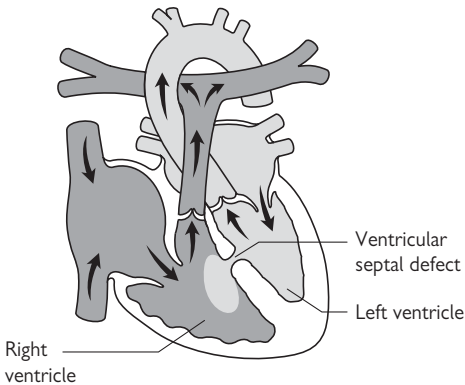


Fig. 16.2 Diagram of a VSD.

Atrioventricular septal defect

The term AVSD covers a spectrum of anomalies at the junction between the atria and ventricles (Fig. 16.3):

- The defect can consist only of an ASD (ostium primum) or can include an inlet-type VSD, which can be restrictive or non-restrictive
- Additionally, the AV valves (mitral and tricuspid) are often abnormal and can be regurgitant
- AVSDs occur in 35% of patients with Down syndrome

Physiological consequences

- Generally similar to the condition of an isolated ASD or VSD and relate to the degree of left-to-right shunting and the presence or absence of pulmonary hypertension
- The abnormality of the AV valves can result in additional problems, including heart failure and atrial arrhythmia.

Repair

Following AVSD repair, potential problems include left or right AV valve regurgitation or stenosis, subaortic stenosis and complete AV block.

Patent ductus arteriosus

- A PDA represents a persistent communication between the descending aorta and the proximal left pulmonary artery (Fig. 16.4)
- There is a left-to-right shunt with ↑pulmonary flow leading to enlargement of the LA and LV
- Small ducts cause a murmur without haemodynamic effects
- Large ducts lead to pulmonary hypertension and pulmonary vascular disease, ultimately resulting in Eisenmenger syndrome and a right-to-left shunt across the PDA into the *descending* aorta. This results in differential cyanosis—reduced lower body oxygen saturations with maintained upper body saturation.


Signs

Continuous (systolic and diastolic) murmur at upper left sternal border; long ejection systolic murmur with small PDAs.

Acute presentation

Rare—endarteritis (like endocarditis) is the main cause.

Management

- Endarteritis managed as for endocarditis in the non-ACHD setting (see  p.128)
- Closure of PDA is indicated if left heart enlarged or when a murmur is present (to reduce the small risk of endarteritis).

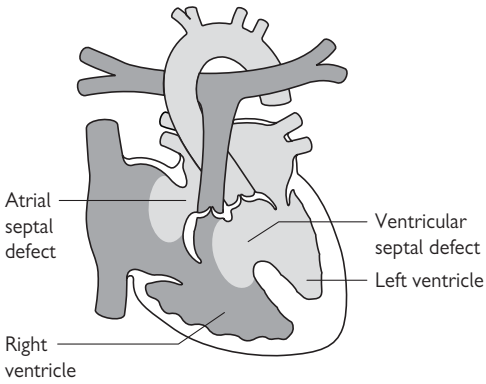


Fig. 16.3 Diagram of an AVSD.

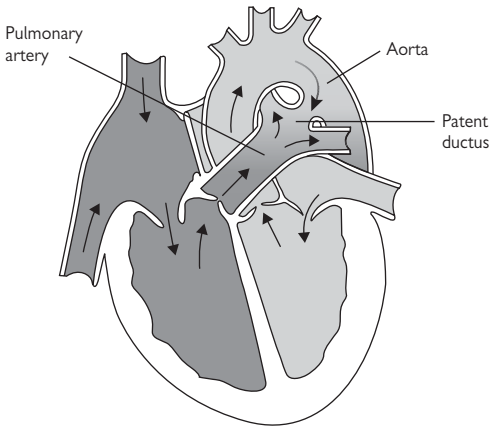


Fig. 16.4 Diagram of a PDA.

Aortic coarctation

Aortic coarctation is a narrowing of the aorta just distal to the left subclavian artery, adjacent to the ligamentum arteriosum (Fig. 16.5). If severe, the lower body relies on collateral vessels via the intercostal arteries for perfusion. Complete occlusion is also possible. A 'simple' coarctation is one without other cardiac lesions. A 'complex' coarctation is associated with other defects (e.g. VSD or aortic stenosis). At least 50% of patients with coarctation have a bicuspid aortic valve.

The unoperated patient

Risks

- Upper body hypertension
- Heart failure from long-standing LV pressure load
- Aortic rupture or dissection
- Infective endocarditis
- Stroke from an associated ruptured berry aneurysm + hypertension
- Premature coronary artery disease.

Signs

- Upper limb hypertension and differential arm–leg pulses. BP measurement in the right arm and a leg is necessary in all new patients with hypertension). A pressure difference of ≥ 30 mmHg may suggest coarctation
- Continuous murmur in the interscapular region.

Investigations

- ECG—LV hypertrophy
- CXR—the '3 sign' caused by narrowing of the aorta at the site of coarctation with dilatation of the vessel before and after the coarctation; 'rib notching' caused by erosions of the inferior edge of the ribs by enlarged intercostal arteries
- CT—good visualization of location and severity
- MRI—excellent visualization of anatomy, possible aneurysm formation and 3D visualization of the geometry and collaterals using contrast angiography. Velocity measurements can assess the degree of stenosis.

Management

- Acute consequences managed as in the non-ACHD setting
- Haemoptysis requires urgent aortic imaging with CT or MRI and referral to a tertiary centre as it may herald aortic dissection and/or rupture of a paracoarctation pseudoaneurysm
- Surgical repair or stenting of the stenosis may be indicated if significant gradient across coarctation (>30 mmHg) \pm proximal hypertension.

The operated patient

- Recoarctation and aneurysm formation (often intercostal) at the site of repair are not uncommon; aneurysm rupture presents acutely!
- Other aortic wall complications are frequent
- Hypertension can persist or develop in adulthood and needs to be treated aggressively because of the risk of atherosclerosis

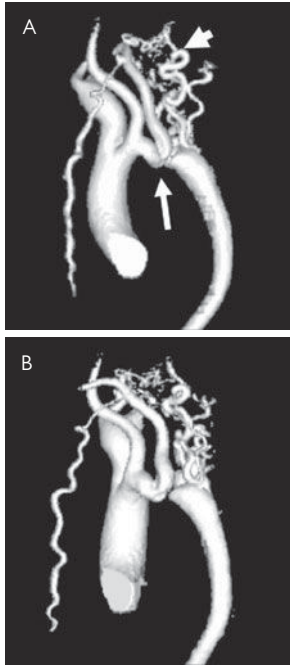


Fig. 16.5 Magnetic resonance angiogram of aortic coarctation. Top: AP view showing site of coarctation (long arrow), enlarged head and neck vessels and extensive collateral circulation to the descending aorta (short arrow) Bottom: slightly rotated view showing complete nature of coarctation.

Transposition of the great arteries


The unoperated patient

The great vessels arise from the wrong ventricle—the aorta from the RV and the pulmonary artery from the LV (Fig. 16.6). Thus systemic blood cannot pass to the lungs for oxygenation. When born, infants are totally dependant on a PDA, and thus need surgery within a few days before this closes, so unoperated patients do not exist in adult life!


Can be associated with other lesions, e.g. VSD or coarctation.

Surgical options

Atrial switch operation

- The most common operation amongst current adults
- Atrial blood flow is redirected with a baffle so that the LV receives systemic venous blood (and pumps to the lungs); while the RV receives pulmonary venous blood (and pumps into the aorta). The disadvantage is that the RV remains the systemic ventricle. There are 2 types—either the Mustard or Senning operations, depending on the material used to create the baffle (see  p.288).

Arterial switch operation

The 'atrial switch operation' has in more recent years been replaced by the 'arterial switch operation' in which the aorta and pulmonary artery are switched to the anatomically correct position, with the LV connected to the aorta and the RV to the pulmonary artery (the LV becomes the systemic ventricle) (see  p.286).

The patient after 'arterial switch operation'

- Arrhythmias are less common and ventricular function is usually well preserved
- Suture lines in the pulmonary trunk can cause stenosis
- Peripheral pulmonary artery stenosis can be caused by the position of the pulmonary bifurcation anterior to the ascending aorta
- Progressive dilatation of the aortic root (former pulmonary root) can cause neo-aortic valve regurgitation
- Coronary artery reimplantation may result in ostial coronary stenosis and myocardial ischaemia.

Signs

- Ejection systolic heart murmur from pulmonary artery stenosis
- Diastolic heart murmur from AR.

Investigation

ECG—typically normal, less often signs of myocardial ischaemia and RV hypertrophy

Management

The main issue in the care of patients after arterial switch operation is to exclude significant pulmonary artery stenosis, myocardial ischaemia, and aortic valve regurgitation. All these situations may warrant intervention.

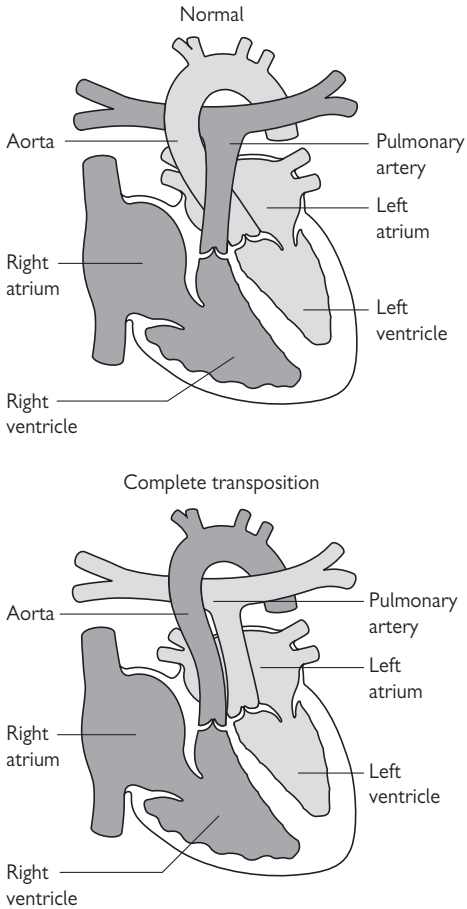


Fig. 16.6 Diagram illustrating TGA.

The patient after 'atrial switch operation'

- There is a significant morbidity from arrhythmia related to extensive atrial surgery: bradyarrhythmias (sinus node dysfunction, slow junctional escape rhythm) and tachyarrhythmias (atrial flutter and AF) occur
- RV dysfunction is common (40%), as it struggles to support the systemic circulation
- TR can accompany right heart failure
- Obstruction of the atrial pathways ('baffle obstruction') can lead to systemic or pulmonary venous congestion.

Signs

- Systolic heart murmur from TR
- Heart failure
- Peripheral oedema and ascites from systemic venous congestion.

Investigations

- ECG—sinus bradycardia or junctional escape rhythm, right axis deviation, RV hypertrophy, atrial arrhythmias
- CXR—cardiomegaly, pulmonary congestion, narrow vascular pedicle.

Management

- ► This requires a specialist centre due to the complexity of arrhythmia management, including pacing, and the difficulty in assessing RV function
 - Thorough assessment of RV and tricuspid valve function, heart rhythm, and the function of the intra-atrial venous pathways is paramount
 - Therapeutic options include catheterization techniques (balloon dilatation and stenting for pathway obstructions) and surgical procedures (tricuspid valve repair/replacement or even conversion to the arterial switch operation, for selected patients)
 - The end of the therapeutic spectrum is heart transplantation.
- ❗ If pacing is required for bradycardia, this must be performed by experts, as placement of the leads within the atria and into the left (pulmonary) ventricle can be immensely difficult.


This page intentionally left blank

Congenitally corrected transposition of the great arteries

In ccTGA the ventricles are 'inverted'. Systemic venous return enters the LV which then ejects into the pulmonary artery. Pulmonary venous return enters the RV which fills the aorta. The circulation is therefore 'physiologically corrected' but the RV is supporting the systemic circulation.

ccTGA is often associated with other defects, e.g. systemic (tricuspid) AV valve abnormalities and regurgitation, VSD, subpulmonary stenosis, and complete heart block. ccTGA can occur with dextrocardia.

The unoperated patient

- Progressive RV dysfunction is common as it is not designed to support the systemic circulation
- Risk of bradyarrhythmias (complete AV block) and tachyarrhythmias (atrial arrhythmia or SVT 2° to WPW syndrome,  p.174)
- Patients with a VSD and PS can be cyanotic

The operated patient

Patients may have been operated for their associated lesions. Common procedures are:

- VSD closure
- Implantation of a conduit from the LV to the pulmonary artery
- Systemic (tricuspid) AV valve replacement.

A 'corrective procedure' would be the 'double switch operation' (combination of an atrial and arterial switch operation). As for atrial switch operations, atrial arrhythmias are common following this.

Signs

Systolic heart murmur—VSD, PS or TR may be difficult to differentiate.

Investigations

- ECG—arrhythmia (complete AV block, atrial arrhythmia), Q wave in V1 and V2, and absent Q wave in V5 and V6 (not to be mistaken for previous MI)
- CXR—dextrocardia (20% of patients), cardiomegaly.

Management

- Preservation of systemic (right) ventricular function is crucial
- Systemic (tricuspid) AV valve regurgitation has to be treated surgically (i.e. valve repair/replacement) before ventricular dysfunction becomes irreversible
- Symptomatic bradycardia or chronotropic incompetence is an indication for pacemaker implantation
- Atrial arrhythmias are common after atrial surgery or with severe TR. They are not well tolerated in the setting of a systemic RV, especially with dysfunction and TR.

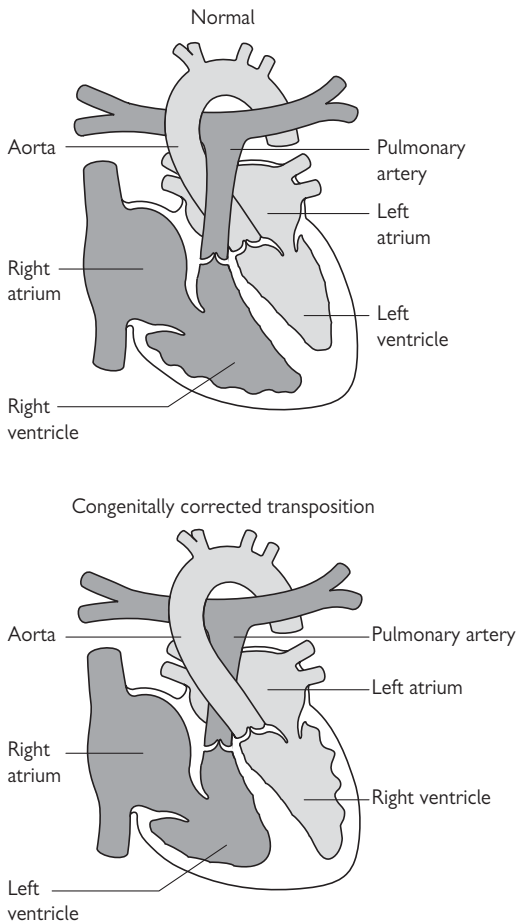


Fig. 16.7 Diagram illustrating ccTGA.

Tetralogy of Fallot

ToF consists of:

- A large VSD
- Right ventricular outflow tract obstruction
- RV hypertrophy
- An over-riding aorta (see Fig. 16.8)

The physiological consequences are determined by the degree of RVOTO which in turn determines the magnitude of pulmonary blood flow. Significant RVOTO leads to a right-to-left shunt and cyanosis. Survival to adulthood in unoperated patients with ToF is rare.

The operated or repaired patient

- Surgical repair includes VSD closure and relief of the RV outflow obstruction, which may involve patching of the pulmonary valve annulus
- The commonest problem is PR from the enlarged pulmonary outflow tract, but (re)stenosis can also occur
- The majority of patients tolerate the regurgitation well, but RV enlargement and dysfunction is associated with VT and sudden death
- Atrial arrhythmias are not uncommon, especially if RA enlargement is present.

Signs

Parasternal RV heave (RV dilatation), diastolic murmur (PR or AR), systolic murmur (residual RVOTO or VSD).

Investigations

- ECG—complete RBBB, QRS prolongation (QRS duration >180 ms is a prognostic marker for sustained VT and sudden death)
- CXR—cardiomegaly, dilatation of ascending aorta.

Management

- Most patients are minimally symptomatic
- RV dysfunction and/or severe dilation may require pulmonary valve replacement. New percutaneous techniques, using stent-mounted pericardial valves, are increasingly common for selected patients
- The development of arrhythmias (VT and atrial flutter/AF) warrants both full electrophysiologic assessment and thorough review of the haemodynamics.

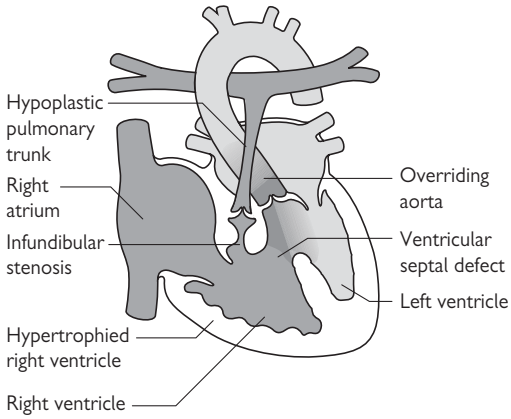



Fig.16.8 Diagram illustrating ToF.

The single ventricle

In some of the most severe forms of congenital heart disease, there may be only 1 ventricle, either 'anatomically' or 'functionally' (i.e. a small vestigial ventricle also exists). The single ventricle can be of LV or RV morphology and receives both systemic and pulmonary venous blood and pumps blood into both the pulmonary artery (when not atretic) and the aorta (Fig. 16.9)



The clinical presentation of patients with univentricular hearts is determined by the degree of pulmonary blood flow and the presence of associated lesions. The best situation is when blood flows unrestricted into a well-functioning ventricle, which pumps an equivalent amount of blood into the lungs and systemic circulation. In this situation, excessive pulmonary blood flow is avoided by an obstruction of the pulmonary outflow tract. If pulmonary outflow tract obstruction is not present, excessive blood flow into the lungs will lead to pulmonary hypertension and the Eisenmenger syndrome (see  p.278).

Severe pulmonary outflow tract obstruction with reduced pulmonary blood flow causes cyanosis.

Surgery in patients with single ventricles is always palliative and aims to secure adequate pulmonary and systemic blood flow and maintain systemic ventricular function.

Surgery for single ventricles

- Aortopulmonary shunts are commonly performed in early infancy to improve pulmonary blood flow. As the single ventricle continues to pump blood into both the aorta and pulmonary arteries, volume overload remains a problem
- Pulmonary artery banding is performed when pulmonary blood flow is unobstructed, to protect against pulmonary hypertension

Systemic venous-to-pulmonary artery connections such as the Glenn shunt ( p.288) or the Fontan operation ( p.286) are performed as definitive palliations to improve pulmonary blood flow and separate the pulmonary from the systemic circulation while unloading the systemic ventricle.

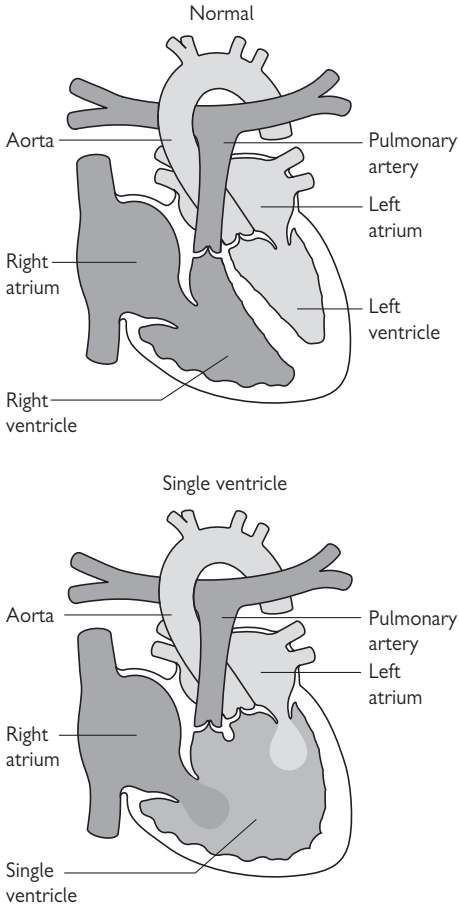


Fig. 16.9 Diagram showing a normal (2-ventricle) heart and a heart with effectively a single ventricle.


The patient after Fontan operation

Many adult patients with a single ventricle have undergone Fontan operations (p.286). Following this operation, all systemic venous return is diverted to the pulmonary circulation without employing a subpulmonary ventricle. Blood flow to the lungs, therefore, is only driven by systemic venous pressure. 'Fontan patients' are at risk of various complications related to surgery and/or the abnormal circulatory physiology persisting after surgery.

Complications after Fontan operation

Arrhythmias

- Sinus node dysfunction may warrant pacemaker implantation
- Atrial flutter/fibrillation related to scarring from surgery, or to atrial distension from high venous pressure

 Atrial arrhythmias in Fontan patients need prompt treatment as they can cause profound haemodynamic deterioration

Thromboembolism

Associated with sluggish venous blood flow.

Protein-losing enteropathy

PLE occurs in 10% of 'Fontan patients' and is characterized by intestinal protein loss → low serum protein levels and subsequently to peripheral oedema and ascites.

Deterioration of ventricular function

This is the 'natural' history, especially if the ventricle is of RV morphology.

Hepatic dysfunction

Resulting from high hepatic venous pressure.

Cyanosis

From persistent right-to-left shunting.

Signs

- A 'good' Fontan patient has no murmurs and a single S₂ (systolic murmurs can indicate AV valve incompetence)
- Peripheral oedema—heart failure or PLE.

Investigations

- ECG—arrhythmia
- CXR—cardiomegaly, atrial enlargement
- Bloods—abnormal LFT, low protein/albumin suggestive of PLE.

Management

- 'Fontan patients' are one of the most challenging group of patients in cardiology and require close follow-up by tertiary centre specialists
- Treatment aims to maintain optimal pulmonary and systemic circulation and to preserve ventricular function.
- Avoid dehydration—patients are very susceptible

This page intentionally left blank

The cyanosed patient

Cyanosis is common in ACHD 2° to right-to-left shunting or ↓pulmonary blood flow. The resulting hypoxaemia leads to adaptive mechanisms to increase oxygen delivery to the tissues. These include a rightward shift in the oxyhaemoglobin binding curve and ↑haemoglobin concentration (2° erythrocytosis, not polycythaemia).

Symptoms related to hypoxia include SOB at rest or on exertion and chest pain. Other symptoms result from the multiorgan consequences:

The multi-organ consequences of cyanosis

Haematological

- Erythrocytosis (2°) without polycythaemia
- Iron deficiency (high demand, dietary, or induced by inappropriate venesections); often missed as MCV can be normal and haemoglobin is above upper normal limit. Look for serum ferritin in a stable patient or transferrin saturation to establish whether iron deficiency is present, and treat with iron supplementation
- Coagulopathy, bleeding diathesis, thrombocytopenia, impaired clotting function.

Neurological

Brain injury from paradoxical embolism, haemorrhage, abscesses.

Renal

- Hypoxaemia-induced glomerulopathy—haematuria, proteinuria
- Nephrolithiasis—uric acid.

Rheumatological

- Gout
- Osteoarthropathy.

Management

Venesection in cyanosed patients—only if:

Severe symptoms of so called ‘hyperviscosity syndrome’ (e.g. headache, dizziness, fatigue, visual disturbances, tinnitus and myalgia) are present after ‘correcting’ dehydration and iron deficiency (symptoms of the latter mimic symptoms of ‘hyperviscosity syndrome’).

Venesection procedure

- 250–500 mL of blood to be removed over 45 min
- Volume replacement with 5% dextrose
- Use IV ‘air filters’—to reduce the risk of systemic air embolus
- BP and heart rate monitoring are required.

Iron deficiency

Needs oral or IV iron supplements.

Anticoagulation

No general consensus on routine anticoagulation, though a stronger case exists in the presence of pulmonary arterial hypertension; requires specialist consideration.

This page intentionally left blank

② Eisenmenger syndrome

Eisenmenger syndrome is a pathophysiological condition resulting from ACHD. Uncorrected left-to-right shunting and progressive pulmonary hypertension eventually leads to reversal of the shunt and cyanosis when right-sided pressure exceeds systemic. VSD, AVSD, and large PDAs are responsible for 80% of cases. Eisenmenger patients exhibit signs and symptoms related to chronic cyanosis (see 📖 p.276) and are at risk of complications related to pulmonary hypertension (see 📖 p.220).

Signs

- Cyanosis
- Loud S₂
- No murmur from original lesion.

Investigations

- ECG—RV hypertrophy
- CXR—oligaemic lung fields, enlarged proximal pulmonary arteries.

Acute presentation

- Progressive heart failure
- Atrial arrhythmias
- Angina
- Syncope and SCD
- Haemoptysis and intrapulmonary bleeding
- Pulmonary artery thrombosis—usually *in situ* thrombosis and not thromboembolic.

Management

Also see Box 16.2.

Haemoptysis/intrapulmonary bleeding

- Bed rest
- CXR and CT scan to determine extent of haemorrhage
- FBC—repeatedly if continuous bleeding is suspected
- Monitoring of oxygen saturation, BP, diuresis
- Embolization of culprit vessels identified by angiography.

Anticoagulation

- To prevent recurrent embolic events
- No general consensus on routine anticoagulation—bleeding diathesis.

Treatment of pulmonary hypertension

Advanced therapies such as prostacyclin analogues, endothelin antagonists, phosphodiesterase inhibitors, and bosentan (a dual endothelin antagonist) have been shown to reduce pulmonary vascular resistance and improve symptoms in patients with Eisenmenger syndrome, similarly to patients with idiopathic pulmonary hypertension. Stable patients with functional class III should therefore be considered for advanced therapy, once iron deficiency—if present—is corrected.

Box 16.2 Rules in the care of Eisenmenger patients

- Avoid *hypovolaemia* and *dehydration*
- Avoid *non-cardiac surgery* and *GA* if possible; when *GA* and surgery are necessary, experienced personnel should be directly involved
- Postoperative care in *ICU*
- Use IV 'air filters' or 'bubble trap' for any IV line
- Good contraceptive advice and avoidance of pregnancy
- Avoid strenuous exercise and competitive sports, but encourage low-grade regular physical activity, within patient's ability
- Consider endocarditis prophylaxis
- Annual immunization against influenza and pneumococcal infections.

❗ **Arrhythmias**

Arrhythmias are common in ACHD as part of the 'natural' history, residual haemodynamic lesions, or resulting from surgery. Arrhythmias in these patients are associated with significant morbidity and mortality and their detection and treatment can be challenging.

❗ **Atypical atrial flutter and intra-atrial re-entry tachycardia**

Usually caused by atrial stretch or previous extensive atrial surgery (Fontan, Mustard, Senning). Intra-atrial excitation circuits around electrical barriers such as scars and suture lines cause rapid atrial heart rate or flutter. AV conduction may be normal in relatively young adults, allowing for a fast 1:1 conduction and a fast ventricular rate leading to haemodynamic compromise.

Treatment

Chemical cardioversion is not often successful. Consider early (same day!) electrical cardioversion for all subjects. Amiodarone, IV β -blockade, and IV diltiazem are the most frequently used rate-control agents (while organizing cardioversion/anticoagulation). Low threshold for TOE to exclude clot. Radiofrequency ablation can block the circuits and potentially treat the arrhythmia. Electrophysiologists with special expertise in CHD are required for these demanding procedures.

⚠️ **Ventricular tachycardia**

VT is commonly associated with previous ventricular surgery or long-standing abnormal ventricular load:

- Previous VSD closure
- ToF repair—prolonged QRS duration is a risk marker
- PR and RV enlargement
- Single ventricles
- Mustard or Senning repairs; Rastelli operation
- ccTGA
- Eisenmenger syndrome.

Treatment

Identifying and treating the culprit haemodynamic lesion is an integral part of arrhythmia management in these patients. Indications for ICD implantation in congenital heart disease are awaited.

General considerations for the treatment of arrhythmias

- Obtain as much information on the patient as possible
- Assess the patient thoroughly for signs of heart failure and infection
- Obtain a 12-lead ECG and compare with previous ECGs (ACHD patients often have a broad QRS complex)
- Amiodarone and β -blockers, including sotalol are the most commonly used drugs. Negative inotropes are poorly tolerated especially in patients with single ventricle physiology
- Only transfer patients to a tertiary centre once stable
- Seek expert advice early.

This page intentionally left blank

ⓘ **Syncope**

Syncope is always a matter of concern in patients with ACHD especially if they are cyanosed or have pulmonary hypertension. See Box 16.3 for causes.

Investigations

12-lead ECG, echocardiography, and Holter monitoring (patient-activated recorders and loop recorders may be employed).

ⓘ In the setting of suspected pulmonary thromboembolic disease there are many pitfalls in interpreting CT angiograms and ventilation/perfusion scans, especially in patients with shunts and systemic-to-pulmonary artery anastomoses.

Management

▶ Any syncope in a patient with congenital heart disease should initiate thorough electrophysiological and haemodynamic assessment and ideally should involve an expert in ACHD!

Box 16.3 Causes of syncope in ACHD

- Tachyarrhythmia—symptoms depend on rate and haemodynamic substrate
- Bradycardia from sinus node dysfunction, AV block
- PE
- Severe pulmonary hypertension
- Severe obstructive lesion—valve stenosis etc.
- Aortic dissection, rupture
- Myocardial ischaemia
- Hypotension—?drug induced
- Vasovagal.

ⓘ Heart failure

In any patient with ACHD presenting with heart failure, an acute underlying cause has to be excluded. Common ones are:

- Arrhythmia
- Infection
- Ischaemia.

Patients with ACHD often have very finely balanced haemodynamics with minimal cardiac reserve and even minor changes in their condition can cause severe deterioration. Emergencies caused by decompensated heart failure are expected to increase because adults with univentricular circulation (Fontan circulation) or a morphologic RV supporting the systemic circulation and other complex anatomy are increasing in numbers and are getting older. The number of potential heart transplant candidates may also increase for the same reasons, although a global shortage of organs coupled with unclear criteria and uncertainty on timing of transplantation for patients with congenital heart disease remain limiting factors.

Lesions that present with left or 'systemic' heart failure

- Left-sided valve disease—mitral and aortic valve
- TGA after Mustard or Senning repair and ccTGA
- Systemic LV dysfunction in older ToF patients.

Lesions that present with right or 'subpulmonary' heart failure

- Fontan patients
- Pulmonary hypertension/Eisenmenger syndrome
- Right-sided valve disease—tricuspid and pulmonary valve
- Mustard with obstruction of intra-atrial pathways
- Elderly patients with late repair or unrepaired ASD.

Medical treatment

- ▶ Seek expert advice early
- Find the cause—diuretics clearly will not cure a severely stenosed conduit!
- Restore sinus rhythm as soon as possible in compromised patients
- Medical treatment will not affect anatomic lesions
- Standard treatment for heart failure, including diuretics, but be cautious with vasodilator therapy.

See Table 16.1.

Table 16.1 Heart failure treatment—considerations for ACHD patients

	Pros	Cons
Loop diuretics	Effective Improve symptoms	Rapidly reduces preload Caution in Fontan patients
Spironolactone	Effective Improves symptoms	
ACE inhibitors	Effective to reduce hypertension Unknown long-term benefits on heart function	Little evidence to improve heart function. Contraindicated in pregnancy Caution if: <ul style="list-style-type: none"> ● Preload dependant. ● Obstructive lesion present ● Renal dysfunction ● Pulmonary hypertension
β-blocker	Antiarrhythmic Good for heart rate control	Caution in bradycardia
Digoxin	Rate control in atrial flutter	

Modified with permission from Gatzoulis MA et al. (eds.) *Adult Congenital Heart Disease: A Practical Guide*, 2005. Oxford: BMJ Books, Blackwell Publishing Group.

Glossary of common surgical procedures

Arterial switch operation or Jatene procedure

Operation for TGA patients. Switch of the great arteries to bring the aorta to the former pulmonary artery position and the pulmonary artery to the former aortic position. The coronary arteries have to be transposed from the aortic root to the former pulmonary artery root (neo aorta). Ultimately, the LV will perfuse the aorta and the RV will perfuse the pulmonary artery.

Bentall operation

Replacement of the ascending aorta and aortic valve with a composite graft (conduit) and valve and reimplantation of the coronary arteries into the conduit.

Brock procedure

Palliative procedure for ToF patients. Closed resection of RV musculature from the outflow tract using a biopsy-like instrument and dilatation (valvotomy) of the pulmonary valve.

Classic Blalock–Taussig shunt

Subclavian artery to ipsilateral pulmonary artery anastomosis—direct end-to-side junction.

Modified Blalock–Taussig shunt

Same shunt as ‘classic’ using a prosthetic graft.

Damus–Kaye–Stansel operation

Operation connecting aorta and pulmonary artery in a side-to-side fashion to provide unrestricted blood flow from the systemic ventricle to the aorta. For patients with single ventricles, TGA and restrictive VSD → subaortic stenosis.

Fontan operation

Palliative operation for patients with ‘single’ ventricle physiology (📖 p.272) (Fig. 16.10). Diversion of the systemic venous return to the lung without interposition of a subpulmonary ventricle; → volume unloading of the ‘single’ ventricle and ideally to normalization of the arterial oxygen saturation.

Multiple variations of the procedure exist regarding the type of connection between the systemic veins and the pulmonary arteries (Fig. 16.10):

- **Classic Fontan:** connection between RA and pulmonary artery
- **Extracardiac Fontan:** IVC connected to pulmonary artery via an extracardiac conduit combined with a Glenn shunt (📖 p.288)
- **Bjoerk or RA–RV Fontan:** valved conduit between the RA and the RV
- **Total cavopulmonary connection (TCPC):** IVC connected to pulmonary artery via an intra-atrial tunnel (also called lateral tunnel), combined with a Glenn shunt to the SVC (📖 p.288).

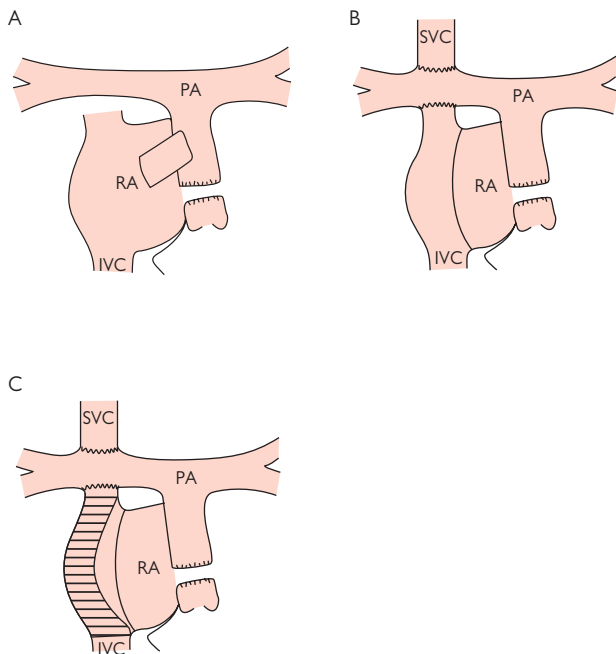


Fig. 16.10 Diagrams illustrating various types of Fontan operation.
A) Atriopulmonary Fontan. B) Total cavopulmonary connection (TCPC, lateral tunnel). C) TCPC (*extracardiac conduit).

Glenn shunt

SVC to pulmonary artery anastomosis (Fig. 16.11).

- **Classical Glenn shunt:** anastomosis of the SVC to the distal right pulmonary artery with ligation of the SVC below the anastomosis and division of the proximal right pulmonary artery from the pulmonary bifurcation
- **Bidirectional Glenn shunt:** anastomosis of the SVC to the undivided pulmonary artery

Konno operation

Complex repair and reconstruction of the LVOT for patients with tunnel-like subvalvar LVOT obstruction. The operation involves enlargement of the outflow tract by inserting a patch in the interventricular septum and aortic valve replacement as well as enlargement of the aortic annulus and the ascending aorta.

Lecompte manoeuvre

Manoeuvre that brings the pulmonary artery in a position anterior to the ascending aorta (part of the arterial switch operation or Jatene procedure).

Mustard operation

Atrial switch operation for patients with TGA—redirection of the venous blood to the contralateral ventricle using pericardial or synthetic patches.

Norwood operation

Initial palliative procedure for the treatment of hypoplastic left heart syndrome with aortic atresia and hypoplasia of the ascending aorta. Operation involves the reconstruction of 'neo-ascending' aorta using the pulmonary valve and trunk and the creation of an aortopulmonary shunt (usually modified BT shunt).

Pott's anastomosis shunt

Descending aorta to left pulmonary artery anastomosis.

Rastelli operation

Operation for patients with TGA, VSD, and PS—closure of the VSD in a way that the patch forms the LVOT to the aorta. The RV is connected to the main pulmonary artery using a valved conduit.

Ross operation

Aortic valve replacement by transplantation of the patient's pulmonary valve into aortic position (pulmonary autograft) and by replacing the pulmonary valve using a homograft valve. Major advantages:

- Potential of the 'neo-aortic' valve (former pulmonary valve) to grow in children
- No need for anticoagulation.

Senning operation

Atrial switch operation for patients with TGA, redirection of the venous blood to the contralateral ventricle using the atrial wall and the septum.

Waterston shunt

Ascending aorta to right pulmonary artery anastomosis.

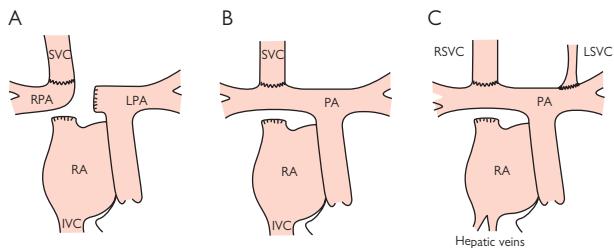


Fig. 16.11 Diagrams illustrating various types of Glenn shunt. A) Classical Glenn. B) Bidirectional Glenn. C) Bilateral bidirectional Glenn.

This page intentionally left blank

Perioperative care

- Perioperative issues 292
- Preoperative assessment 292
- Predictors of risk 294
- General considerations 296
- Coronary artery disease 298
- Cardiac failure/reduced LV function 300
- Arterial hypertension 300
- Valvular heart disease 302
- Arrhythmias/pacing 304
- Postcardiac surgical problems 306

Perioperative issues

Cardiovascular complications of anaesthesia and surgery are common in patients suffering from ischaemic heart disease, LV dysfunction, arterial hypertension, and valvular heart disease.

Size of the problem

The National Confidential Enquiry into Perioperative Death (NCEPOD) reveals that approximately 20,000 deaths within 30 days of surgery occur annually in England and Wales. 60% of these patients have evidence of coronary heart disease and approximately 8000 deaths have a cardiovascular cause.

In addition, estimates suggest 50,000–100,000 major perioperative cardiovascular complications (MI, acute LV failure, unstable angina, life-threatening arrhythmias). The high number of cardiovascular complications reflects the nature of surgery: a stress test that cannot easily be stopped once the operation has started.

Preoperative risk assessment is therefore an important element of informed consent and also influences the strategy for anaesthesia and postoperative care. Collaboration between surgeons, anaesthetists, and physicians—especially cardiologists—is essential to ensure optimal management.

Preoperative assessment

Medical opinion is sought on diagnosis, clinical status, and the appropriateness of the patient's current treatment. The medical opinion may conclude that further evaluation is required and/or recommend specific treatments, e.g. coronary revascularization or pacing, prior to surgery.

Guided by this medical opinion, the anaesthetist can determine the patient's fitness for anaesthesia and surgery and develop a strategy for anaesthesia and postoperative care. This includes the extent of cardiovascular monitoring and the best location for postoperative care, e.g. ICU or HDU. *Informed consent* will require consideration of the risks as well as the benefits of the procedure.

This page intentionally left blank

Predictors of risk

The risk of perioperative cardiac complications relates to both the clinical status of the patient and the nature of the proposed surgery. The following stratification of predictors is based on the American College of Cardiology/American Heart Association guidelines. Clearly, the highest risk occurs when a patient with a 'major' clinical risk factor(s) undergoes a 'major' risk surgical procedure.

Predictors related to the patient

Major

- Unstable coronary syndromes
- Acute or recent MI
- Unstable or severe angina—Canadian class III or IV
- Decompensated heart failure—new onset or worsening or NYHA class IV
- Significant arrhythmias
- High-grade AV block
- Symptomatic ventricular arrhythmias
- Supraventricular arrhythmias—including AF with uncontrolled ventricular rate >100 bpm at rest
- Severe valvular disease.

Intermediate

- Mild angina (Canadian Class I or II)
- Previous MI (history, pathological Q waves)
- Compensated or prior heart failure
- Diabetes mellitus
- Renal insufficiency.

Minor

- Advanced age
- Abnormal ECG—LV hypertrophy, LBBB, ST-T segment abnormalities
- Rhythm other than sinus
- Low functional capacity—inability to climb 1 flight of stairs
- History of stroke
- Uncontrolled systemic hypertension.

Special considerations

- Severe hypertension with target organ involvement, LV hypertrophy and strain
- Comorbidity—not already mentioned
- Obstructive airway disease
- Possible interactions between medication and anaesthetic agents.

Predictors related to surgery

Major (reported cardiac risk >5%)

- Emergency major operation—particularly in the elderly
- Aortic and other major vascular surgery
- Peripheral vascular surgery
- Anticipated prolonged procedures with large fluid shifts and/or blood loss.

Intermediate (reported cardiac risk generally <5%)

- Carotid endarterectomy
- Head and neck surgery
- Intraperitoneal and intrathoracic surgery
- Orthopaedic surgery
- Prostate surgery.

Low risk

- Endoscopic procedures
- Superficial procedures
- Cataract surgery
- Breast surgery.

In addition, special consideration should be given to the following:

- Cardiovascular effect of aortic cross-clamping and de-clamping
- Gut handling leading to the release of inflammatory mediators
- Surgery likely to impair postoperative respiratory function
- Positioning of the patient on the operating table (often for minimally invasive surgery), e.g. steep head-down position with or without leg elevation.

Predictors related to the type of anaesthetic

Spinal or epidural anaesthesia

- Perceived to be safer for cardiac patients than GA
- **But** no scientific evidence of reduced cardiac risk
- ► **And** severe hypotension can result from autonomic blockade, so may actually be worse!
- Where spinal or epidural anaesthesia offer major advantages, monitoring needs to be extensive because of the possibility of hypotension.

Local and regional anaesthesia (regional nerve blocks)

Associated with a relatively low risk of postoperative cardiac events.

General considerations

Cardiac disease is not always clinically obvious, particularly where function is limited, e.g. by lower limb arthropathy or peripheral vascular disease

Emergencies

Where potentially life-saving emergency surgery is required (e.g. ruptured aortic aneurysm, major trauma), identify and treat cardiac complications where possible, with a view to further cardiac evaluation post-operatively.

Elective/semi-urgent cases

- In the non-emergency setting, patients with 'major' clinical risk factors usually require further investigation and/or treatment
 - Patients with no more than 'intermediate' clinical risk factors, a functional capacity that would allow them to walk up a hill or play a round of golf, and who are undergoing surgery of 'intermediate' risk or less can generally proceed with a low probability of cardiac events
 - For 'major' risk procedures and/or where functional capacity is low, non-invasive functional investigation may be required, depending on the individual situation, e.g.:
 - Echocardiography—to check LV function; this is a major determinant of risk
 - Exercise ECG—treadmill test
 - Stress echocardiography—using exercise or dobutamine
 - Myocardial perfusion scan (SPECT) to investigate potential coronary disease
 - Stress radionuclide ventriculography (a MUGA scan) to examine functional capacity of the LV under stress.
- Significant reversible myocardial ischaemia increases the risk of cardiac events after major surgery and further evaluation, e.g. with coronary angiography may be indicated.

Cardiovascular drugs

- Most cardiovascular drugs can be safely administered throughout the perioperative period
- ACE inhibitors and angiotensin receptor antagonists may have to be omitted on the morning of surgery to reduce the risk of intractable hypotension.

This page intentionally left blank

Coronary artery disease

Coronary disease is the most frequent cause of cardiac complications from anaesthesia and surgery. In susceptible individuals, coronary events may be precipitated by haemodynamic perturbations (tachycardia, hypotension, hypertension), perioperative hypoxaemia (especially nocturnal hypoxaemia after abdominal surgery), altered coagulation, postoperative anaemia, or perioperative release of inflammatory cytokines causing disruption of vulnerable coronary plaques.

Angina

- Well-controlled angina increases the risk of anaesthesia and surgery but this increase is generally acceptable
- Unstable and recent onset angina must be investigated preoperatively as perioperative morbidity and mortality are unacceptably high

Prior MI

- The time between the MI and proposed elective surgery is important. An interval of at least 3–6 months is generally advocated. A delay of 6 weeks can be acceptable in uncomplicated MI, if there is no subsequent ischaemia on a stress test
- As myocardial function is a major determinant of risk, patients with reduced LV function remain at ↑risk irrespective of the time that has elapsed since the MI.

Prior CABG

Asymptomatic patients within 5 years of successful CABG are at low risk for perioperative cardiac events providing ventricular function is good and they remain asymptomatic.

Prior PCI

While CABG offers some protection, there is no such evidence for PCI. There is some evidence that perioperative risk is *greater* in the first 1–3 months following PCI, though whether this reflects a higher risk population or an effect of the procedure is unclear.

Antiplatelet therapy

- To minimize the risk of stent thrombosis (from the exposed metal struts), patients usually receive aspirin and clopidogrel for up to 6 weeks for bare metal stents, and 12 months for drug-eluting stents
- The pronounced antiplatelet effect of these drugs poses a risk of perioperative haemorrhage, so it is preferable to defer surgery until a month after patients no longer need dual antiplatelet therapy, i.e. 6–10 weeks for bare metal stents and 13 months for drug eluting stents
- If surgery cannot be delayed, the decision on the withdrawal or maintenance of dual antiplatelet therapy requires a discussion involving surgeon, cardiologist, anaesthetist, ± haematologist. Surgery in closed cavities generally requires the withdrawal of dual antiplatelet therapy with the attending risk of stent thrombosis
- In emergency situations, excessive bleeding may require the administration of platelets.

Box 17.1 The need for coronary revascularization

Coronary revascularization (either CABG or PCI) may be necessary in selected patients to decrease the risk of cardiac complications from anaesthesia and surgery. Current guidelines recommend that coronary revascularization should be performed prior to non-cardiac surgery if it is indicated for conventional indications (irrespective of planned non-cardiac surgery). If coronary revascularization is not warranted for conventional clinical indications, it should only be considered before high-risk surgery (particularly major vascular surgery).

The evidence for protection is weak however; there is observational data to suggest that patients who have undergone successful CABG are protected against perioperative cardiac events if their cardiac function is good and there is no recurrence of symptoms. By contrast, the incidence of perioperative cardiac complications does not appear to be reduced by PCI.

Box 17.2 Prophylactic perioperative β -blockade¹

Patients on chronic β -blocker therapy should continue on β -blockers for an established indication (e.g. angina, hypertension, congestive heart failure, arrhythmia) throughout the perioperative period.


Though acute β -blockade has been widely advocated for the prophylaxis of perioperative cardiac events, evidence of their efficacy was inconclusive. A recent, large, randomized controlled trial of acute perioperative β -blockade (the POISE study²) has shown that while the risk of cardiac death and MI is reduced, there is an increase in all cause mortality and in strokes. This balance of risks requires decisions based on the circumstances of individual patients

Where β -blockers are considered advantageous, treatment should be started days or weeks before elective surgery and the dose titrated to obtain a resting heart rate of ~60–70 bpm with strict protocols for rate and BP control.

References

1. Fleisher LA et al. ACC/AHA 2006 guideline update on perioperative cardiovascular evaluation for noncardiac surgery: focused update on perioperative beta-blocker therapy: a report of the American College of Cardiology/American Heart Association Task Force on Practice Guidelines. *Circulation* 2006; **113**: 2662–74.
2. Devereaux PJ et al. Effects of extended-release metoprolol succinate in patients undergoing non-cardiac surgery (POISE trial): a randomised controlled trial. *Lancet* 2008; **371**: 1839–47.

Cardiac failure/reduced LV function

Both objective cardiac function and the patient's functional capacity are useful for predicting operative risk (see  NYHA classification, p.69). The ability to climb 1 flight of stairs with some load (or equivalent) is considered adequate reserve for most surgeries. Heart failure management should be optimized before surgery.

Objective testing

- Echocardiography
- Radionuclide ventriculography (MUGA scan)
- CMR.

Arterial hypertension

- Hypertension confers a modest increase in the risk of cardiovascular complications, irrespective of the admission BP
- Presence of target organ involvement is more important than the level of BP for predicting events
- Defer surgery and treat hypertension if systolic pressure >180 mmHg and/or diastolic >110 mmHg. A delay of 4–6 weeks is necessary to improve autoregulation of blood flow, particularly in the brain.

This page intentionally left blank

Valvular heart disease

See also  Chapter 8.

Aortic stenosis

Severe AS represents the most serious threat. The fixed obstruction to cardiac output permits very little adaptation where ↑output is required. Peripheral vasodilatation, e.g. from regional anaesthesia or hypotension from haemorrhage cannot be matched by an adequate increase in cardiac output. The consequent fall in BP can lead to coronary hypoperfusion, reduced myocardial function and further hypotension. This is a potentially fatal downward spiral. Although AS cannot be alleviated easily, knowledge of the severity can inform the patient and doctor of the risks, and help determine the required monitoring.

Even in **moderate AS**, stiffness of the LV reduces the tolerance of variability of filling conditions. In fluid overload, the LA pressure will increase sharply, provoking pulmonary oedema, while low filling pressure (hypovolaemia) or low diastolic filling time (high ventricular rates) will decrease cardiac output. Where symptoms or physical signs suggest AS, a pre-operative echocardiogram should be obtained.


Mitral stenosis

- Maintain slow heart rate—the onset of AF or loss of rate control in the perioperative period will decrease diastolic filling and cause a fall in cardiac output. This can provoke an abrupt deterioration ± pulmonary oedema
- Careful fluid balance—underfilling may cause an inordinate reduction in output while overfilling may cause pulmonary oedema.

Mitral and aortic regurgitation

- In general are well tolerated
- Require careful fluid management
- May benefit from afterload reduction, e.g. with nitrates/ACE inhibitors.

Valve surgery

In some cases it may be appropriate to alleviate valve lesions prior to non-cardiac surgery, though a full discussion of indications are given in  Chapter 8. The decision must take into account the risks of prosthetic valve thrombosis and endocarditis (Box 17.3) related to future surgery.

Anticoagulation

(Also see  p.117.)

- Metallic prosthetic valves—anticoagulation is discontinued before most operations. Warfarin is replaced by an IV infusion of heparin until shortly before surgery to provide perioperative anticoagulation
- In emergencies, anticoagulation with warfarin can be transiently reversed by administration of FFP, which provides clotting factors
- ► Be very wary of giving vitamin K since this will prevent anticoagulation with warfarin for a prolonged period. With expert guidance, small doses of vitamin K (phytomenadione e.g. 1 mg), can be administered.

Box 17.3 Endocarditis avoidance

Abnormal heart valves, prosthetic mechanical valves, or biological valves are at ↑risk for infective endocarditis from organisms introduced at the time of surgery.


Antibiotic prophylaxis

This is a controversial topic—there is little evidence for its effectiveness, and the ↑risk from surgery is small compared to the background risk from everyday activities such as tooth-brushing. A fuller discussion on this can be found in Chapter 9 on Infective endocarditis (📖 Prophylaxis, p.134).


Vascular access

- Keep vascular access to the minimum necessary
- Take precautions to avoid infections at insertion
- Observe the skin around lines for signs of infection and revise lines regularly
- Seek to remove all vascular catheters as soon as they are no longer needed.

Arrhythmias/pacing

- Most arrhythmias should be stabilized prior to surgery
- Controlled chronic AF (rate <100 bpm) is rarely a significant problem
- During anaesthesia and surgery, arrhythmias occur frequently and require treatment if haemodynamic compromise occurs
- See  Chapter 10 for specific details of management.

Preoperative pacemaker insertion

In general, the indications for preoperative pacemaker insertion, including temporary pacemaker insertion, are the same as those for the non-surgical setting (see  p.139). These include complete heart block, Mobitz type II block, and symptomatic bradycardia. There are thus almost no circumstances where pacing is required purely for surgery,

Pacemakers and implantable defibrillators during surgery

- ▶ Establish the type of pacemaker or defibrillator, the indications for implantation, and the functional settings from the patient's pacemaker identification card or from the centre where it was implanted.
- ▶ With modern complex pacemakers/defibrillators it is no longer advisable to blindly return the pacemaker to its simplest mode of operation by fixing a magnet over it

Electromagnetic interference

Pacemakers and defibrillators are susceptible to interference, and in the operating theatre, diathermy equipment is the major concern. EMI may affect the device by direct electrical interference during diathermy or by exposure to an electromagnetic field (with the device lead acting as an aerial).

- Potential effects:
 - Inappropriate inhibition or triggering of paced output
 - Asynchronous pacing
 - Reprogramming—usually into a back-up mode
 - Damage to circuitry, or triggering of defibrillator discharge
 - Defibrillators may interpret electrocautery as VF and deliver a shock
- Bipolar leads, generally used in contemporary pacing systems, are much less sensitive to EMI than unipolar leads
- Electrocautery is usually applied in unipolar configuration between the handheld instrument (cathode) and the anode attached to the patient's skin
- ▶ Diathermy should be avoided near the pacemaker/ICD generator
- ▶ Bipolar diathermy should be used wherever possible.

This page intentionally left blank

Postcardiac surgery problems

This section is intended as a practical guide to situations commonly experienced after cardiac surgery.

The hypotensive patient


Read the operation note and anaesthetic chart.

Was the operation straightforward? The surgeon will have noted any difficulties, e.g. where small calibre coronary arteries prejudice graft patency, or problems with haemostasis. What was the preoperative assessment of LV function?

Blood pressure

Note the BP and pulse trends. Was there an abrupt change suggestive of an acute 'event' or has the change been gradual? Compare with preoperative values. Determine peripheral perfusion. Is the patient cold and 'shut down' or peripherally vasodilated? What is the urine output?

Filling

Is the patient adequately filled? One size does not fit all in this respect. Patients with LV hypertrophy but good LV systolic function (e.g. after aortic valve replacement) are likely to require higher filling pressures. In patients with significant TR (e.g. after mitral valve replacement), filling will be difficult to gauge from the venous pressure. Remember that early after surgery, you are likely to have the benefit of a CVP line—see  p.12.


ECG

Does the ECG show evidence of myocardial ischaemia? Has the rhythm changed? AF is common postoperatively. New-onset or fast AF may be sufficient to compromise BP in susceptible patients.

Pericardial drains

Are the pericardial drains working? Has the rate of drainage changed (new bleeding, drain occlusion)? Hypotension with tachycardia, and elevated CVP may indicate pericardial tamponade. This can occur rapidly and may be caused by a relatively small volume of pericardial blood. Postoperatively, this may be caused by localized effects on a single chamber.

► An urgent echocardiogram should be obtained. In extreme cases, sudden haemodynamic collapse necessitates emergency exploration and direct drainage with the chest re-opened.

- When hypotension persists despite correction of the reversible causes, further evaluation with echocardiography may be indicated. New wall motion abnormalities suggest perioperative infarction or 'stunning'
- Consider support with inotropic drugs ± IABP. These are considered in greater detail elsewhere ( p.8, 10).


Atrial fibrillation postcardiac surgery

- Occurs in approximately 25% of patients
- More frequent in elderly patients and those with a prior history of AF
- Likely to return spontaneously to sinus rhythm, unless AF was present preoperatively.

Actions

- Markedly compromised patients need DC cardioversion
- Correct hypokalaemia: keep K^+ above 4.5 mmol/L
- Control rate with amiodarone or digoxin. β -blockers/calcium-channel blockers can be used if the underlying cardiac function is good
- IV amiodarone (central line) may hasten reversion to sinus. In selected patients, continuation with oral therapy may be indicated
- Anticoagulation is needed if persistent (heparin \rightarrow warfarin)
- Arrange outpatient review of continuing need for antiarrhythmic therapy \pm cardioversion.

AV conduction block

- Most likely after aortic valve surgery because of the valve's proximity to the AV node
- Pacing is necessary using epicardial pacing electrodes implanted at surgery or a temporary transvenous system
- Permanent pacemaker implantation is sometimes required. Predicted by preoperative features—AV block, LBBB, root abscess, calcified aortic annulus, AR, and prior MI. See  p.139 for indications

Postpericardiotomy syndrome

- Inflammatory (possibly autoimmune) pericarditis that occurs >1 week after cardiac surgery where the pericardium has been opened
- Often associated with fever, pericarditic pain, and malaise
- The associated effusion may be serous or serosanguinous. It can be large and can lead to tamponade
- The diagnosis is clinical. Echocardiography is helpful in helping to determine the size, distribution, percutaneous accessibility, and haemodynamic significance of any effusion
- Usually self-limiting, but may recur.
- \blacktriangleright Treat with NSAIDs.

Further reading

Fleisher LA et al. ACC/AHA guideline on perioperative cardiovascular evaluation and care for noncardiac surgery. A report of the American College of Cardiology/American Heart Association Task Force on Practice Guidelines. *Circulation* 2007; **116**: 1971–96.

This page intentionally left blank

Cardiac drugs: effects and cardiotoxicity

General approach to cardiotoxicity 310

Cardiac drugs

β -blockers 312

β -blocker toxicity 313

Calcium-channel blockers 314

Calcium-channel blocker toxicity 315

Diuretics 316

Renin–angiotensin system inhibitors 318

Other vasodilators 320

Antiarrhythmic drugs 322

Flecainide 324

Amiodarone 326

Digoxin 328

Digoxin toxicity 330

Statins 332

Other lipid-modifying drugs 334

Antiplatelet agents 336

Newer cardiac therapies 338

Cardiotoxic drugs in overdose 340

Recreational drugs with cardiac effects in overdose 342

Drug-induced QT prolongation 344

Drugs used in cancer 346

General approach to cardiotoxicity

Cardiovascular side effects can occur with both cardiac and non-cardiac medication. In particular, side effects 2° to recreational drug use are becoming more prevalent. Patient history may be unreliable and any witnesses should be sought.



- ▶ This chapter should be used as a brief guide—detailed information is available, particularly on drug doses (see ‘Sources of information’).
- ▶ Specialist advice should be sought for overdoses in children.

General management principles

- Resuscitate the patient
- Consider the prevention of drug absorption:
 - Activated charcoal (50 g orally) will absorb many drugs if given <1 hour after ingestion
 - Gastric lavage can be considered if a substantial overdose has been ingested <1 hour previously. The evidence for benefit is weak however, and it is performed less commonly now
- Supportive care—e.g. airway maintenance, acid–base and electrolyte balance, treat seizures—is important
- Any unstable (haemodynamically compromising) arrhythmias (VT, fast SVT >180/min) are better dealt with by cardioversion than drugs

Sources of information

TOXBASE: web-based service accessible from any emergency department:  <http://www.spib.acl.co.uk>

- In the UK, the **Poisons Information Service:**  0870 6006266 directs callers to local unit
- The **British National Formulary** contains detailed advice on drugs and doses:  <http://www.bnf.org/bnf>.

This page intentionally left blank

β -blockers

Main indications

- Hypertension
- Ischaemic heart disease—angina, cardioprotection post-MI
- Cardiac arrhythmias
- Congestive cardiac failure
- *Other*: HCM, acute dissection, aortic root dilatation (i.e. Marfan's), phaeochromocytoma—with α -blocker.

Mechanism of action

- Block action of endogenous catecholamines
- Negative chronotropic and inotropic effect
- \downarrow renin release—via renal β 1-adrenergic receptors
- Depressed conduction through sinoatrial and AV nodes
- Antisymphathetic central effect
- \downarrow cardiac workload, \downarrow cardiac output, and \downarrow salt/water retention

Contraindications

- Decompensated heart failure
- Cardiogenic shock
- Asthma or acute bronchospasm
- Bradyarrhythmias
- Sick sinus syndrome, 2nd- and 3rd-degree AV block
- Long QT syndrome and torsade de pointes (*sotalol*)
- Severe peripheral vascular disease
- **⚠**Caution in AR, COPD, concomitant use with diuretics (diabetes risk), rate-slowing calcium-channel blockers.

Side effects

- *Cardiac*—hypotension, bradycardia, AV block, heart failure
- *Vascular*—cold extremities, Raynaud's, peripheral vasoconstriction
- *Respiratory*—dyspnoea, bronchospasm
- *GI*—diarrhoea
- *CNS*—headache, paraesthesia, visual disturbance, insomnia, hallucinations, depression, psychoses
- *Other*—fatigue, erectile/sexual dysfunction, thrombocytopenia purpura, psoriasis exacerbations.

Dosing

- *Atenolol*—25–50 mg PO daily, max. 100 mg/day
- *Bisoprolol*—1.25 mg PO daily (heart failure); 2.5–5 mg (IHD/HT); max. 10 mg/day
- *Metoprolol*—25–50 mg BD/TDS PO, max. 400 mg/day; 5 mg IV every 5 min up to 15 mg in acute MI or tachyarrhythmias
- *Sotalol*—40–80 mg BD PO, may increase to 160 mg BD
- *Carvedilol*—3.125–6.25 mg BD PO to start, max. 50 mg/day
- *Propranolol*—20–40 mg BD PO, max. 320 mg/day.

β-blocker toxicity

Clinical features

- Light-headedness, dizziness, syncope
- Bradycardia
- Hypotension
- Heart failure—esp. if pre-existing LV dysfunction
- Drowsiness, confusion, convulsions
- Cardiorespiratory arrest, due to asystole or VF—rare
- Bronchospasm—uncommon

► Prognosis is worsened in those taking concomitant *calcium-channel blocker therapy*

Investigations

ECG—AV block, intraventricular conduction defects (RBBB, LBBB), ventricular extrasystoles, asystole

Management

- Consider activated charcoal (or lavage for large overdoses) if <1 hour
- Observe for at least 6 hours (12 if slow-release preparation)
- *Atropine*—for symptomatic bradycardia & hypotension (3 mg IV bolus)
- *IV fluids for hypotension*
- *Glucagon*—for severe bradycardia, hypotension or heart failure unresponsive to atropine. Increases myocardial cAMP, thereby acting as an inotrope. Dose: 2–10 mg IV bolus followed, if necessary, by IV infusion (1–5 mg/hour). Can cause vomiting, so antiemetic sometimes required
- *Pacing*—temporary transvenous or external pacing should be considered if atropine and glucagon are ineffective (📖 p.368)
- *Salbutamol*—for bronchospasm 5–10 mg nebulized
- *Dextrose*—if hypoglycaemia develops, give 25 mL of 50% dextrose. Monitor blood glucose closely
- *Inotropes*—in severe cases, may be needed to maintain cardiac output: e.g. dobutamine (2.5–10 mcg/kg/min) or isoprenaline (5–10 mcg/min) by IV infusion.

► Sotalol has additional class III antiarrhythmic action and can cause QT prolongation and torsade de pointes (📖 p.182, 344).

Calcium-channel blockers

- Dihydropyridine group—vasodilation but no negative ino- or chronotropic effects, e.g. nifedipine, amlodipine, felodipine.
- Non-dihydropyridine group—vasodilation and negative ino- and chronotropic effects (the latter are lower in diltiazem, higher in verapamil; both lower than β -blockers)

Main indications

- Hypertension
- Ischaemic heart disease—angina
- Coronary artery spasm—prophylaxis
- Cardiac arrhythmias—*verapamil* and *diltiazem*
- Pulmonary hypertension
- Peripheral vasoconstriction (e.g. Raynaud's)—dihydropyridine group.

Mechanism of action

- Block cardiovascular L-type calcium channels (\downarrow cellular Ca^{2+} influx)
- Peripheral vasodilatation—reduced contraction of VSM
- Negative chronotropic and inotropic effect—*verapamil* and *diltiazem*
- Above mechanisms cause \downarrow cardiac output \rightarrow \downarrow cardiac oxygen demand
- Antidromotropic effect—depressed cardiac conduction.

Contraindications (mostly apply to non-dihydropyridine group)

- Cardiogenic shock—applies to all
- Decompensated heart failure
- Bradyarrhythmias—sick sinus syndrome, 2nd- or 3rd-degree AV block
- ⚠Caution in severe AS, WPW, 1st degree AV block, \downarrow LV function, concomitant use with other drugs (β -blockers, quinidine), and in renal/hepatic impairment.

Side effects

- Ankle oedema—very common in dihydropyridine group. \downarrow incidence in some, e.g. *lercanidipine*, *lacidipine*
- Cardiac—palpitation, brady/tachycardia, \downarrow BP, AV block, heart failure
- GI—nausea/vomiting, dyspepsia, constipation, hepatitis
- CNS—headaches, dizziness, insomnia, depression
- Other—lethargy, gynaecomastia, flushing, gingival hypertrophy, erectile dysfunction, blood dyscrasias, inhibition of hepatic CYP enzymes.

Dosing

- *Amlodipine*—initially 5 mg OD PO up to 10 mg daily
- *Nifedipine*—immediate release: initially 5 mg TDS PO, max. 60 mg daily; modified release: 20–30 mg OD PO, max. 90 mg daily
- *Felodipine*—initially 5 mg OD PO up to 10 mg daily
- *Diltiazem*—standard release: initially 60 mg TDS PO, max. 360 mg daily; modified release: 60–180 mg BD or 120–480 mg once-daily preparations
- *Verapamil*—immediate release: initially 40–120 mg TDS PO, modified release: 120–240 mg in 1–2 doses, max. 480 mg daily; for supraventricular arrhythmias can give 5–10 mg IV (over 2 min) and an additional 5 mg after 5 min if necessary.

Calcium-channel blocker toxicity


Clinical features

- Nausea, vomiting, dizziness
- Slurred speech, confusion, convulsion
- Hypotension
- Hyperglycaemia, metabolic acidosis
- *Dihydropyridine group* (e.g. nifedipine, amlodipine):
 - Sinus tachycardia
- *Non-dihydropyridine group* (e.g. diltiazem, verapamil):
 - Sinus bradycardia, AV block
 - ↓myocardial contractility, pulmonary oedema.

Investigations

ECG—as for β -blockers.

Management

- Consider activated charcoal or gastric lavage (see  p.310). Sustained release preparations may require further charcoal every 4 hours, plus a single dose of osmotic laxative (e.g. lactulose, $MgSO_4$)
- Monitor for ≥ 4 hours (≥ 12 hours if sustained-release preparation)
- *Calcium chloride* (0.2 mL/kg of 10% solution, up to 10 mL, IV over 5 min) for significant clinical features (or *calcium gluconate*: at 2–3 \times dose). Can be repeated every 10–20 min up to 4 doses. May reverse prolonged intracardiac conduction times
- *Glucagon* for severe myocardial depression or hypotension. 10 mg IV every 3 min. Consider infusion (3–6 mg/hour) if good response
- Consider *atropine*, *pacing* and *inotropes* as for β -blockers
- ► Prognosis is worsened in those taking concomitant β -blocker therapy.

Diuretics

Main indications

- Congestive cardiac failure—loop diuretics primarily, or *metolazone* for refractory oedema
- Hypertension—*thiazides*
- Post-MI—aldosterone antagonists, but primarily *eplerenone*

Mechanism of action by type

- Thiazides—e.g. *bendroflumethiazide*, *metolazone*; inhibit Na^+/Cl^- co-transporter at distal tubule yielding $\uparrow \text{Na}^+$ and water excretion
- Loop diuretics—e.g. *furosemide*, *bumetanide*; inhibit $\text{Na}^+-\text{K}^+-2\text{Cl}^-$ symporter at the loop of Henle (medullary thick ascending limb)
- K^+ sparing diuretics—e.g. *amiloride* (inhibits epithelial Na^+ channels), *spironolactone*, *eplerenone* (aldosterone antagonists); inhibit Na^+/K^+ exchanger at cortical collecting ducts.

Contraindications

- Hypersensitivity
- Gout
- For thiazides—⚠caution in dyslipidaemia, erectile/sexual dysfunction, diabetes, prostatism, renal and hepatic impairment.

Side effects

- Cardiac—hypotension, arrhythmias 2° to electrolyte imbalance
- GI—nausea/vomiting, constipation, anorexia, pancreatitis
- CNS—confusion, coma, seizures, stupor, depression, paralysis (all rare)
- Other—hypo/hyperkalaemia, muscle cramps, hyponatraemia, hypercalcaemia, hyperglycaemia, hyperuricaemia (gout), dyslipidaemia, metabolic acidosis (*amilorides*) or alkalosis (*thiazides*, *loop diuretics*).

Dosing

- *Furosemide*—initially 20–80 mg OD PO, max. 600 mg/day
- *Bumetanide*—initially 0.5–2 mg OD PO, max. 10 mg/day (1 mg bumetanide ~40 mg furosemide)
- *Bendroflumethiazide*—2.5 mg OD PO (benefit from further dose increases usually outweighed by side effects)
- *Metolazone*—initially 2.5 mg once only to gauge response, then 2.5–5 mg OD PO, max. 20 mg/day
- *Amiloride*—initially 5 mg OD PO, max. 20 mg/day
- *Spironolactone*—initially 25–100 mg PO in 1–2 doses, max. 400 mg/day
- *Eplerenone*—initially 25 mg OD PO, increase within 4 weeks to 50 mg OD.

This page intentionally left blank

Renin–angiotensin system inhibitors

Main indications

- Hypertension
- Congestive cardiac failure
- Asymptomatic LV dysfunction—improve prognosis
- Post-MI—reduce adverse remodelling
- Ischaemic heart disease—2° prevention

Types

- ACE inhibitors, e.g. ramipril, lisinopril. Diminish effects of angiotensin II
- Angiotensin II AT₁ receptor blockers, e.g. losartan, candesartan, valsartan. Often used when ACE inhibitors not tolerated, e.g. persistent cough
- Use of ACE inhibitors and angiotensin II AT₁ receptor blockers in combination is debated

Mechanism of action

- Peripheral vasodilatation—arterial vasodilators
- ↑stroke volume and cardiac output
- Reduced TPR and renovascular resistance
- ↑natriuresis; inhibition of aldosterone release from adrenal cortex thereby promoting Na⁺ and water excretion
- Inhibition of vasopressin (antidiuretic hormone) release from posterior pituitary
- Prevent adverse ventricular remodelling → LV hypertrophy.

Contraindications/cautions

- Angio-oedema
- Renal artery stenosis
- Pregnancy—especially 2nd and 3rd trimesters
- ⚠Caution in renal impairment, severe/symptomatic LVOT obstruction, and concomitant use with other K⁺-sparing drugs.

Side effects

- *Cardiac*—hypotension (particularly 1st dose)
- *Respiratory*—cough (with ACE inhibitors, due to ↑bradykinins), sinusitis, rhinitis
- *GI*—nausea/vomiting, dyspepsia, diarrhoea, constipation, abdominal pain
- *CNS*—headache, dizziness, insomnia, paraesthesia
- *Other*—hyperkalaemia, hypoglycaemia, myalgia, arthralgia, anaemia, rash, angio-oedema, renal impairment, deranged LFTs, blood disorders.

Dosing

- *Ramipril*—initially 1.25–2.5 mg OD PO, max. 10 mg/day
- *Lisinopril*—initially 2.5–5 mg OD PO, max. 80 mg/day
- *Enalapril*—initially 2.5–5 mg OD PO, max. 40 mg/day in 1–2 doses
- *Perindopril*—initially 2 mg OD PO doubling each week to max. 8 mg/day
- *Losartan*—initially 25–50 mg OD PO, max. 100 mg/day in 1–2 doses
- *Irbesartan*—initially 75–150 mg OD PO, max. 300 mg/day in 1–2 doses
- *Candesartan*—initially 4 mg OD PO, max. 32 mg/day in 1–2 doses
- *Valsartan*—initially 20–40 mg BD PO, max. 160 mg BD.

This page intentionally left blank

Other vasodilators

Nitrates

- Highly effective vasodilators (arterial and venous), esp. coronary
- Used primarily for prophylactic treatment of angina
- Very short acting—SL GTN used for rapid relief of angina
- Chronic use requires sustained release preparations for effective dosing—usually BD or OD dosing
- *Side effects*—headache, hypotension, dizziness, nausea, diarrhoea, dyspepsia
- *Contraindications*—severe LVOT obstruction
- **⚠Caution with**—concomitant use with other vasodilators, antihypertensives, and phosphodiesterase inhibitors (e.g. sildenafil)
- *E.g. GTN, isosorbide mononitrate, isosorbide dinitrate*
- *Dose*—*isosorbide mononitrate* 10 mg BD PO, increasing to 120 mg daily in divided doses—or single dose if long-acting sustained-release preparation

Nicorandil

- Activates K^+ channels to cause vasodilatation (venous > arterial)
- Work in a very similar way to nitrates
- Used to treat angina
- Reduces preload and hence cardiac workload
- *Side effects*—headache, flushing, palpitations, nausea/vomiting, dizziness, weakness, mouth/intestinal ulcers
- *Contraindications*—hypotension, LVF (with low filling pressures), cardiogenic shock and concomitant use with phosphodiesterase inhibitors (e.g. sildenafil)
- *Dose*—10 mg BD PO increasing to 30 mg BD max.

α -blockers


- Arterial vasodilators; block α_1 -adrenergic receptors in vascular smooth muscle
- Used in treatment of severe/resistant hypertension
- Of particular use where benign prostatic hypertrophy co-exists, and in phaeochromocytomas where combined β - and α -blockade is required
- *Side effects*—dizziness, headache, nausea, weakness, postural hypotension, fluid retention, sexual dysfunction, rash, agitation, depression
- *Contraindications*—**⚠caution** in concomitant use with other antihypertensives and phosphodiesterase inhibitors
- *Dose*—*doxazosin* 1 mg OD PO, doubling every 1–2 weeks to usual max. 8 mg daily; can be up to 16 mg in selected cases.

Hydralazine

- Arterial vasodilator—relaxes vascular smooth muscle ($\downarrow Ca^{2+}$ release from sarcoplasmic reticulum)
- Used as adjunctive treatment for severe hypertension and 1st-line antihypertensive in pregnancy

- *Side effects*—reflex tachycardia, palpitation, hypotension, fluid retention, flushing, headache, nausea, diarrhoea, anorexia, drug-induced SLE
- *Contraindications*—coronary artery disease, MS
- **⚠** *Caution in*—cerebrovascular disease and severe renal impairment
- *Dose*—25 mg BD PO, increasing to 50 mg BD.

Antiarrhythmic drugs

Categorized historically by Vaughan–Williams classification (see  Table 10.4, p.155) (although incomplete and excludes some drugs, e.g. *digoxin*, *adenosine*).

For details of use see  Pharmacological treatment, p.154.

Class I (membrane stabilizers)

- Na^+ channel blockers, restricting fast Na^+ current in phases 0 and 4 of cardiac AP
- ↓spontaneous automaticity, ↑excitation threshold.

Class Ia

- Lengthen AP with prolonged repolarization (phases 3 & 4) and refractory period (K^+ -channel blockade)
- Delay conduction—prolong PR, QRS, QT
- E.g. *quinidine*, *procainamide*, *disopyramide*.

Class Ib

- Shorten AP, shorten and ↑rate of repolarization
- Minimal effect on refractory period—no K^+ -channel blockade
- ↑fibrillation threshold
- ↓automaticity
- E.g. *lidocaine*, *mexilitene*, *tocainide*, *phenytoin*.

Class Ic

- Prolong refractory period—block outward rectifying K^+ channels
- ↓repolarization rate and contractility
- Delay conduction—prolong PR, QRS
- E.g. *flecainide*, *propafenone*.


Class II (β -adrenergic receptor blockers)

- ↓ Ca^{2+} influx responsible for automaticity—↓rate and conduction)
- See  p.000.

Class III (K^+ -channel blockers)

- Decrease K^+ efflux during repolarization
- Prolong repolarization and effective refractory period
- E.g. *amiodarone*, *sotalol*, *bretylum*, *dofetilide*

Class IV (Ca^{2+} -channel blockers)

- ↓SA and AV node automaticity and AV conduction
- See  p.314.

This page intentionally left blank

Flecainide

Class Ic antiarrhythmic agent; effective for many types of life-threatening SVTs and VTs.

Main indications

- AF/atrial flutter—acute control, or chronic maintenance of sinus rhythm
- AVNRT(SVT)
- WPW syndrome
- VT—non-ischaemic
- RVOT tachycardia.

Mechanism of action

- Rate-dependent block of cardiac Na⁺ channels
- Prolongs cardiac AP
- Slows conduction through His–Purkinje system and ventricular myocardium (delays repolarization); prolongs ventricular refractory period
- ↓ventricular myocardial contractility
- Dose related ↑ in PR, QRS, and intra-atrial conduction intervals.

Contraindications

- Bradycardia
- AV block or sinus node disease
- Structural (incl. valvular) heart disease
- Ischaemic heart disease
- LV dysfunction/heart failure
- ⚠Caution in renal or hepatic impairment, with pacemakers (↑ capture thresholds) and concomitant use with other drugs (digoxin, alcohol, amiodarone, propafenone, procainamide, quinidine, cimetidine, paroxetine, β- and Ca²⁺-channel blockers).

Side effects

- *Cardiac*—pro-arrhythmia, bradycardia, AV block, heart failure
- *Respiratory*—dyspnoea, pneumonitis
- *GI*—nausea/vomiting, dyspepsia, anorexia, diarrhoea, jaundice
- *CNS*—headache, blurred vision, dizziness, tremor, ataxia, paraesthesia, insomnia, amnesia, hallucinations, confusion, depression
- *Other*—reduced red/white blood cells or platelets, rash, ↑ANA, corneal deposits, photosensitivity.

Dosing

- Acute cardioversion of AF—2 mg/kg to a maximum of 150 mg over 15 min IV
- *Prevention of paroxysmal SVT/AF*—initially 50 mg BD PO; can increase by 50 mg BD every 3–5 days to maximum of 300 mg/day
- *Life-threatening ventricular arrhythmias*—initially 100 mg BD PO; increase by 50–100 mg/day to maximum of 400 mg/day.

This page intentionally left blank

Amiodarone

Class III antiarrhythmic agent (with weak class Ia, II, and IV effects). It is highly lipid-soluble and oral loading is prolonged (2–3 months), requiring saturation of lipid stores before a steady-state plasma level is reached. A similar length of time is required for amiodarone to be removed from the system. IV infusions provide a high plasma level within 1–2 hours, but levels fall rapidly once the infusion is stopped.

The potential for side effects is high, and amiodarone is reserved for when other drugs are unsuitable.

Main indications

- Control of acute atrial or ventricular arrhythmias where rapid return to sinus rhythm is required (⚠caution—may ↓BP if given by infusion)
- Recurrent arrhythmias difficult to control by other means
- Recurrent haemodynamically unstable VT—as adjunct to ICD
- Shock-refractory VF—IV 300 mg bolus

Mechanism of action

- Prolongs cardiac AP—↑refractory period via Na^+ and K^+ channel effects
- ↓automaticity of SA and AV nodes
- Coronary and peripheral vasodilator
- May non-competitively block α - and β -receptors.

Contraindications/cautions

- Hypersensitivity
- Bradycardia, sinoatrial or AV block—it is a weak AV node blocker
- Thyroid dysfunction
- ⚠ caution in pregnancy, respiratory disease, hepatic impairment and concomitant use with other drugs (digoxin, flecainide, procainamide, quinidine, warfarin, phenytoin, β - and Ca^{2+} -channel blockers)

Side effects

► All patients are sensitized to sunlight and should be warned to avoid strong sunshine, and wear suitable clothing and high-factor sun-cream if chronic amiodarone therapy is planned.

- *Cardiac*—hypotension (esp. if give by IV infusion), bradycardia, AV block, heart failure
- *Respiratory*—lung fibrosis (esp. with large cumulative long-term dose), eosinophilic lung infiltration, cough
- *GI*—hepatic enzymopathy, jaundice, hepatomegaly, hepatitis, cirrhosis
- *Eyes/skin*—corneal microdeposits, papilloedema, optic neuropathy, slate-grey skin discolouration
- *Endocrine*—hyperthyroidism, hypothyroidism
- *CNS*—abnormal taste, tremor, ataxia, weakness, peripheral neuropathy

Dosing

- IV (via central line)—if essential: 300 mg/1 hour then 900 mg/24 hours infusion (Box 18.1)

- Oral loading—200 mg TDS for 1 week followed by 200 mg BD for 1 week
- Maintenance dose—200 mg OD orally.

Box 18.1 Administration of IV amiodarone

The IV bolus and infusion of amiodarone should be administered through a central venous catheter whenever possible. If it has to be given peripherally then ensure it is given through a newly sited, large-bore cannula in a large peripheral vein (e.g. in the antecubital fossa) as extravasation of amiodarone may result in severe tissue damage.

Thrombophlebitis is a recognized iatrogenic complication of peripheral amiodarone.

Digoxin

A purified cardiac glycoside (derived from foxglove plant *Digitalis lanata*).

Main indications

- Ventricular rate control in AF/atrial flutter—primarily in older patients with a resting rate >100 bpm
- Congestive cardiac failure (particularly in presence of AF)—it has weak inotropic effects.

Mechanism of action

- Binds and inhibits α -subunit of Na^+/K^+ ATPase pump in membrane of cardiac myocytes, resulting in \uparrow intracellular Na^+ , slowing Ca^{2+} extrusion by exchange pump
- Lengthens AP
- \downarrow AV node conduction and \uparrow refractory period (thus \downarrow ventricular rate).

Contraindications

- 2° or complete heart block
- Accessory pathways, e.g. WPW syndrome
- VT/VF
- HCM
- ⚠Caution in hypokalaemia and metabolic acidosis (\uparrow digoxin toxicity), sick sinus syndrome, thyroid disease, hepatic or renal impairment
- Take care with concomitant use of other drugs (verapamil, amiodarone, erythromycin, warfarin)—digoxin competes for binding to albumin and may displace/be displaced by other albumin-bound drugs, with potentiation of effect of either the digoxin or the other drugs.

Side effects (mostly if toxic dose)

- Cardiac—arrhythmia (bigeminy, VT/VF, paroxysmal atrial tachycardia with variable AV block)
- GI—nausea/vomiting, anorexia, diarrhoea, abdominal pain
- CNS—headache, confusion, blurred vision, xanthopsia (yellow–green vision), drowsiness, dizziness, agitation, delirium, depression, psychosis.

Dosing

- Oral loading with 0.75–1.5 mg in 2–3 divided doses over 24 hours
- IV loading (if essential): with 500 mcg slow infusion followed cautiously by 125–250 mcg every 6–8 hours until clinical effect evident
- Maintenance dose of 62.5–500 mcg OD PO depending on response.

This page intentionally left blank

Digoxin toxicity

Chronic toxicity may occur as a result of interactions with other albumin-bound drugs (e.g. amiodarone) or from progressive renal failure. Digoxin has a long half-life (16–20 hours); the half-life of digitoxin (a related compound) is 6 days.

Toxicity is more common following acute overdose if the patient is already on digoxin, or cardiovascular disease is present (Boxes 18.2 and 18.3).

Clinical features

- Nausea and vomiting
- Dizziness, slurred speech, confusion, visual disturbances (blurring, alteration in colour perception) and hallucinations
- Hyperkalaemia
- Arrhythmias, hypotension, cardiac arrest
- Life-threatening toxicity rare in healthy hearts if <5 mg ingested. Those with cardiac disease are much more susceptible

Investigations

- ECG—marked sinus bradycardia, PR and QRS prolongation, sinus arrest, supraventricular arrhythmias, AV block, ventricular ectopics, VT, VF. A classical arrhythmia in chronic toxicity is paroxysmal atrial tachycardia with AV block
- Blood:
 - Serum digoxin level—immediate if acute overdose and severe toxicity present (digoxin antibodies being considered). Otherwise wait >6 hours post-dose. Normal therapeutic range 0.8–2.0 mg/L
 - Serum electrolytes (esp. K^+)
 - Magnesium.

Management

- Consider activated charcoal if <1 hour from ingestion
- Monitor for at least 6 hours
- Cardiac monitoring and frequent BP measurement
- Treat hyperkalaemia aggressively—but avoid calcium gluconate as it may precipitate VF
- Correct hypokalaemia with oral or IV K^+ supplementation
- Atropine for symptomatic bradycardia and AV block (1–2 mg IV)
- Lidocaine, atenolol, or amiodarone for VT
- Pacing wire if severe bradycardia/sinus arrest
- Digoxin-specific Ab (Digibind[®])—given in severe cases if $K^+ > 5.5$ mmol/L or a satisfactory cardiac output is not achieved in patients with sinus arrest, AV block, severe bradycardia, or tachyarrhythmias. Patients usually respond within 1 hour. Cardiac monitoring required for 24 hours; can cause $\downarrow K^+$, so monitor K^+ frequently. See Box 18.4 for dose.

Box 18.2 Predisposing factors for digoxin toxicity

- Acute hypoxia
- Electrolyte disturbance, esp. ↓K⁺
- Respiratory alkalosis
- Myocardial ischaemia
- Old age
- Drug interactions
- Impaired renal/hepatic clearance.

Box 18.3 Poor prognostic indicators

- Older patients
- Underlying cardiac disease
- Hyperkalaemia (>5 mmol/L)
- High-grade AV block
- Serum digoxin level >15 ng/mL
- VT.

Box 18.4 Digoxin-specific antibodies (Digibind[®]): dosing**Dosage for toxicity during chronic therapy**

- In adult patients in whom the steady-state digoxin level is known:

$$\text{Number of vials} = \frac{\text{Serum digoxin conc. (ng/mL)} \times \text{weight (kg)}}{100}$$

- In adult patients in whom the steady-state digoxin level is unknown, 6 vials of Digibind[®] (228 mg) usually reverses toxicity

Dosage for acute poisoning

- Methods for calculating dose are usually by an estimate of the amount of digoxin ingested in milligrams (**not** micrograms):

$$\text{Number of vials} = \frac{\text{Total dose ingested (mg)} \times 0.8}{0.5 \text{ (mg of digitalis bound per vial)}}$$

- 20 vials of Digibind[®] (760 mg) usually reverses acute toxicity if the amount ingested is unknown.

Statins

Hugely important cholesterol-lowering drugs.

Main indications

► Should be used routinely in all patients as 2° prevention for cardiovascular disease (including IHD, stroke, peripheral vascular disease, hypertension), unless contraindicated.

- Significantly ↓cardiovascular events and mortality with a wealth of trial data supporting their use
- Also used in 1° prevention for those at ↑risk of cardiovascular disease.

Mechanism of action

- Inhibit *HMG-CoA reductase* (rate-limiting enzyme in cholesterol synthesis) → up-regulation of LDL receptors and ↑LDL clearance
- ↓LDL, ↑HDL, ↓triglycerides
- Additional likely pleiotropic effects including improvement of endothelial function and plaque stabilization.

Contraindications

- Significant liver disease
- Pregnancy
- Untreated hypothyroidism
- ⚠Caution: ↑risk of rhabdomyolysis if used with other lipid-lowering agents.

Side effects

- Myalgia, myositis; rarely: rhabdomyolysis—usually reversible
- Headache
- GI disturbance
- Rash
- Paraesthesia
- Deranged LFTs.

Dosing

- Generally start with moderate statin (e.g. *simvastatin* 40 mg) and aim for the following targets:
 - Total cholesterol <4.0 mmol/L (or < 5.0 mmol/L for 1° prevention)
 - LDL <2.0 mmol/L (or < 3.0 mmol/L for 1° prevention)
 - HDL >1.0 mmol/L
- Change to stronger statin if required, e.g. *atorvastatin*, *rosuvastatin*
- Lifelong prescription once indicated
- All statins given once daily, at night:
 - *Simvastatin*—20–40 mg PO initially, max. 80 mg (but ↑toxicity at high dose)
 - *Pravastatin*—10 mg PO initially, max. 40 mg
 - *Atorvastatin*—10 mg PO initially, max. 80 mg
 - *Rosuvastatin*—5–10 PO mg initially, max. 40 mg.

This page intentionally left blank

Other lipid-modifying drugs

Fibrates

- Activate PPAR- α receptors primarily in muscle and liver
- Mainly lower serum triglyceride levels and \uparrow HDL
- Often used in combination with statins—but \uparrow risk of rhabdomyolysis
- Thought to improve insulin resistance and dyslipidaemia in type 2 diabetes (although no mortality benefit from trial data)
- *Side effects*—myalgia, GI disturbance, anorexia, erectile dysfunction, gallstones
- *Contraindications*—severe renal/hepatic impairment, 1^o biliary cirrhosis, nephritic syndrome, \uparrow risk of rhabdomyolysis when used with statins
- *Dose*:
 - *Bezafibrate*—200 mg TDS PO
 - *Fenofibrate*—200 mg OD PO
 - *Ciprofibrate*—100 mg OD PO
 - *Gemfibrozil*—600 mg BD PO.

Ezetimibe

- Inhibits cholesterol absorption from small intestine
- \uparrow uptake LDL-cholesterol in to cells
- Results in \downarrow serum cholesterol
- Often given in combination with statin but licensed for monotherapy
- No mortality benefit yet demonstrated
- *Side effects*—headache, dizziness, diarrhoea, myalgia, deranged LFTs, gallstones, hepatitis, pancreatitis, URTI, rhabdomyolysis
- *Contraindications*—concomitant use with statin in established liver disease
- *Dose*—10 mg OD PO.

Nicotinic acid (niacin/vitamin B₃)

- Blocks fat metabolism in adipose tissue; \downarrow serum free fatty acids, \uparrow HDL, \downarrow hepatic VLDL and \downarrow cholesterol secretion
- *Side effects*—abdominal bloating, diarrhoea, nausea/vomiting, flushing, cardiac arrhythmias, hypotension, rash, eczema, pruritis, acanthosis nigricans, dyspepsia, peptic ulceration, hyperglycaemia, gout, headache, toxic amblyopia, prolonged prothrombin time, \downarrow platelets, fulminant liver failure
- *Contraindications*—arterial bleeding, active peptic ulcers, breastfeeding, liver disease, diabetes, hypotension, glaucoma
- **⚠Caution**—unstable angina, MI
- *Dose*—usually given as modified-release preparation (Niaspan[®]) to minimize side effects; initially 375 mg OD PO at night, increasing to 1–2 g daily.

This page intentionally left blank

Antiplatelet agents

Aspirin (acetylsalicylic acid)

- ▶ Vitally important for 1° and 2° prevention of IHD and stroke.
- Protects against stroke in patients with AF at lower risk (see 📖 p.165)
- Given lifelong generally, once started
- Inhibits COX enzyme suppressing prostaglandin and thromboxane A₂ formation—responsible for platelet aggregation
- *Side effects*—GI ulcers, haemorrhage, tinnitus, bronchospasm, angio-oedema
- *Contraindications*—NSAID hypersensitivity, active ulcers, and ⚠caution in asthma, gout, hepatic/renal impairment and G6PD deficiency
- *Dose*—300 mg PO loading dose (ACS/TIA/stroke) then 75 mg daily.

Clopidogrel

- Protects against stent thrombosis (usually given post stent insertion—see 📖 p.60 for length of treatment)
- Reduces risk of non-fatal MI for up to 1 year post-NSTEMI
- Can substitute for aspirin in 1° or 2° prevention where aspirin intolerance exists, or augment aspirin where additional antiplatelet activity is required.
- Blocks adenosine diphosphate (ADP) receptor on platelet cell membranes to inhibit platelet aggregation
- *Side effects*—bleeding (GI, cerebral, mucosal), dyspepsia, nausea, diarrhoea, pruritis, depression, headache, confusion, myalgia, bronchospasm, renal/hepatic impairment, rash, TTP, neutropenia, erectile dysfunction
- *Contraindications*—hypersensitivity, acute bleeding/high bleeding risk (trauma, surgery) and ⚠caution in concomitant use with other antiplatelets/anticoagulants
- *Dose*—300 mg PO loading dose (acute MI/TIA/stroke) then 75 mg daily. 600 mg given orally before 1° PCI (unlicensed indication).

Glycoprotein (GP) IIb/IIIa inhibitors

- Used in treatment of ACSs, particularly when persistent symptoms despite maximal standard treatment
- Given during and post-acute angioplasty with or without intracoronary stent placement
- Block GP IIb/IIIa platelet surface receptors to inhibit platelet aggregation and thrombus formation
- Note given as IV infusion—↑mortality risk with oral preparations
- *Side effects*—bleeding, thrombocytopenia, GI upset, headache, bradycardia
- *Contraindications*—hypersensitivity, coagulopathy, active bleeding, vasculitis, cerebral neoplasia, recent surgery, recent stroke, thrombocytopenia and ⚠caution in concomitant use with other antiplatelets/anticoagulants
- *E.g.* Abciximab, Tirofiban, Eptifibatide

This page intentionally left blank

Newer cardiac therapies

The following drugs have recently become established agents in the treatment of ischaemic heart disease:

Ivabradine

- Rate-limiting antianginal agent
- Useful when β -blockers contraindicated or not tolerated
- Further uses include inappropriate atrial tachycardias
- Selectively inhibits I_f current—mixed Na^+/K^+ inward current regulating pacemaker activity in sinoatrial node
- *Side effects*—bradycardia, 1° AV block, headache, dizziness, blurred vision, luminous phenomena (sensation of brightness in visual fields), nausea, constipation, diarrhoea, palpitations, eosinophilia
- *Contraindications*—sick sinus syndrome, AV block, cardiogenic shock, severe heart failure, long QT syndrome, recent MI/stroke and concomitant use with CYP3A4 inhibitors (e.g. ketoconazole, erythromycin, nelfinavir)
- *Dose*—initially 2.5–5 mg BD PO then increase to 7.5 mg BD after 1 month.

Aliskiren

- First in a new class of renin inhibitors
- Licensed for treatment of hypertension
- *Side effects*—angio-oedema, hypotension, nausea, vomiting, dyspepsia, diarrhoea, cough, hyperkalaemia, light-headedness, dysphagia, gout, renal calculi, rash, haematuria, arthritis
- *Contraindications*—pregnancy, renal impairment, and ⚠caution in concomitant use with furosemide, atorvastatin or azole anti-fungals (ketoconazole)
- *Dose*—initially 150 mg OD PO; may increase to 300 mg OD.

This page intentionally left blank

Cardiotoxic drugs in overdose

Tricyclic antidepressants

Clinical features

- Anticholinergic—dry mouth, blurred vision, urinary retention
- Palpitation, supraventricular and ventricular arrhythmias
- Hyper-reflexia, extensor plantar responses
- Syncope, convulsions, absent brain-stem reflexes in severe cases.

Investigations

- ECG—sinus tachycardia, ↓P wave, prolonged PR interval, and QRS duration (>100 msec, significant; >160 msec, severe—risk of ventricular arrhythmias), supraventricular and ventricular arrhythmias (usually <6 hours)
- Blood—arterial blood gas (metabolic acidosis), U&Es.

Management

- Supportive measures including IV fluids ± inotropes
- Activated charcoal: 50 g orally if ingestion < 1 hour previously
- Na⁺ bicarbonate alters myocardial binding: give 50 mmol (350 mL of 1.26% or 50 mL of 8.4% [through a central line]) over 20 min if any of: pH <7.1; QRS duration >160 msec (even in the absence of acidosis); arrhythmias; significant hypotension
- In general, antiarrhythmic drugs should be avoided and aggressive measures to correct the underlying metabolic and clinical state (hypoxia, hypotension, acidosis, ↓K⁺) should be pursued instead
- IV diazepam for convulsions. ⚠ Phenytoin is contraindicated.

Theophylline

Clinical features

- Agitation, tremor, drowsiness, convulsions, status epilepticus
- Hypokalaemia, acidosis
- Sinus tachycardia, hypotension, SVT, VT, VF.

Investigations

- ECG—sinus tachycardia, SVT, VT, VF
- Bloods—U&E (esp. K⁺), Mg, arterial blood gases, theophylline levels.

Management

- Consider activated charcoal (50 g). Repeat 4-hourly if plasma theophylline >40 mg/L
- Monitor vital signs. Cardiac monitoring for >4 hours
- Check K⁺ and blood gases regularly (1–2 hourly in severe cases)—initial K⁺ may not reflect total K⁺ depletion and rebound hyperkalaemia may also occur during recovery
- IV fluids ± inotropes for hypotension
- Benzodiazepines or phenytoin for convulsions
- β-blockers or verapamil for symptomatic or compromising SVT (asymptomatic can be left untreated)
- VT—synchronized DC cardioversion or MgSO₄
- In very severe cases, haemodialysis may be required.

This page intentionally left blank

Recreational drugs with cardiac effects in overdose

Cocaine


Clinical features

- Euphoria, agitation, paranoia
- Sweating, hyperthermia, convulsions
- Tachycardia, hypertension, chest pain, pulmonary oedema
- Coronary/carotid spasm—can be severe enough to cause MI/stroke
- Intracerebral haemorrhage
- The patient may be violent and have a high pain threshold.

Investigations

- ECG—ST segment elevation/depression if coronary ischaemia, supraventricular and ventricular arrhythmias
- Bloods—U&Es, CK, arterial blood gases.

Management

- Cooling if core temperature $>41^{\circ}\text{C}$; aim for $<39^{\circ}\text{C}$ (tepid sponging, chilled IV fluids)
 - Diazepam[®] to control agitation or convulsions 5–10 mg IV
 - Nitrates may relieve myocardial ischaemia and lower BP, e.g. GTN 1–10 mg/kg/hour IV infusion
 - Adenosine 6–18 mg IV or verapamil 5 mg IV for sustained, haemodynamically tolerated SVTs
 - Phentolamine for hypertension and coronary spasm (2–5 mg IV bolus)
 - Thrombolysis or 1^o angioplasty should be considered if persistent ST segment elevation is present and there are no contraindications
 - Broad complex tachycardia can be treated with sodium bicarbonate (see  Tricyclic antidepressants, p.340 for dose)
- β -blockers should be avoided as they may be associated with unopposed α -receptor-mediated vasoconstriction, which can result in a sudden and severe increase in BP and coronary vasoconstriction.

Amphetamine

The cardiological features and management of amphetamine overdose are comparable to those of cocaine overdose.

Ecstasy (3,4-methylene-dioxy-methamphetamine, or MDMA)**Clinical features**

- Nausea, muscle pain, hyperthermia, ataxia, rhabdomyolysis
- Euphoria, agitation
- Hyper/hypotension, tachyarrhythmias
- Hyponatraemia, hyperkalaemia, ARDS.

Investigations

- *Blood*—U&Es (esp. Na⁺), LFTs, arterial blood gases
- *ECG*—sinus tachycardia or SVT.

Management

- *Cooling*—to ↓core body temperature to <39°C (e.g. tepid sponging, chilled IV fluids). Consider dantrolene (1 mg/kg IV over 15 min)
- *β-blocker* to treat narrow complex tachycardia e.g. metoprolol 5–10 mg IV
- Hypertension—Diazemuls[®] and/or nitrates IV.

Drug-induced QT prolongation

Many factors influence acquired QT prolongation, including genetic susceptibility (separate from congenital long-QT syndromes), metabolic state (including hypokalaemia and hypomagnesaemia), other concomitant drugs, and heart rate. The concurrent use of agents that prolong QT interval and/or inhibit hepatic cytochrome P₄₅₀ isoenzyme (e.g. fluoxetine) should also be avoided.

Thus the emergence of QT prolongation relies not just on the drug ingested, but on a combination of this and many predisposing factors. The occurrence with any particular drug is therefore unpredictable, but several drugs have been shown to be associated (Box 18.5):

► The main risk is of polymorphic VT (torsade de pointes) (📖 p.182).

Box 18.5 Some causative drugs

- | | |
|-----------------------------|---|
| • Class 1a antiarrhythmics | —quinidine, procainamide, disopyramide |
| • Class 1c antiarrhythmics | —flecainide |
| • Class III antiarrhythmics | —sotalol, amiodarone, dofetilide |
| • Tricyclic antidepressants | —amitriptyline, imipramine, clomipramine |
| • Psychotropic agents | —lithium, chlorpromazine, haloperidol |
| • Antihistamines | —terfenadine, loratidine |
| • Antimicrobials | —erythromycin, clarithromycin, quinine, chloroquine, ketoconazole |
| • Immunosuppressants | —tacrolimus |
| • Recreational drugs | —cocaine |

Clinical features

- Recurrent dizziness or syncope
- Palpitations
- Polymorphic VT /torsade de pointes.

Investigations

- ECG—VT, torsade de pointes (Fig. 18.1)
- Blood—serum electrolytes (esp. K⁺, Mg²⁺, Ca²⁺)

Management

- Identify and withdrawing the offending drug(s)
- Avoid empirical antiarrhythmic therapy
- For torsade de pointes:
 - MgSO₄—8 mmol (2 g) over 15 min, then 20 mmol over 6–12 hours
 - K⁺—keep at 4.5–5 mmol/L
 - Pacing—overdrive pacing for VT (📖 Box 10.11, p.185); prevention of VT in bradycardia with long QT (permanent pacing).

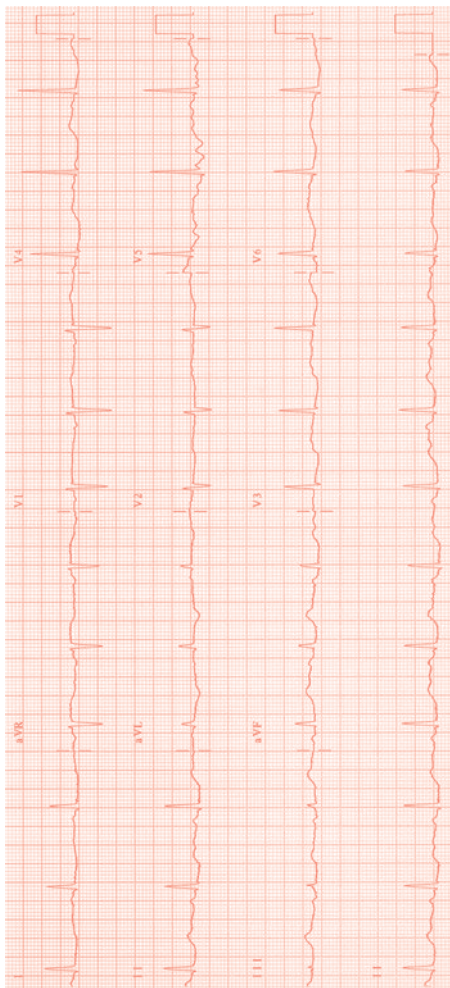


Fig. 18.1 Drug-induced long QT syndrome.

Drugs used in cancer

A number of oncological therapeutic agents are known to be cardiotoxic. In the majority, these effects are cumulative, but a number of medications have acute cardiac side effects:

Interleukin-2

- Causes a capillary leak syndrome (hypotension, oedema, effusions, arrhythmias)
- Stop infusion, administer steroids, antihistamines and consider adrenaline

5-Fluorouracil

- May cause myocardial ischaemia and acute MI
- Stop 5-FU treatment and treat with conventional antianginal therapy

Anthracyclines (e.g. doxorubicin, daunorubicin)

- Chronic dose-related cardiomyopathy
- Arrhythmias.

Herceptin

- Class III/IV heart failure
- Chronic dose-related cardiomyopathy
- Arrhythmias.

Others

- Cisplatin —acute myocardial ischaemia
- Cyclophosphamide —heart failure, haemorrhagic pericarditis
- Mitomycin C —myocardial injury
- Vincristine —MI
- Vinblastine —MI
- Taxol —bradycardia.

Miscellaneous conditions

Hypertensive emergencies 348

Traumatic heart disease 350

Cardiac tumours 352

ⓘ **Hypertensive emergencies**

A *hypertensive crisis* (previously termed 'malignant hypertension') occurs in <1% of patients. Severe prolonged elevation of BP (diastolic >130 mmHg) can result in end-organ damage, mostly affecting the CNS, kidneys, and cardiovascular system. Prognosis depends on the degree of end-organ damage, rather than the level of the BP. Survival rate has improved considerably and >90% of patients are alive at 1 year. See Box 19.1.

Presentation

- Angina, LV failure
- Headache, visual disturbance, irritability, altered consciousness, seizures (hypertensive encephalopathy)
- Nausea and vomiting
- Can occur in the setting of aortic dissection
- With haematuria or acute renal failure
- In association with catecholamine excess (phaeochromocytoma, recreational drug overdose)
- During pregnancy with eclampsia/pre-eclampsia.

Clinical signs

- Severe hypertension (>200mmHg systolic / 130mmHg diastolic). Check BP in both arms (?aortic dissection) and in the legs (?coarctation)
- Fundoscopy (retinal haemorrhages, exudates, or papilloedema)
- Full neurological examination (focal abnormalities)
- Examine for renal bruits (?renal artery stenosis).

Investigations

- 12 lead ECG (?LV hypertrophy, atrial arrhythmias)
- CXR (cardiomegaly)
- FBC (microangiopathic haemolytic anaemia), U&E, glucose, clotting studies (DIC)
- Urinalysis (haematuria)
- Further laboratory investigations (according to working diagnosis) include cardiac troponin, thyroid hormones, urine collections for catecholamines.

Management

- Patients are usually admitted to hospital for bed rest and monitoring
- Initial aim of BP management is to lower systolic pressure by 10% in the first hour and then by a further 15% in the next few hours
- Treatment can usually be commenced orally with a beta-blocker (e.g. atenolol) or long-acting calcium antagonist (e.g. amlodipine)
- IV antihypertensive therapy may be required if oral therapy is not effective, e.g. nitrates, nitroprusside, labetalol (see Box 19.2)
- In the longer term, a combination of beta-blockers, calcium-channel blockers, ACE-inhibitors, and other antihypertensives are often necessary to normalize BP.

Box 19.1 Hypertensive emergencies in specific conditions

Aortic dissection (📖 p.196)

A more rapid reduction in BP is required with a target systolic pressure of <120 mmHg.

Subarachnoid haemorrhage

Should be considered for treatment with nimodipine intravenously (0.5–2 mg/hour via central line) or orally (60 mg every 4 hours)

Phaeochromocytoma

Initial treatment with the alpha blocker phentolamine (2–5 mg intravenously) followed by beta-blockade if necessary. The risk of beta-blockade is of unopposed alpha-adrenoreceptor stimulation

Pregnancy

Some anti-hypertensive drugs are contraindicated. See 📖 p.248 for specific advice.

Cocaine abuse

May precipitate a hypertensive emergency. IV benzodiazepines and vasodilator therapy are recommended.

Monoamine oxidase inhibitors

Hypertension caused by monoamine oxidase inhibitors should be managed with benzodiazepines and with a short-acting antihypertensive such as sodium nitroprusside.

Box 19.2 Intravenous antihypertensive therapy

- **Labetalol** is a beta-blocker with alpha-blocking effects at high doses. It is given as an IV injection of 50 mg over 1 min followed by a continuous infusion of 1–2 mg/min
- **Esmolol** is a short-acting beta-blocker. It is administered as a bolus of 500 mcg/kg and as an infusion of 50–200 mcg/kg/min
- **Propranolol** is given as an IV injection of 1 mg over 1 min and repeated every 5 min until an adequate response has been achieved or a total of 10 mg has been given. Additional propranolol should then be given every 4 hours
- **Sodium nitroprusside** is given as an infusion of 0.5–1.5 mcg/kg/min increasing in steps of 0.5 mcg/kg/min every 5 min. Dose range 0.5–8 mcg/kg/min. It is usually given with a beta-blocker to prevent reflex tachycardia.

Traumatic heart disease

① **Blunt cardiac trauma**

- Usually occurs as a result of motor vehicle accidents, crush injuries, falls, prolonged cardiopulmonary resuscitation
- Injuries range from myocardial bruising to fatal cardiac rupture
- Non-fatal injury usually results in sub-epicardial or myocardial bruising
- Investigations for blunt cardiac trauma include:
 - ECG—T-wave changes (non-specific) or conduction abnormalities (bundle branch block)
 - Cardiac enzymes can be elevated (though not believed to be prognostically important)
 - Echocardiography may show regional wall motion abnormalities or a pericardial effusion
- Management is with bed rest, monitoring, and analgesia
- Complete recovery is the rule.

Commotio cordis

A cause of SCD, particularly in young men with no underlying cardiac disease. Impact to the precordium (usually from a baseball or other hard object) over the centre of the LV just before the onset of the T wave is believed to cause VF and sudden death.

🚑 **Penetrating cardiac trauma**

- ▶▶ Refer immediately to a cardiothoracic surgeon
- Stab and gunshot wounds are the commonest causes and usually affect the RV and LV (anterior structures)
- A large proportion of stab wounds to the heart present with pericardial tamponade whereas gun shot victims usually present with shock due to haemorrhage
- Immediate ultrasonography is indicated and if a pericardial effusion is visible in an unstable patient, urgent cardiothoracic intervention is required
- Pericardiocentesis is discouraged in acute trauma. The blood clots quickly and may be difficult to remove
- Do not remove a knife or other penetrating instrument unless instructed to do so by a cardiothoracic surgeon.

This page intentionally left blank

❓ **Cardiac tumours**

1° cardiac tumours are rare. 2° malignant deposits in the heart are more common. Three-quarters of primary cardiac tumours are benign and the majority of these are myxomas. Diagnosis is by echocardiography, MRI, and CT imaging.

Clinical features

- Cardiac symptoms and signs related to obstruction (dyspnoea from pulmonary venous congestion and pulmonary oedema, syncope)
 - Signs of systemic embolization (stroke, peripheral emboli, see 📖 p.228)
 - Systemic or constitutional symptoms (fever, weight loss, fatigue)
 - Arrhythmias (due to direct infiltration of the conduction tissue or myocardial irritation).
- ▶ Cardiac tumours are the great mimickers.

Benign tumours

Cardiac myxomas

Represent 50% of cardiac tumours. Rare forms are multiple (LAMB and NAME syndromes) and inherited (autosomal dominant). Usually present around age 50. Most commonly arise in the atria from the fossa ovalis. LA > RA. Symptoms and signs (clubbing, rash, 'tumour plop'—similar to S₃) similar to endocarditis, malignancy, and collagen vascular disease. Blood test may reveal anaemia, ↑CRP, ↑ESR. Echocardiography is normally diagnostic (Fig 19.1). Myxomas generally have a broad base but some are pedicled. Management is with surgical excision. Follow-up echocardiography is required as inadequate excision can lead to recurrence.

Papillary fibroelastomas

Often detected as small incidental lesions on the aortic and mitral valve. Fragments may embolize leading to coronary or cerebral obstruction (📖 p.228). Surgery is generally indicated to improve prognosis but small right-sided lesions may be monitored.

Others

- Rhabdomyoma (most common 1° cardiac neoplasm in children)
- Fibroma (most commonly resected childhood tumour)
- Haemangiomas
- Cardiac lipomas
- AV nodal tumours (small cystic mass—a cause of sudden cardiac death)

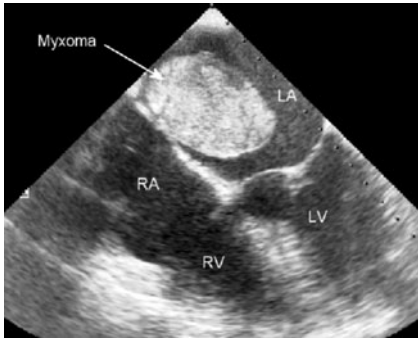


Fig. 19.1 Transoesophageal echocardiography demonstrating a large myxoma attached to the septum between the right atrium (RA) and left atrium (LA)

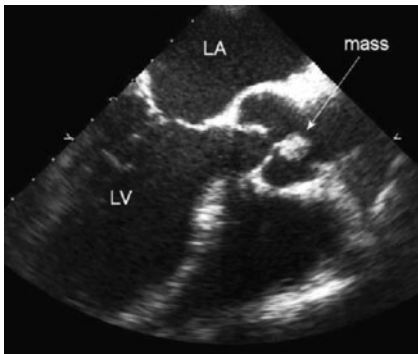


Fig. 19.2 Transoesophageal echocardiography revealing a mobile fibroelastoma attached to the aortic valve. LA, left atrium, LV left ventricle.

Malignant tumours***Metastatic cardiac tumour***

Much more common than primary cardiac tumours. Tachycardia, arrhythmias, heart failure in a patient with carcinoma should raise the suspicion. May present with pericardial effusion and/or tamponade. Associated malignancies include malignant melanoma, leukaemia, lymphoma, carcinoma of the stomach, liver, colon, rectum, and ovary.

Sarcomas

Extremely rare. May occur in any part of the heart but most commonly involve the RA. Includes angiosarcoma, osteosarcoma, leiomyosarcoma, rhabdomyosarcoma. Management is with a combination of surgery, chemotherapy, and radiotherapy. Outcome is generally poor with median survival <1 year.

Cardiac lymphoma

Radiological staging is required to distinguish between 1° cardiac lymphoma and generalized lymphoma. Management is usually with chemotherapy.

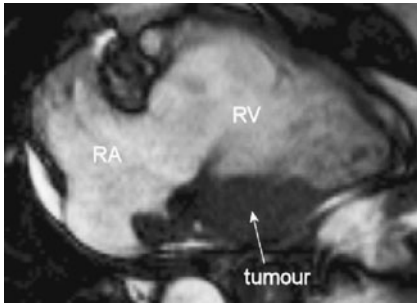


Fig. 19.3 Cardiac MRI of the right heart demonstrating a mass at the junction of the right ventricle (RV) and right atrium (RA). Subsequent biopsy confirmed myocardial infiltration with lymphoma.

This page intentionally left blank

Part 3

Practical issues

Chapter 20	Practical procedures	359
Chapter 21	ECG recognition	383

This page intentionally left blank

Practical procedures

- General considerations 360
- Central venous lines 362
- Pulmonary artery (Swan–Ganz) catheters 366
- Temporary pacing 368
- Inserting an arterial line 370
- Pericardial drainage (pericardiocentesis) 372
- Intra-aortic balloon counterpulsation 374
- Exercise stress testing 378

General considerations

There is always time to think

There are very few emergencies that require an *immediate* response. A focused period of reflection and planning, supported when required by the opinion and contribution of others, is an essential prelude to the successful performance of a practical procedure—especially in the demanding setting of an acute clinical problem.

Is the proposed procedure indicated?

This may seem an odd first question but is the correct starting point. Many a practical procedure is abandoned after prolonged, fruitless (and often painful and dangerous) attempts with an observation to the patient that ‘We can do without it’. Consider the indications for the proposed procedure and any special factors that may affect the likelihood of success or the risk. Review all alternative approaches to the problem. Commit to a procedure only if the intervention is considered essential or has much to offer, at a risk judged acceptable to your patient, ideally with informed consent though this may not always be possible or appropriate.

Do you have the skills to perform the procedure?

► *To thine own self be true.*

It is your professional duty to act within your established competence. Never hesitate to ask for help or guidance or to initiate referral to an appropriate specialist. This text aims to serve as a practical aide-memoire and is not a substitute for formal training and practical experience.

Even if experienced and confident in a procedure, never underestimate the role and importance of assistants or other professionals that will be involved (e.g. radiographers in temporary pacemaker insertion). The full range of skills will be required.

Do you have the setting and equipment for the procedure?

Remember the rule of the 13 Ps:

In the Performance of Practical Procedures, Proper Prior Preparation and Planning and Perfect Patient Positioning, Prevents Poor Performance.

- If appropriate, inform your senior cover of your intention and schedule
- Secure time, free of likely interruption—who will hold your bleep? Are there any competing urgent clinical concerns?
- Rearrange the room and furniture to secure optimum access. Adjust patient position, bed height, lighting, and remove obstructions
- Prepare and check all items of equipment that will be required
- For complex or unfamiliar procedures, perform a mental rehearsal—establish the sequence of your planned action; checklist all planned equipment requirements
- Ensure compatibility of items—will the pacing wire fit through the venous access line? Will the pacing wire fit to the pacing box?
- Prepare in advance items that do not demand sterile handling, e.g. infusions for central venous lines, transducers and monitors for pressure lines.

This page intentionally left blank

Central venous lines

Choice of approach

The 3 main approaches to central venous cannulation are:

- Internal jugular vein
- Subclavian vein
- Femoral vein.

You should aim to become familiar with at least 2 of these routes.

General points—applicable to all approaches

- Ultrasound guidance has emerged as a useful tool in central venous access (to locate the target vein and identify related structures). You should seek training in the use of these imaging devices and use them when they are available. The following points assume that a traditional surface anatomy approach is required
- Pay attention to sterility. Prepare the skin and drape the area with sterile dressings. Wear sterile gloves and gown
- Position the patient with head-down tilt. This fills the central veins, increasing their available size for cannulation and minimizes the risk of cerebral air embolization during the procedure.

Internal jugular approach

This has emerged as the most common route for central venous access. When compared to subclavian access, it has a lower risk of pneumothorax and allows compression haemostasis for patients with a disordered coagulation or following thrombolysis. It is also ideal for the application of ultrasound guidance methods. The line position may, however, be more uncomfortable for patients, and there may be an ↑tendency for displacement of temporary pacing wires. The right internal jugular is preferred to the left, as it is a straighter course to the SVC and avoids the thoracic duct.

The approach (Fig. 20.1)

(See Box 20.1 for details of technique.)

- Identify the apex of the muscle-free triangle between the clavicular and manubrial heads of the sternocleidomastoid muscle
- Palpate the line of the carotid artery and insert the needle lateral to this line at an angle of 45° to the skin, aiming for the right nipple area (or anterior superior iliac spine)
- The vein is superficial and cannulation should be achieved at a depth of a few centimetres. Do not advance beyond this, as the apex of the lung could be injured.

Box 20.1 Technique for central venous line insertion

- Whenever possible use the Seldinger technique (needle over guidewire). Catheter over needle devices (similar to peripheral IV cannulae) are more difficult to place
- Infiltrate the skin and SC tissue with 5–10mL lidocaine 1%
- Mount the needle on a syringe containing a few mL of normal saline
- Position the guidewire on the sterile field but within easy reach
- Make a small incision ('nick') the skin with a small (e.g. number 11) scalpel blade to facilitate advancement of the sheath/cannula
- Advance the needle, maintaining negative pressure by aspiration
- If the vein is not entered, withdraw the needle slowly maintaining syringe aspiration. Sometimes the needle transfixes the vein and cannulation is only evident on slow withdrawal
- After an unsuccessful pass:
 - Flush the needle to remove debris that may clog its lumen
 - Reassess the anatomical landmarks and identify a modified line for the next attempt. Be systematic in exploring the target region
- When the needle enters the vein and blood is aspirated, be prepared to make minor adjustments (advance or retract) to ensure free flow of blood
- Fix the needle with 1 hand and carefully remove the syringe
- Pass the flexible end of the guidewire (usually with 'J' tip) down the needle—the wire should pass with minimal resistance. Passage can sometimes be facilitated with minor rotation of the wire or needle (to change the angle of the bevel).
- If resistance persists, remove the wire and check the needle position by aspiration with a syringe before retrying
- When half of the wire is in the vein, remove the needle and place the sheath and its dilator over the wire.
- ► Do not advance the sheath into the body until a short length of wire is visible protruding from the rear end of the dilator and is secured with a firm grasp
- If there is resistance to insertion of the sheath, consider enlargement of the skin incision. If there is resistance in the deeper layers (e.g. clavipectoral fascia for subclavian lines) it may be necessary to first advance a dilator of smaller calibre (without its sheath) to open the track
- Once the line is in place remove the dilator and secure the cannula with suture and a transparent occlusive dressing
- Radiographic examination (penetrated films) can be used to check the line position but this investigation should not preclude emergency use of a line following uncomplicated insertion.

Subclavian approach

The subclavian approach allows access to the patient if the area around the patient's head is unavailable (e.g. during a cardiac arrest). A line inserted by this route lies on the anterior chest, is comfortable for the patient, and easy to manage. The main limitations of the approach are a risk of pneumothorax and an inability to apply pressure to the target vessels in the event of multiple venous or inadvertent arterial puncture.

► It is unwise to attempt immediate subclavian puncture on the contralateral side after an initial unsuccessful attempt as this may result in bilateral pneumothoraces.

The approach (Fig. 20.2)

(See Box 20.1 for details of technique.)

- Identify the junction between the medial 1/3 and lateral 2/3 of the clavicle. This is usually at the apex of a convex angulation as the clavicle sweeps laterally and cranially
- The skin incision point is 2 cm inferior and lateral to this point
- Infiltrate the skin and SC tissue at this point and up to the edge of the clavicle. Keeping the needle horizontal, move the needle tip gently down and behind the clavicle, infiltrating local anaesthetic
- Prepare the cannulation needle and follow the same initial track as the anaesthetic needle
- When the needle lies just below the clavicle, aim the needle at the nadir of the suprasternal notch
- Keeping the needle horizontal and parallel to the bed (avoiding lifting the hands off the body and angling the needle tip down) minimizes the risk of pneumothorax.

Femoral vein approach

The femoral approach allows easy cannulation of a great vein and is valuable in an emergency setting. The area can be compressed in the event of bleeding and temporary pacing can be achieved by this route. The main limitations relate to subsequent patient immobility and a probable ↑risk of line infection.

The approach (Fig. 20.3)

(See Box 20.1 for details of technique.)

- The patient should be lying flat with the leg slightly adducted and externally rotated
- Shave the groin, prepare the skin, and drape
- Palpate the femoral artery below the inguinal ligament, over or slightly above the natural skin crease at the top of the leg
- The femoral vein lies medial to the femoral artery
- Infiltrate local anaesthetic at the skin surface and deeper layers
- Advance the cannulation needle at 30–45° to the skin surface, parallel to the direction of the femoral artery
- The vein usually lies ~4 cm from the skin surface.

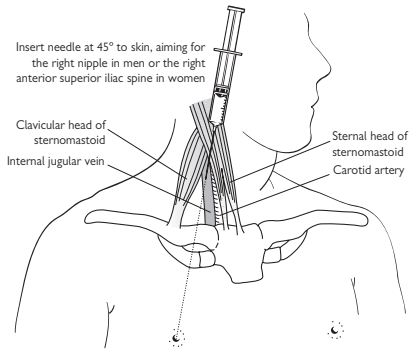


Fig. 20.1 Internal jugular central insertion.

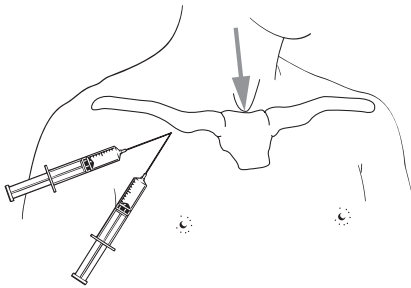


Fig. 20.2 Right subclavian vein central line insertion.

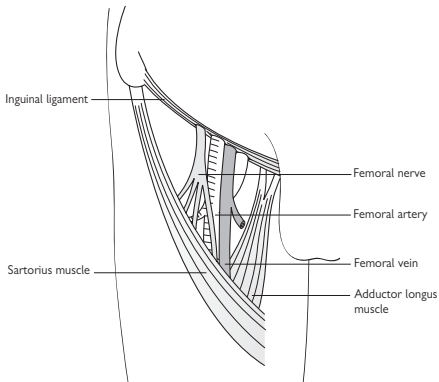


Fig. 20.3 Right femoral vein anatomy.

Pulmonary artery (Swan–Ganz) catheters

The main purpose of this intervention is to monitor intracardiac pressures. Other, more specialized catheters allow the calculation of indices of cardiac function and vascular resistance. They are, however, used less frequently in modern practice, as their usefulness is debated.

- Ensure that the correct equipment is available and prepared including the pressure transducers and monitors
- Connect the patient to ECG monitoring and insert a peripheral IV cannula
- Secure central venous access via internal jugular (📖 p.366) or subclavian routes (📖 p.368) using a special sheath designed to allow the introduction of PA catheters
- Prepare the catheter by flushing its internal lumens—usually labelled distal, mid, and proximal, describing the exit lumen in the catheter. Most catheters include a soft balloon, inflated with air and designed to encourage floatation of the catheter tip (with blood flow), through the right heart and into the pulmonary vasculature. Test this balloon with inflation/deflation
- Attach real-time pressure monitoring to the distal channel of the catheter and insert into the great veins to a depth of 8–10 cm
- Inflate the balloon to encourage flow through the right heart. Deep inspiration can encourage passage across the tricuspid valve
- Progress of the catheter can be assessed with X-ray screening but the more usual method is to observe the characteristic waveforms recorded in the RA, RV, and in the pulmonary artery (Fig. 20.4). The right ventricle is usually entered at a catheter length of 25–35 cm and the pulmonary artery at 40–50 cm
- Ventricular ectopics and some non-sustained VT can occur during passage but do not demand treatment in the absence of circulatory collapse
- Do not continue to advance the catheter if there is no progress. This risks knot formation with the catheter coiling in a chamber. Deflate the balloon, withdraw to the RA, and attempt another passage. In patients with low cardiac output or established right heart pathology specialist help with X-ray imaging may be required
- When in the pulmonary circulation, advance the catheter tip to a position where the wedge pressure can be measured when the balloon is inflated. Deflation of the balloon between readings minimizes the risk of trauma or rupture of a pulmonary vessel
- A good wedge tracing exhibits a classic LA pattern with 'a' and 'v' wave morphology (if the patient is in sinus rhythm)—see Fig. 20.4 and Box 20.2. It is lower or equal to the PA diastolic pressure and has no dichrotic notch, seen in most PA tracings. The wedge pressure usually fluctuates with respiration. If the pressure tracing is damped and tends to increase in a ramp fashion this implies 'overwedging' and partial balloon deflation or catheter withdrawal may be required.

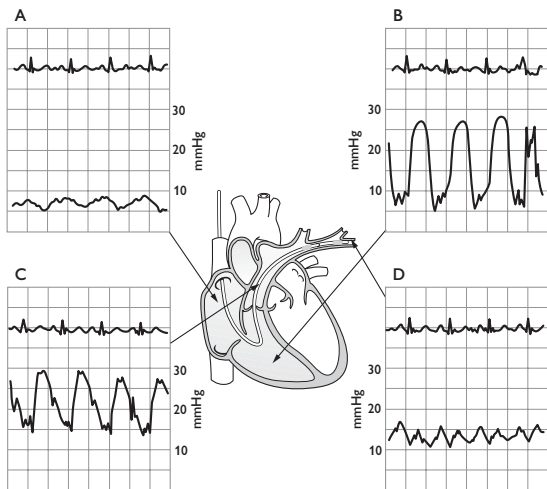


Fig. 20.4 Right heart catheterization. In each panel, the ECG is shown at the top with the corresponding pressure trace from the distal port of a PA catheter at the bottom. The characteristic pressure traces indicate the position of the catheter as it traverses the right heart. Record the pressures obtained from each location and the systemic arterial BP.

A) (Top left.) RA pressure trace in sinus rhythm. Atrial pressure is clearly lower than that of RV or PA. The 'a' wave coincides with atrial contraction while the 'v' wave reflects atrial filling against the tricuspid valve (closed during RV systole). The 'a' wave will be absent in AF. Large 'v' waves are indicative of tricuspid incompetence.

B) (Top right.) The RV pressure trace is characterized by large swings in pressure that correspond to RV contraction and relaxation.

C) (Bottom left.) In the PA, the systolic should be equal to RV systolic (in the absence of RVOTO or pulmonary stenosis). Note the diastolic notch corresponding to closure of the pulmonary valve.

D) (Bottom right.) PCWP. With the PA catheter balloon inflated, the distal port is insulated from the right heart and it is effectively exposed to LA pressure. In the absence of PE or pre-capillary pulmonary hypertension then PA diastolic pressure should approximate closely to PCWP.

Box 20.2 Normal ranges


- RA 0–8 mmHg
- RV systolic 20–25 mmHg; diastolic 6–12 mmHg
- PA systolic 20–25 mmHg; diastolic 4–8 mmHg
- PCWP 6–12 mmHg.

Temporary pacing

See  p.139 for indications

► Consider external pacing or pharmacological support (atropine and/or isoprenaline) if immediate support for haemodynamic compromise due to bradycardia is required.

Transvenous pacing wire insertion

- Insert a peripheral IV cannula and connect an ECG monitor—using limb leads to avoid external wires over the chest that will be visible when screening with X-rays
- Use full sterile precautions
- Secure central venous access ( Central venous lines, p.362) with a sheath of larger diameter than the temporary wire to be used
- Under X-ray screening, advance the pacing wire into the RA. The wire has a J-shaped distal contour which allows the tip to be directed by rotation
- Direct the wire towards the apex of the RV (this lies just medial to the lateral border of the cardiac silhouette on AP screening) (Fig. 20.5)
- If the wire does not move directly over the tricuspid valve it may be necessary to form a loop of wire in the atrium, usually achieved with the tip on the right lateral border of the atrium. Rotation and advancement of the wire may then result in prolapse through the tricuspid valve
- As the wire enters the ventricle, some ectopic activity is usual and helps confirm a ventricular position
- The wire can enter the coronary sinus (which drains venous blood from the myocardium to the RA), the orifice of which lies just above the tricuspid valve. A wire in the coronary sinus appears more cranial on AP screening and on a lateral view moves posteriorly) rather than the desired anterior direction of an RV position)
- Manipulate the wire so that the tip curves downwards to the apex of the ventricle (Fig. 20.5). In its final position the line of the wire should resemble the heel of a sock in the RA, with the toe in the apex of the RV
- Connect the lead to the pacing box and test the threshold for capture
- Test the stability of the lead position by observing lead motion and the ability to pace the heart during patient manoeuvres of deep inspiration, coughing, and sniffing
- Suture the lead to the skin close to the entry point and apply transparent occlusive dressings
- Secure the external portion of the lead with tape or other fixatives.

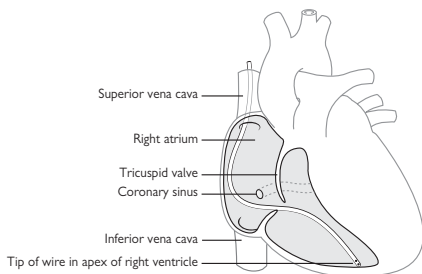


Fig. 20.5 Temporary pacing wire position.

Box 20.3 Configuring the pacemaker settings

- Set to **Demand** at a **rate** of 60–80 bpm
- The pacemaker will, on a beat-to-beat basis, **pace** when it does not detect ventricular activity above that rate
- The red **pace** light will illuminate on each occasion
- When the spontaneous ventricular rate is above the pacemaker rate, the box will inhibit and the red **sense** light will illuminate
- An **output** voltage set to at least $3 \times$ pacemaker threshold will ensure that each impulse ‘captures’ the ventricle
- The **SENSITIVITY** should be adjusted to ensure that each intrinsic beat is detected but that skeletal muscle interference does not lead to pacemaker inhibition—the lower the setting, the more sensitive the pacemaker.

⚠ Ensure that the pacemaker is set to DEMAND. Asynchronous pacing risks inducing ventricular arrhythmias.

⚠ Note that instigating pacing may lead to pacemaker dependence.

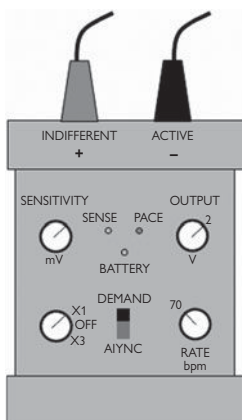



Fig. 20.6 Diagram of a typical temporary pacing box.

Inserting an arterial line

Although the femoral and brachial arteries can be used, the best approach is via the radial artery. This is a superficial vessel, easily palpated at the wrist medial to the radial styloid. In the vast majority of people, a dual blood supply to the hand (via the ulnar artery and palmar arch) ensures adequate distal limb perfusion even if the radial artery is occupied by a catheter or closes by subsequent thrombosis.

Procedure

- Position the patient's hand palm upwards. Place a support (bandage roll or 500mL fluid bag) to support the lower forearm and allow the wrist to rest in passive extension
- Prepare (sterile field) and drape the wrist
- Infiltrate local anaesthetic at the skin surface and superficial SC layer
- Use a special radial artery catheter pack with small calibre needle, guide wire and cannula (Seldinger technique)
- Palpate the radial pulse.
- Aim to cannulate proximal to the flexor skin creases to avoid the tough flexor retinaculum
- Advance the needle at 45° to the skin. As the artery is entered blood flow is observed in the needle hub
- Insert guidewire and cannula following the pattern of central venous line insertion ( Central venous lines, p.362)
- Secure the cannula and attach a pressure monitoring line, transducer, and flush facility.

This page intentionally left blank

Pericardial drainage (pericardiocentesis)

Emergency drainage of the pericardial space is usually performed for the management of cardiac tamponade. When known or suspected tamponade has created a cardiac arrest situation, the procedure can and should be performed as an immediate and potentially life-saving measure (Box 20.4). In other, less critical, cases echocardiography should be performed first. This allows confirmation of the diagnosis and provides important information about the wisdom of and approach to pericardial aspiration.

Aspiration should only be attempted if there is a substantial fluid collection between the pericardial layers at the access point of intended drainage (>2 cm echocardiographic separation). Following cardiac surgery or with certain chronic and infective aetiologies, there can be localized tamponade of a cardiac chamber, not amenable to percutaneous drainage, and expert cardiac surgical advice should be sought for this.

Location and imaging

Both emergency and elective procedures can be performed without imaging but most authorities now recommend some form of guidance. A cardiac catheterization laboratory is the ideal environment with radiographic screening and pressure monitoring, though this is not essential, and echocardiographic imaging is commonly used. Some older texts refer to the use of ECG monitoring connected to the aspiration needle, though this is difficult to achieve with modern ECG recording equipment.

The subxiphisternal approach

- Position the patient at 45° to encourage pooling of the effusion at the inferior surface of the heart
- Prepare the skin and drape the patient in sterile fashion
- Conscious sedation may be required
- Infiltrate local anaesthetic along the drainage track
- The skin incision point lies just below the xiphisternum. Use a scalpel blade to make a small incision to reduce skin friction for the passage of the drainage catheter
- Advance the needle just under the costal margin, advancing behind the sternum, and aiming towards the tip of the left scapula
- Maintain negative pressure on an attached syringe and observe for the aspiration of fluid
- Remove the syringe and advance the guidewire through the needle so that it loops in the cardiac shadow on X-ray screening or is visible in the pericardial space with echo (bubble contrast may help to confirm position)
- Advance a dilator over the wire
- Advance the drainage catheter over the wire and into the pericardial space
- Initially fluid can be aspirated with a syringe—including samples for biochemical, immunological and microbiological analysis. Following this, the drainage bag is connected
- The drain is secured with sutures at the skin entry point and dressed with transparent occlusive dressings.

Box 20.4 Emergency situations (see also p.83)

Insertion of a pericardial drain requires specialized equipment (see Box 20.5). In a critical situation, however, symptoms and haemodynamic compromise will improve (at least in the short term) with simple drainage, sometimes of modest volumes of fluid. This can be achieved with simple aspiration using a syringe and a standard 'white' venepuncture needle or IV cannula, inserted at the position of the apex beat and directed towards the heart. This '*apical*' approach' can also be used for inserting a drain, with appropriate echocardiographic guidance.

Box 20.5 Key equipment

A variety of manufacturers now supply composite pericardial drainage packs but the key items of equipment include:

- Long needle (15 cm) of at least 18G calibre,; a short bevel is an advantage to avoid potential cardiac laceration
- 'J' tip guidewire—0.035" (0.89mm) diameter
- Dilator (5–7 Fr)
- Pigtail or other drainage catheter with multiple side-holes on the distal shaft
- Large calibre syringe for initial aspiration
- Drainage bag and connecting tubing.

Intra-aortic balloon counterpulsation

► The insertion, setup and maintenance of an IABP is a specialist skill beyond the scope of this text. This device can however be valuable, sometime life saving, and those involved in the management of acute conditions should be aware of its potential. The following points may be of value in managing patients under your care, and it may be possible to make some initial preparation to assist a cardiac team en route to your patient.

Practical considerations

- Most patients receive systemic anticoagulation with IV heparin
- IABP therapy is less effective in patients with tachycardia, especially if the rhythm is irregular. These patients may need specialist review with inflation/deflation cycles being triggered by changes in aortic pressure rather than the surface ECG
- In the event of IABP failure (balloon rupture, exhausted helium supply, ECG trigger failure) pumping must be resumed in 20–30 min or the balloon catheter removed. A static IABP is a potential source of clot formation and distal arterial embolization
- Some patients require weaning from IABP support. The usual method is to reduce the balloon inflation frequency to every second, and later to every 3rd cardiac cycle
- Though it is possible to draw arterial blood samples from the pressure monitoring line of an IABP, this should be avoided as the calibre of the line is narrow and prone to blockage if contaminated with blood.

Preparation for IABP insertion

- An IABP can be inserted in a general ward area but many centres prefer insertion to take place in a facility with radiographic screening and improved sterility. Ask if you should secure the use of a cardiac catheterization laboratory or other clinical area
- Shave and clean both groins and the anterior aspects of both thighs
- Position extra ECG monitor electrodes for use by the IABP system
- Check and document the peripheral pulses in the lower limbs
- Check clotting status.

Box 20.6 lists the indications for IABP insertion and Box 20.7 gives a brief description of how IABPs work.

Box 20.6 IABP insertion—indications (see also p.83)**Indications**

- Cardiogenic shock
- Severe pulmonary oedema
- Acute LV dysfunction, e.g. MI, with severe cardiac failure
- Acute severe MR with cardiac failure, e.g. post-MI
- VSD with severe cardiac failure, esp. post-MI
- Intractable myocardial ischaemia
- Support during CABG and coronary angioplasty.

Contraindications

- Significant AR
- Significant AS
- Hypertrophic obstructive cardiomyopathy with significant gradient
- Thoracic aortic pathology, e.g. dissection, aneurysm, clot
- Significant peripheral vascular disease—relative contraindication.

Cautions

- May sometimes worsen renal blood flow
- Peripheral vascular compromise can occur, usually affecting the leg on the side of insertion, though ischaemia of the contralateral limb can also occur. A cold, pale, and painful limb with reduced pulses demands immediate specialist attention.

Box 20.7 How IABPs work

- A long (34 or 40 cm) balloon is placed in the proximal descending aorta, nearly always via an entry site in the proximal femoral artery (as for an angiogram). Rapid expansion of the balloon in diastole displaces blood and promotes flow distally to the mesenteric, renal, and lower limb vessels
- Augmented flow also occurs proximal to the balloon, to the head and neck vessels, and coronary arteries
- Flow in coronary vessels mainly occurs in diastole and use of an IABP is associated with a substantial improvement in coronary perfusion
- Abrupt balloon deflation at the start of systole decreases the afterload resistance to LV contraction, improving performance, and decreasing cardiac work
- The balloon is inflated and deflated with helium via a pressurized line, fed from a reservoir cylinder
- Inflation and deflation cycles are timed from the surface ECG and adjusted so that the balloon inflates immediately after aortic valve closure and deflates at the end of diastole.

IABP removal

If the device ceases to function and regular balloon inflation and deflation cycles cannot be restored, the intra-vascular balloon should be removed within 20–30 min, as it creates a significant risk of clot formation in the descending aorta.

► The puncture hole in the artery is large however (at least 7.5 Fr in size; diameter ~2.7mm) and there is a risk of bleeding, bruising or other vascular compromise on removal. **Do not remove an IABP unless you are competent in the manual compression of arteries following the removal of large bore catheters**

Procedure

- Stop IV (unfractionated) heparin and aim for ACT <200, as a guide
- Remove the dressings over the balloon pump insertion site and any further dressings along the line of the balloon shaft down the thigh
- Identify and cut any sutures, placed to secure the device
- Inject 10 ml of 1% lignocaine into the SC tissues around the puncture site
- Consider pre-medication with an opiate
- Have ready and available 600 mcg of atropine and a unit of IV fluids as vagal reactions with bradycardia and hypotension are common following the removal of large-bore arterial lines
- Switch off balloon inflation
- Prepare a receiver surface for the balloon pump (e.g. incontinence pad) as the IABP is very long and will be covered with blood
- IABP catheters can be inserted directly or via a sheath into the femoral artery. At the time of removal, the used balloon will not however retract through the sheath. If a sheath is present, the IABP catheter should be withdrawn slowly until the balloon reaches the sheath. At this point resistance will be encountered.
- Place 2 or 3 fingers of 1 hand over the presumed arterial puncture site (2–5 mm cranial to the skin puncture site).
- The sheath ± balloon catheter are pulled out together as a single unit
- Maintain firm pressure to secure haemostasis over a 10–15-min period, until haemostasis occurs
- Insist on continued flat bed rest for at least 2 hours following sheath removal.

This page intentionally left blank

Exercise stress testing

The exercise ECG is a widely available, well-established, inexpensive test designed for investigating exercise tolerance and potential IHD. The predictive value is affected by the pretest probability of IHD based on symptoms and risk factors. Patients with a low pretest probability will have a high rate of false positive tests.

- Overall sensitivity 68% and specificity 77% for the diagnosis of IHD
- Specificity is reduced in females and in patients with diabetes.

Performing the exercise test

- Prior examination and ECG are important to assess contraindications and conditions making interpretation unreliable (see Box 20.8)
- Full resuscitation equipment must be available
- Continuous ECG monitoring, BP, and workload are recorded
- The exercise treadmill is the most common modality used, often with the Bruce protocol which has been extensively validated. It involves a series of 3-min stages of increasing incline and speed
- The modified Bruce protocol is often used for risk stratification of patients 5–7 days after an ACS and in those with reduced mobility. It adds 2 low-workload stages at the beginning of the standard Bruce protocol.

Test endpoints

Generally there is little clinical reason to continue a Bruce protocol beyond 12 min, as any additional information gained is unlikely to be of diagnostic or prognostic significance. There are a number of reasons to terminate an exercise tolerance test:

Patient determined

- Patient wants to stop or is unable to maintain exercise
- Significant chest discomfort
- Marked fatigue or severe dyspnoea
- Other limiting symptoms.

Operator determined

- Patient looks unwell
- Exertional hypotension (systolic BP lower than pre-test standing BP)*
- Systolic BP >250mmHg or diastolic BP >120mmHg.

ECG endpoints

- Planar or downsloping ST segment depression (usually ≥ 1.5 mm)*
- ST elevation*
- New bundle branch block* or AV block
- Ventricular tachyarrhythmias*
- Supraventricular tachyarrhythmias.

Protocol-determined endpoints

Achieving $\geq 85\%$ of the maximal predicted heart rate for age (or 70% if post ACS).

*Also suggests a positive test.

Conditions making ECG interpretation unreliable

Not suitable for exercise tolerance testing if ECG changes are important for assessment, but exercise tolerance may be reliably assessed.

- Pre-excitation—WPW syndrome
- Paced ventricular rhythm
- More than 1 mm of ST depression at rest
- Complete LBBB
- RBBB—makes interpreting ECG changes in leads V1–V3 unreliable
- Patients taking digoxin
- ECG criteria for LV hypertrophy
- Electrolyte abnormalities, esp. hypokalaemia.

Box 20.8 Indications, contraindications, and complications for exercise stress testing

Common indications

- Assessment of patients with suspected IHD
- Risk stratification following ACSs
- Prognosis and management in patients with medically-treated stable angina, or those with known IHD who develop worsening symptoms
- Other indications include:
 - Preoperative evaluation
 - The assessment and response to treatment of selected patients with arrhythmias.

Contraindications

Absolute

- Symptomatic severe AS
- Uncontrolled symptomatic heart failure
- Acute MI—within 2 days
- Unstable angina
- Acute myocarditis or pericarditis
- Acute PE
- Acute aortic dissection.


Relative

- Left main coronary stenosis
- Severe hypertension—systolic ≥ 200 mmHg /or ≥ 110 mmHg
- Tachyarrhythmias with uncontrolled ventricular rate, e.g. AF
- Mental or physical impairment leading to inability to cooperate
- High degree AV block.

Complications

- Although rare, exercise testing can be associated with serious complications
- For every 10,000 tests there are approximately 3.5 MIs, 4.8 serious arrhythmias, and 0.5 deaths.

Interpreting exercise tests (Box 20.9)

- If a patient completes 12 min of the Bruce protocol without symptoms or ECG changes, it represents a negative test for cardiac ischaemia and puts the patient in a low-risk group for cardiovascular events
- Tests terminated prematurely for any of the reasons highlighted in  Test end-points, p.378, have to be interpreted carefully to manage the patient appropriately
- Be careful about signal-averaged ECGs (often labelled 'linked medians' or have a '*' on them)—these can include artefact and under- or over-report ST segment change. Computer generated reports often don't recognize these artefacts—always examine the raw data alongside computer-averaged traces.

Indicators of a 'positive' test

- Significant anginal symptoms, esp. if accompanied by ECG changes
 - Significant planar or downsloping ST segment depression (≥ 1.5 –2 mm in lateral leads at 80 msec beyond 'J' point)
 - ST elevation
 - New bundle branch block
 - Ventricular tachyarrhythmias
 - Exertional hypotension—systolic BP lower than pretest standing BP
- Exercise time is important—a low distance covered indicates poor functional reserve and in itself can be an indicator of poor prognosis, even without other changes (esp. <3 min. of a Bruce protocol).

Box 20.9 Duke scoring

The Duke University treadmill score is the most popular validated scoring system that risk stratifies patients based on three exercise parameters:

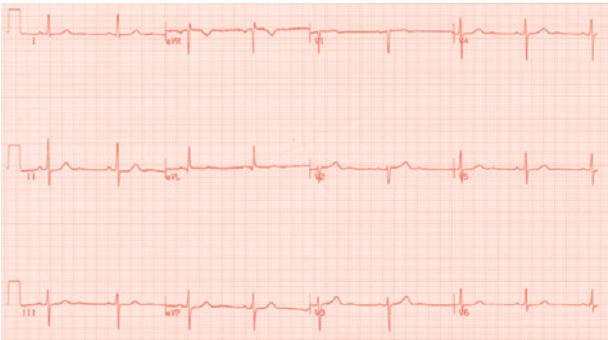
Score = **exercise time** (minutes based on the Bruce protocol)
 minus (5 x maximum **ST segment deviation** in mm)
 minus (4 x **exercise angina** [0= none, 1= non-limiting, 2= limiting])

	Score	5-year survival
Low risk	$\geq +5$	97%
Moderate	-10 to +4	90%
High risk	≤ -11	65%

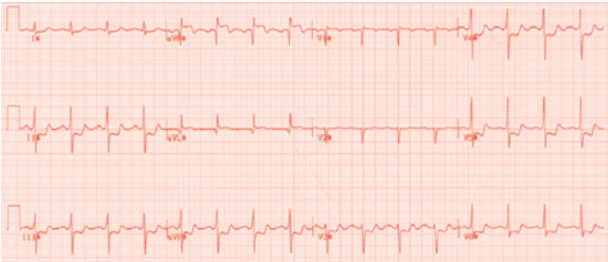Further management

- Patients with significantly positive tests or high-risk Duke scores will generally be considered for coronary angiography
- The management of patients with intermediate scores or inconclusive tests will be based on the clinical picture. This may involve further non-invasive testing or coronary angiography.

A



B



C

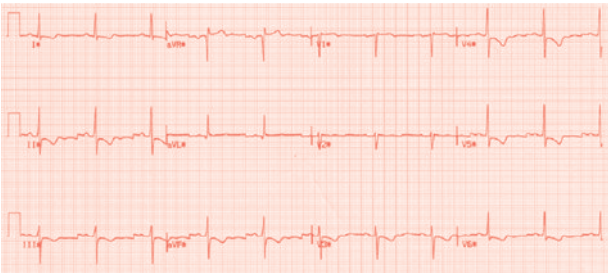

Fig. 20.7 Exercise ECG recordings at rest (A), peak exercise (B), and recovery (C) of a patient presenting with exertional chest pain. Note the significant downsloping ST depression in multiple lead groups during exercise that persists into recovery suggestive of significant coronary disease.

Other (imaging) modalities of stress testing**Indications**

- Patients unable to perform an exercise test
- Resting ECG abnormalities making interpretation unreliable
- As further assessment of equivocal exercise ECG tests.

These give prognostic information independent of exercise treadmill performance and underlying risk factors. Used in combination with exercise treadmill testing, they can vastly improve the positive and negative predictive values of each test used alone.

The stress involved with imaging may be provided by exercise or by pharmacological methods (e.g. dobutamine, dipyridamole, or adenosine)

Choice of test

- Available tests:
 - Stress echocardiography—with dobutamine
 - Myocardial perfusion imaging
 - CMR imaging—with adenosine for perfusion assessment, or dobutamine for functional assessment
 - PET scanning
- Choice largely depends on the availability of the test and local expertise
- The 2 most common modalities are stress echocardiography and myocardial perfusion imaging
- All have similar accuracies and positive and negative predictive values.

ECG recognition

- Physiology of the ECG 384
- Interpreting the ECG 386
- The current of injury 388
- Helpful tips 392
- Bundle branch block 394
- ECG library 398
 - Anterior myocardial infarction 399
 - Anterolateral myocardial 400
 - Inferior myocardial infarction 401
 - Inferolateral-posterior myocardial infarction 402
 - Myocardial ischaemia 403
 - Pericarditis 404
 - Pulmonary embolism 405
 - Pulmonary hypertension 406
 - Left bundle branch block 407
 - Right bundle branch block 408
 - Trifascicular block 409
 - Junctional rhythm 410
 - First degree heart block 411
 - Second degree heart block (Mobitz I) 412
 - Complete heart block 413
 - Atrial fibrillation 414
 - Pre-excited atrial fibrillation 415
 - Atrial flutter 416
 - Atrial tachycardia 417
 - Supraventricular tachycardia (AVNRT) 418
 - Supraventricular tachycardia (AVRT) 419
 - Pre-excitation 420
 - Ventricular tachycardia 421
 - Ventricular fibrillation 422
 - Accelerated idioventricular rhythm 423
 - Long QT 424
 - Brugada syndrome 425
 - Hypertrophic cardiomyopathy 426
 - Arrhythmogenic right ventricular cardiomyopathy 427
 - Single chamber pacemaker 428
 - Dual chamber pacemaker 429
 - Pacemaker lead failure 430

Physiology of the ECG

Electrical conduction

- Electrical spread may be facilitated either by direct cell-to-cell depolarization (e.g. in the atria), or, as in the ventricles, via a specialized conduction system, termed the *His–Purkinje system*
- Cell-to-cell depolarization is relatively slow, producing more slurred, widened patterns of tracing, e.g. P waves, delta waves
- His–Purkinje conduction is rapid, giving rise to the sharp deflections as normally seen in the QRS complex
- For example, in bundle branch block (📖 p.394), conduction through the ventricles is initially via the His–Purkinje system, and so begins as a sharp deflection in the QRS complex, followed by cell-to-cell depolarization which leads to QRS prolongation (>120 msec by definition in bundle branch block)
- In pre-excitation (📖 p.392, 420) the ventricles are starting to depolarize via an anomalous ('accessory') pathway before the His–Purkinje system, thus the complex begins slurred before becoming sharper (depending upon the balance of activation between the accessory pathway and His–Purkinje system).

The origin of the waves of the ECG

- A single cardiac myocyte produces an electrical signal when it 'fires' (depolarizes), followed by another signal when it 'recovers' (repolarizes)
- The P wave represents atrial depolarization. It occurs from cell-to-cell, and thus is relatively slow in onset and duration giving a typical broad 'dome' shape
- The QRS wave is produced from depolarization via the His–Purkinje system. It is normally fast, and the whole of the RV and LV myocardium is depolarized in under 120 msec—hence the normal QRS duration of ≤ 120 ms
- The T wave represents ventricular repolarization ('resetting'). Thus measuring the onset of the QRS until the end of the T wave gives a measure of the time taken for ventricular myocytes to depolarize and repolarize ('fire and reset'). This is termed the QT interval.

This page intentionally left blank

Interpreting the ECG

The art of ECG recognition

ECG interpretation is a fundamental art of medicine. Basic principles are learnt and applied to each and every ECG encountered. Time and experience makes 'pattern recognition' possible. Combining both pattern recognition and fundamental principals is the cornerstone to the 'art of ECG recognition'. The following points will hopefully aid the reader to understand some aspects that are traditionally not well explained. The ECG recordings included hereafter will have salient features pointed out, and hopefully act as an aid for pattern-recognition.

Key points

- ▶ The changing ECG should be regarded as the hallmark of ischaemic heart disease until proven otherwise.
- ▶ The diagnosis of ischaemia is not made on the ECG alone.
- An electrogram can be recorded from any site upon the body surface; however, convention dictates a 12 different electrode configuration to produce what we know as *the routine 12-lead ECG*
- Other electrode configurations may be of use clinically (RV electrodes, and posterior electrodes)

Leads and direction of electrical activity

Each ECG lead 'looks at' a mean voltage of the entire electrical activity in the heart from a particular 'point of view' (Fig. 21.1 and Tables 21.1 and 21.2).

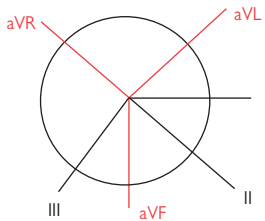
- An electrical wavefront moving towards an electrode appears as a positive deflection above the isoelectric line
- An electrical wavefront moving away from an electrode appears as a negative deflection below the isoelectric line
- Hence, V1 which 'looks at' the base of the heart towards the RV has predominantly a negative QRS, as the major vector of myocardial depolarization is away from that lead, towards the apex of the LV
- V6, which 'looks at' the LV apex, is correspondingly predominantly a strongly positive complex.

Mean frontal axis

- The chest leads (V1–V6) are not used
- Look at the most isoelectric complex—the axis will lie at 90° to this
- Look at the leads which are at 90° to the isoelectric lead—the most positive one will be close to the true axis, with the most negative lead being 180° to the axis
- Much has been made of the ECG axis, although in reality there are only a few important patterns to recognize:
 - RBBB and left or right axis deviation in bifascicular block
 - Left anterior hemiblock
 - 'Upward' or 'northward' axis of AV canal defects and often in fascicular VT
 - Right axis deviation in RV strain/overload, e.g. chest disease, including acute PE.

Table 21.1 Areas related to each ECG lead

ECG lead	Area that lead 'looks at'
Leads I and aVL	Lateral aspect of the whole myocardium
Leads II, III, and aVF	The inferior (caudal) aspect of the whole myocardium
Lead aVR	Right lateral heart
V1 and V2	Atria (with the RA moving towards these electrodes and the LA moving away) and the base of the ventricles
V3 and V4	The septum and mid LV
V5 and V6	LV lateral wall and apex

**Fig. 21.1** ECG lead vectors. The augmented leads (aVR, aVL, and aVF) are spaced at 120°. The standard leads (I, II and III) are spaced at 60°**Table 21.2** ECG normal values

	Milliseconds	Small squares*
PR interval	0.12–0.2	3–5
QRS duration	≤0.12	Not >3
Axis	–30° to +120°	
QT interval	0.35–0.43†	9–11
P-wave duration	<0.11	<3

* assuming paper speed of 25 mm/sec; † must be corrected for heart rate

The current of injury

- A myocyte damaged by any cause (direct trauma, ischaemia) cannot regulate normal ionic transport. The earliest process to be affected is repolarization and thus the earliest changes seen on the ECG are usually in the ST segment of the ECG—i.e. the period at the very end of depolarization to repolarization
- An injured myocyte produces an action potential which has a 'lower' (i.e. *more negative*) baseline. Taken as a group of cells, this gives the appearance of ST segment *elevation* when viewed from an electrode position directly adjacent to the damaged area (Fig. 21.3)
- In cardiac ischaemia (📖 p.62), the endomyocardium becomes ischaemic first, as it is relatively less well perfused. The ST elevation is directed in an inward vector manifesting as ST segment depression when observed on surface electrodes (Fig. 21.4)
- In acute MI (📖 p.44) the full thickness of myocardium is in jeopardy and so ST elevation is seen in those leads which 'look at' the affected territory (e.g. leads V1–V6 in anteroseptal infarcts, II, III, and aVF in inferior infarcts) (📖 ECG: p.399, 400, 401)
- In LV hypertrophy, the 'strain pattern' is believed to be a result of chronic subendocardial ischaemia due to the high metabolic demands of the ↑muscle-mass and the diminished perfusion from high transmural pressures. Thus the cells may demonstrate chronic ST elevation which, when viewed on the surface ECG, manifest as non-dynamic ST depression. As it predominantly occurs in the LV, it is typically seen in leads V4–V6 (📖 p.426)
- In temporary (and permanent) pacing, endomyocardial electrode contact is confirmed by a local signal of ST elevation obtained from the pacing-electrode tip. Conversely ST depression suggests penetration of the electrode through the ventricular wall into the pericardium.

Box 21.1 'High take-off'

- This is a term which refers to fixed physiological ST elevation
- It is more often seen in the anterior chest leads V1, V2, and V3 where the ST segment often lies 1 mm or so above the isoelectric line
- It is less commonly seen in inferior leads and occasionally it is affected by posture—i.e. moving from the lying to the standing position
- In either case, clinical assessment is critical before making any conclusions about coronary ischaemia or MI
- In the presence of LBBB, V1 and V2 almost always show some degree of ST elevation
- In RBBB, V1 and V2 again often show ST elevation—but be aware that you are not missing Brugada syndrome (📖 p.177, ECG p.425).

Some patterns of ST segment abnormalities

See Figs. 21.2–21.4.

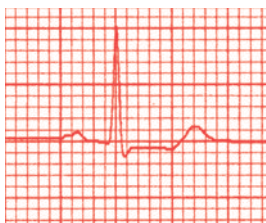


Fig. 21.2 Typical, planar ST depression.

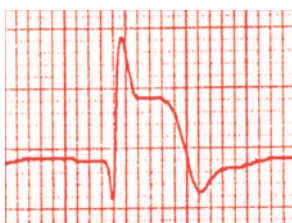


Fig. 21.3 ST elevation due to MI.

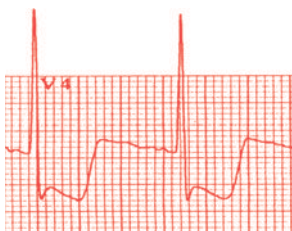


Fig. 21.4 ST depression. This exaggerated response is often found in LV hypertrophy and ischaemia—particularly during exercise tests. ‘Strain’ pattern can sometimes be this severe, especially in severe AS and HCM.

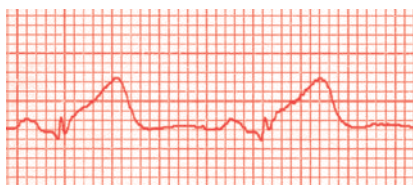


Fig. 21.5 ‘Hyper-acute’ ST changes. Often this is the first sign of ST shift in acute MI. It may also be seen in hyperadrenergic states, including subarachnoid haemorrhage and post-arrest (especially after adrenaline has been given) where it does not necessarily represent infarction.

True posterior myocardial infarction (Fig. 21.6)

- Differentiating between true posterior MI and ischaemic ST depression may be difficult
- The key is to look at the 'shape' of the ST elevation from a posterior point of view using either true posterior leads or holding the ECG up to the light and looking at V1–V3 reversed (i.e. from behind, upside down)
- Fig. 21.6 shows (A) V1–V3 in standard fashion, with (B) the leads reversed, such that V3 is uppermost
- The pattern in reversed V1 (lowermost complex, B) looks like typical ST elevation.

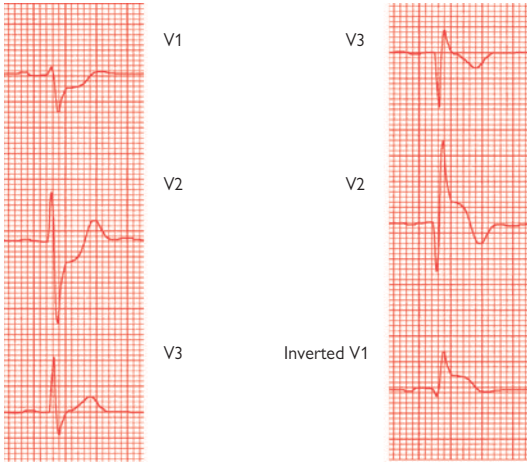


Fig. 21.6

Helpful tips

Left ventricular hypertrophy

This is difficult to diagnose on the ECG as most criteria are only up to 50% sensitive, making them clinically unhelpful. The QRS voltages may also be influenced by body size and shape, as well as lead positioning.

- LV hypertrophy and so-called LV hypertrophy strain pattern is the presence of:
 - LV hypertrophy with T-wave inversion, and
 - ST depression (usually in V5–V6, I, and aVL)
- Quick measurements that can be consistent with LV hypertrophy are:
 1. (S in V1 or V2) + (R in V5 or V6) >35 mm (over age 35)
 2. R in AVL > 12 mm.

The ST depression represents chronic ischaemia within the endomyocardium producing a current of injury which is interpreted by the external leads as being ST depression. Do not confuse this with the 'reverse tick' type of ST depression seen in patients taking digoxin.

Dominant R wave in V1

A useful tip for ECG interpretation is that a dominant R wave in lead V1 is usually associated with one of the following:

- RBBB (📖 p.394)
- Left-sided accessory pathway
- Posterior MI (📖 p.392)
- RV hypertrophy
- Dextrocardia
- Infancy

Localization of accessory pathways

The acute management of patients with pre-excitation does not require accurate localization of the pathway. It is only important for electrophysiologists, as it aids selection of the correct equipment and approach to ablation. However, there are some simple rules-of-thumb:

- Dominant R wave in V1 suggests left-sided accessory pathways—i.e. looks more like RBBB because left heart is being stimulated prematurely via the accessory pathway
- LBBB-like pattern suggests right-sided accessory pathway
- The negative delta wave 'points' to the accessory pathway's position e.g. left free wall accessory pathways usually have negative delta wave in aVL, posteroseptal pathways (actually, inferiorly situated in true anatomy) have negative delta waves in II, III, and aVF
- As septal pathways move from posteroseptal, to mid-septal and anteroseptal, the delta wave tends to become more positive in the inferior leads in sequence—i.e. II, then aVF and then III.

Thus, in basic terms, localization may be simplified as follows:

- Dominant R wave in V1? Yes—left sided. No—right sided
- Negative delta wave in inferior leads? Yes—posteroseptal likely. No—free-wall likely.

Electrolytes and the ECG

- As a rule of thumb hyPO-PrOlongs the QT interval (📖 ECG, p.424)
- With hypokalaemia, the T wave flattens, the ST segments depress, and U waves can develop (Fig. 21.7):

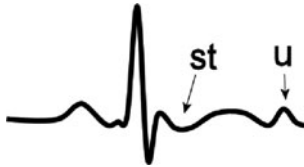

Fig. 21.7 Hypokalaemia.

- HYPERkalaemia is an important and classic ECG which typically shows a broad QRS, flattened P waves with high peaked T waves (Fig. 21.8):

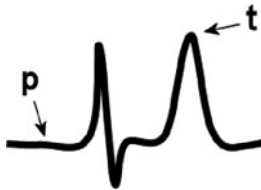

Fig. 21.8 Hyperkalaemia.

- As the potassium concentration increases the ECG may simply show a sign wave appearance—this is a medical emergency

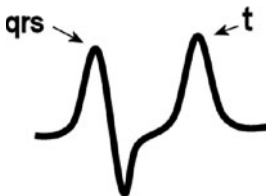


Fig. 21.9

- The ECG changes of hypomagnesaemia resemble that of hypokalaemia
- The ECG changes of hypermagnesaemia resemble that of hyperkalaemia
- Hypercalcaemia tends to shorten the QT interval whereas hypocalcaemia lengthens it.

Further reading

Fitzpatrick AP et al. New algorithm for the localization of accessory atrioventricular connections using a baseline electrocardiogram. *J Am Coll Cardiol* 1994; **23**: 107–16.

Bundle branch block


The bundle of His exits the AV node within the interventricular septum and bifurcates into the left and right bundle branches. The left bundle subdivides further into the left posterior and anterior fascicles. The bundles can develop conduction block from a variety of sources, both transient and permanent. Characteristic changes may then be observed on the ECG

Left bundle branch block

(Also see  ECG, p.407)

- Activation proceeds through the bundle of His and into the right bundle as normal, activating the RV early. This is rapid, and hence there is a sharp deflection initially
- Septal and left ventricular activation is delayed, hence the QRS configuration is almost as it would be in normal activation but 'wider'
- As septal depolarization is reversed (now occurring from right-to-left) there is an initial Q wave in V1 and an R-S-R' pattern in V6—i.e. V1 is W shaped and V6 is M shaped
- In true LBBB there can be no initial Q wave in 'left-looking' leads, V5, V6, and I, no matter how small the deflection

Clinical significance of LBBB:

- Almost always associated with organic heart disease, e.g. ischaemia, cardiomyopathy, conduction tissue disease, hypertensive heart disease, infiltration
- ST elevation is very difficult to interpret and thus cannot be relied upon to diagnose acute MI.
- ► New-onset LBBB with ischaemic sounding chest pain is supportive of acute MI and thus is considered an indication for thrombolysis ( p.48.)

Right bundle branch block

(Also see  ECG, p.408)

- RV activation occurs via the left bundle branch and thus is delayed
- The interventricular septum is depolarized in the normal fashion (left-to-right)
- Because the RV is activated just after the LV it typically produces an R-S-R' pattern in V1 (M shape)
- In V6 it may produce a deep S wave, giving a modified W type pattern, although often this is not apparent. The changes in V1 are much more constant

Clinical significance of RBBB

- May be normal, especially in young and the fit
- May be a sign of right heart strain, e.g. acute PE, RV overload due to shunts
- Often seen in ASDs, with right axis deviation in atrial septal type ('secundum') defects and left/upright axis in AV canal defects ('primum').

'William and Marrow'

- William and Marrow are often used aide memoirs to recognize and differentiate LBBB and RBBB
- The first letter of each word refers to the appearance of the QRS complex in V1 and the last letter in V6
- The double letters in the middle give the type of BBB. In practice, 'WiLLiaM' for LBBB tends to work quite well as a rule of thumb, but as mentioned earlier, 'MaRRoW' tends to fall down because V6 often does not look like an M shape.

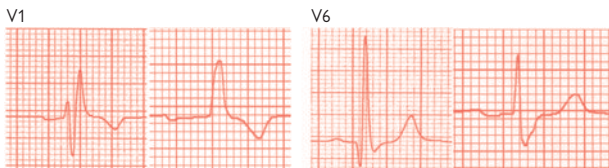


Fig. 21.10 A) V1 in two cases of RBBB, and B) V6. The 'MaRRoW' principle can only be interpreted with a degree of 'artistic licence'

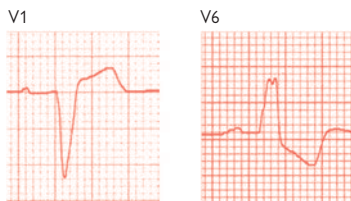


Fig. 21.11 V1 (A) and V6 (B) in LBBB. Again, applying the 'WiLLiaM' principle requires a little imagination

Alternating LBBB/RBBB

- A sign of bifascicular block
- In the presence of unexplained syncope, transient higher degrees of AV block should be considered.

Bifascicular and trifascicular block

- Conduction delay, usually due to widespread fibrotic disease is present within the AV node, His bundle, and bundle branches
- Left anterior hemiblock usually results in left axis deviation
- Left posterior hemiblock usually results in right axis deviation
- Trifascicular block is a misnomer, as it really represents conduction delay. Logically, if all 3 fascicles were actually blocked there would be complete heart block
- Bifascicular block is most commonly seen with RBBB and left anterior hemiblock. Hence there is RBBB and left axis deviation
- In trifascicular block, the classic ECG shows 1° heart block, RBBB and left axis deviation (📖 p.409)
- In an asymptomatic patient with trifascicular block, permanent pacing is not indicated. In the presence of unexplained syncope however, a bradycardic cause is likely
- Risk of complete heart block (may be transient) is 2–6% per annum, with asymptomatic patients forming the lower percentage, and those with unexplained syncope the higher

Bundle branch block and cardiac catheterization

- Direct trauma to a bundle may produce BBB (usually transient)—so-called ‘mechanical bundle block’, this may last for several hours or even days
- In pre-existing BBB, catheter-based procedures on the contralateral side may produce complete heart block, with acute compromise. This occurs most typically during right heart procedures with pre-existing LBBB (e.g. Swan–Ganz lines, pacing, etc.)

Paced complexes and VT morphology

- Pacing from the RV apex causes the septum and LV to be activated right-to-left, rather like LBBB. Thus paced complexes have the LBBB ‘WiLLiaM’ type morphology. In LV pacing (as part of cardiac resynchronization therapy) the pure LV paced complex has RBBB morphology (Fig. 21.12)
- For similar reasons, VT with LBBB type morphology may be exiting within the right heart, and RBBB morphologies may be exiting within the left heart.

Box 21.2 Bundle branch block and SVT rate

When a BBB develops during SVT it is often labelled a 'rate-related' BBB. However, careful attention should be paid to the tachycardia rate. If the rate or cycle-length actually slows, then an accessory pathway ipsilateral to the block is implicated—i.e. LBBB with slowing implicates a left free-wall accessory pathway, and RBBB suggests a right-sided accessory pathway. The mechanism is due to the extra time the head of the re-entrant wave takes to cross the septum after it leaves the AV node and spreads through the His–Purkinje system.

Example: In AVRT with a left sided free-wall accessory pathway, the circuit travels down the AV node, through both LV and RV, before climbing the accessory pathway back into the LA, and so on. If LBBB develops, the wavefront must travel down the right bundle, across the septum and into the LV using cell-to-cell spread. This adds about 40–60 msec to its journey and results in an increase in tachycardia cycle length by the same amount.

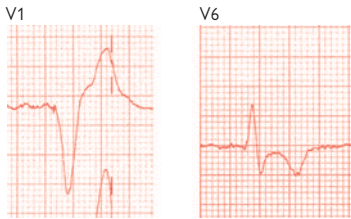


Fig. 21.12 Paced rhythm from RV apex, with V1 (A) and V6 (B) shown. Depolarization initiating from the RV apex 'mimics' to a certain degree, LBBB, as reflected in the tracings. RBBB-paced patterns are due to inadvertent LV capture via an ASD/PFO, VSD, or coronary sinus branch. With a biventricular pacemaker it may represent a LV lead or programming problems.

ECG library

The following collection of ECGs is presented to act as a reminder of the 12-lead ECG patterns of common (and a few uncommon) cardiac conditions.

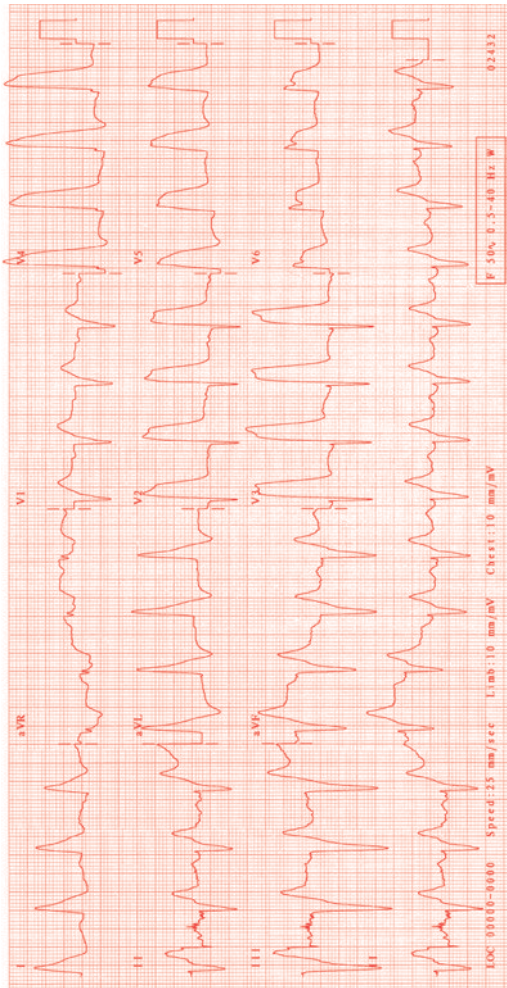
Anterior myocardial infarction

Fig. 21.13 There is ST elevation of > 30mm in anterior leads (V2–V4). For management see [□](#) p.44.

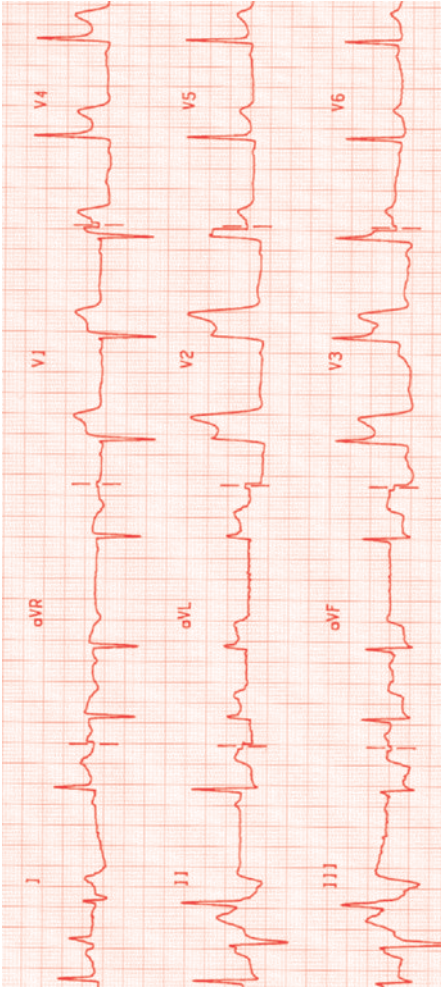

Anterolateral myocardial

Fig. 21.14 There is marked ST segment elevation in leads V1–V4 and aVL. Reciprocal ST segment depression is present in leads II, III, and aVF. For management see  p.44.

Inferior myocardial infarction

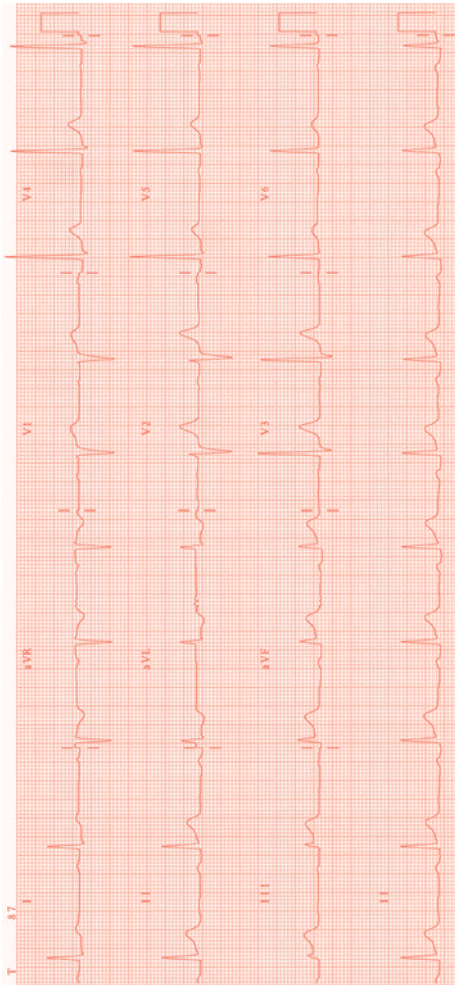


Fig. 21.15 There is ST elevation of $>1\text{mm}$ in the inferior leads (II, III, and aVF). There is also 1° AV block (PR interval $>200\text{msec}$). For management see [□](#) p.44.

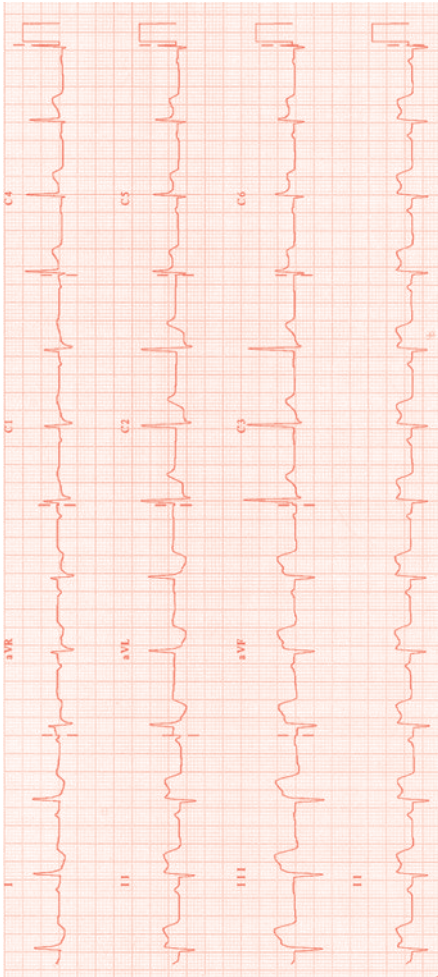

Inferolateral-posterior myocardial infarction

Fig. 21.16 There is ST elevation of $>1\text{mm}$ in the inferior leads (II, III, and aVF) and lateral leads (V5 and V6) with ST depression in V1 and V2. The R wave in V1 is dominant. For management see  p.44.

Myocardial ischaemia

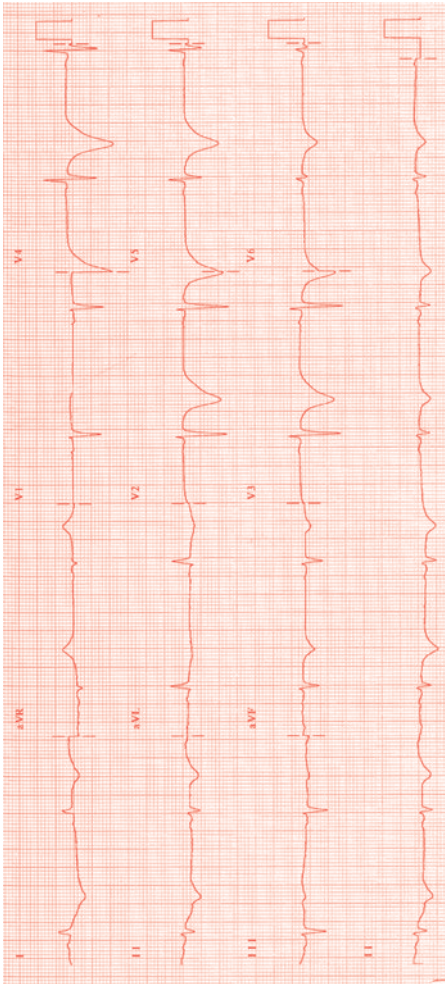


Fig. 21.17 Deep T-wave inversion across the anterior leads. A stenosis of the proximal left anterior descending coronary artery lesion is commonly the culprit. For management see [p.62](#).

Pericarditis

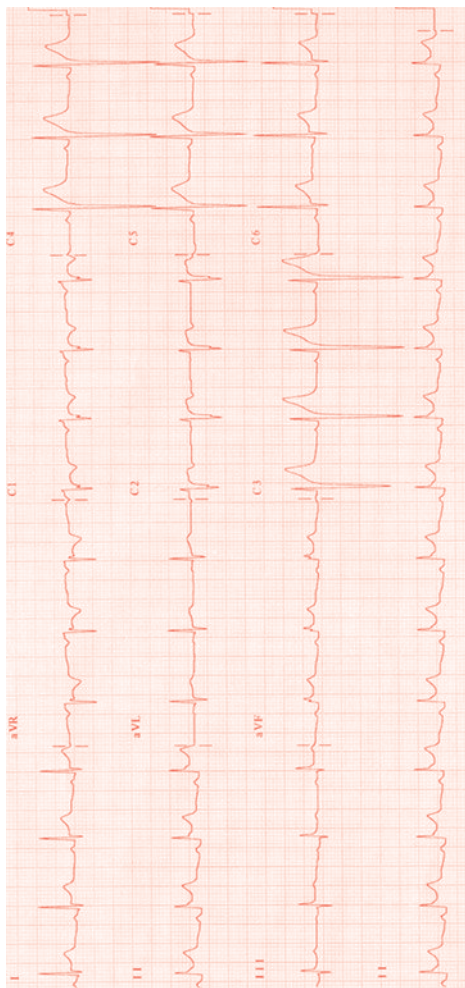


Fig. 21.18 Saddle-shaped ST elevation across several, non-contiguous leads. There is PR segment depression (particularly in leads II and aVF). For management see [p.206](#).

Pulmonary embolism

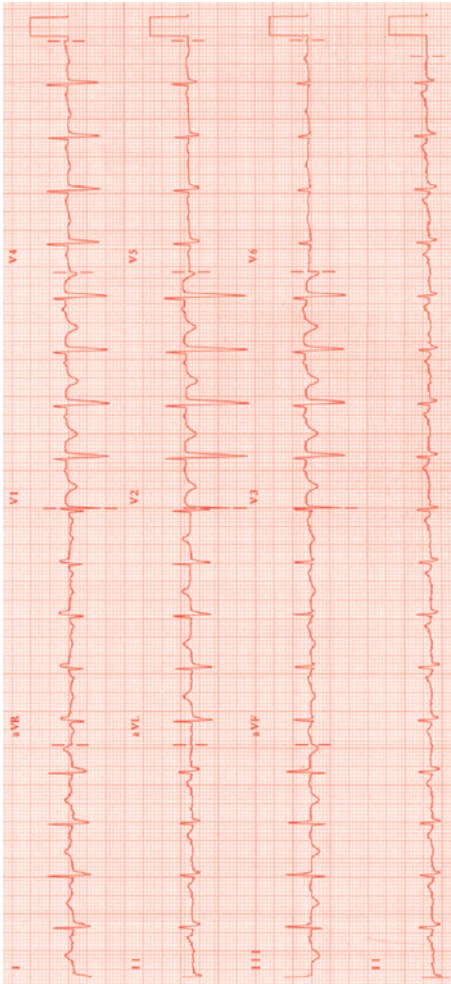


Fig. 21.19 Sinus tachycardia with widespread T-wave inversion. There is a large S wave in I with a Q wave and T inversion in lead III. NB this is rare—the most common ECG finding in PE is sinus tachycardia.

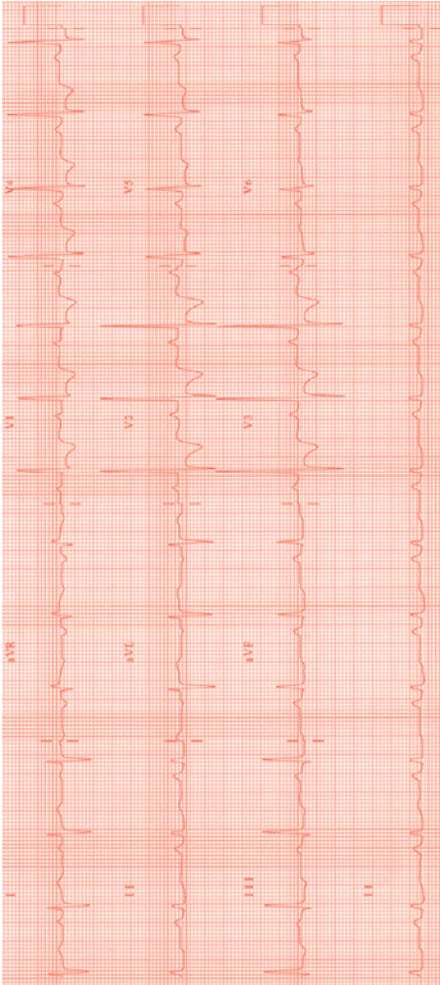
Pulmonary hypertension

Fig. 21.20 RV hypertrophy is demonstrated by right axis deviation, large R waves with T-wave inversion in leads V1–V3 and a prominent p wave (p pulmonale).

Left bundle branch block

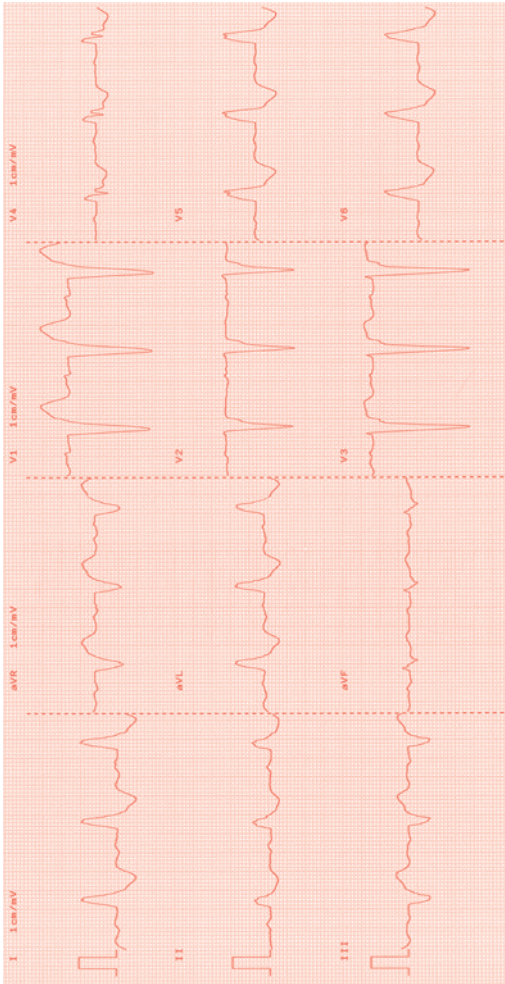



Fig. 21.21 LBBB. Broad QRS complex with a Q wave in V1 ('W') and RSR pattern in V6 ('M'). See  p.394.

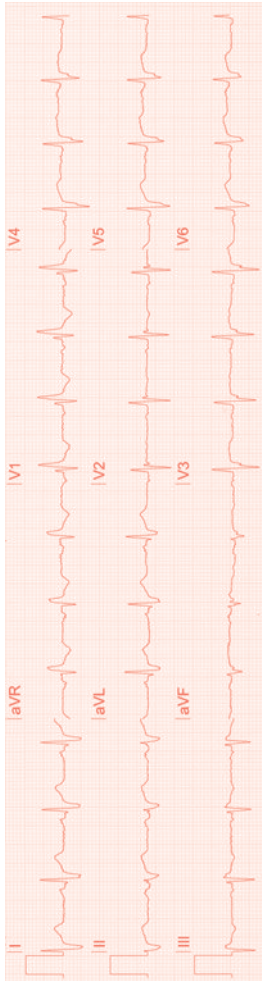

Right bundle branch block

Fig. 21.22 RBBB. Broad QRS complex with an RSR pattern in V1 (M shape) and an S wave in V6 (W shape). There is also 1° AV block. See  p.394.

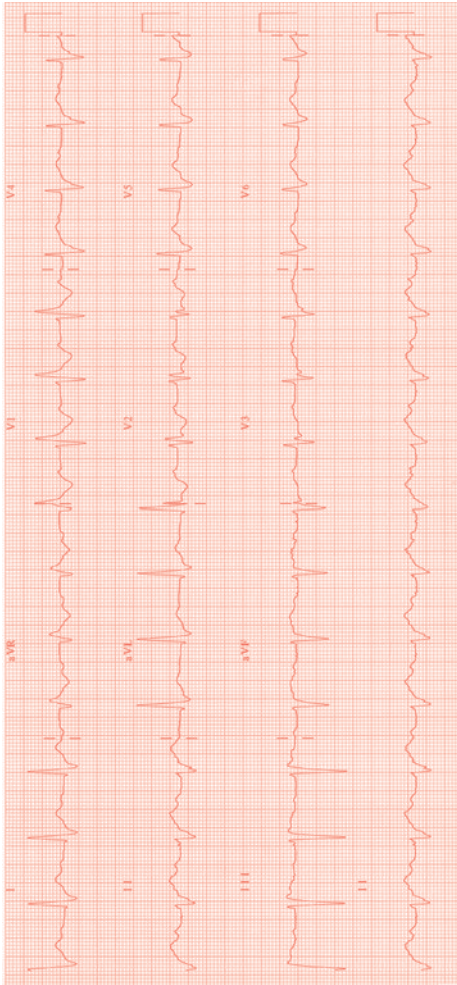
Trifascicular block

Fig. 21.23 There is RBBB, 1° degree AV block, and left anterior hemiblock (left axis deviation). See  p.396.

Junctional rhythm

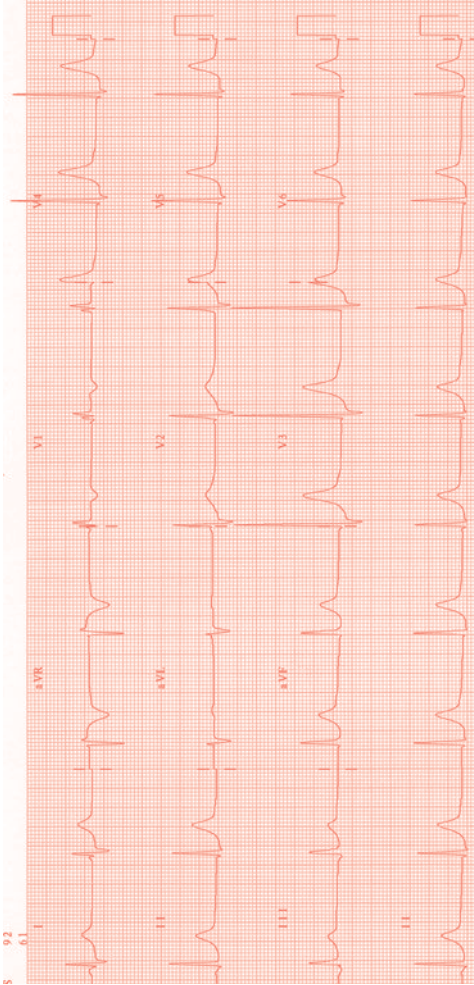


Fig. 21.24 P waves are seen before the first complex but then are buried within the QRS complex. See [p.144](#).

First degree heart block

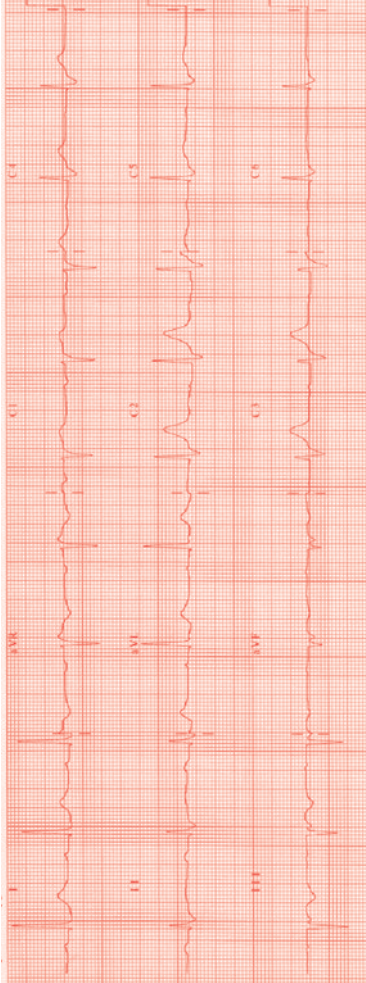



Fig. 21.25 P waves are seen before each QRS complex. The PR interval is prolonged (289ms). See  p.146.

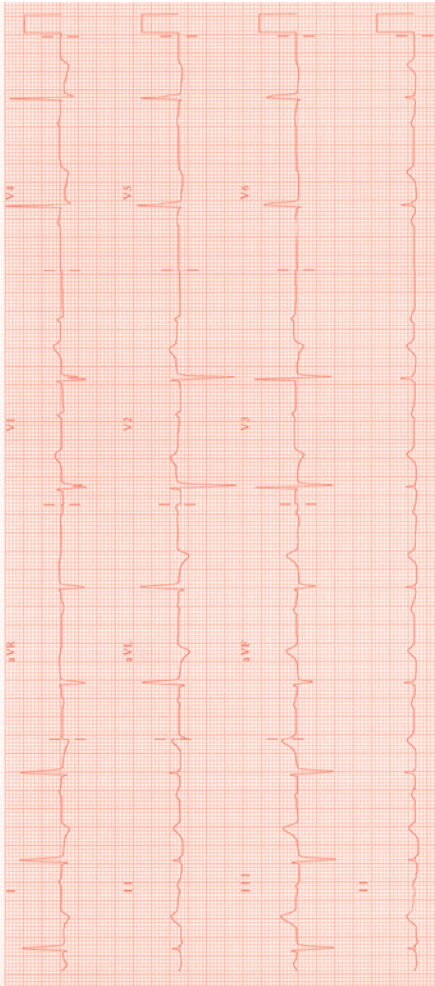
Second degree heart block (Mobitz I)

Fig. 21.26 There is progressive lengthening of the PR interval until a P wave is non-conducted and a QRS is dropped (Wenckebach). The PR interval after the dropped beat is the shortest. See [□](#) p.147.

Complete heart block

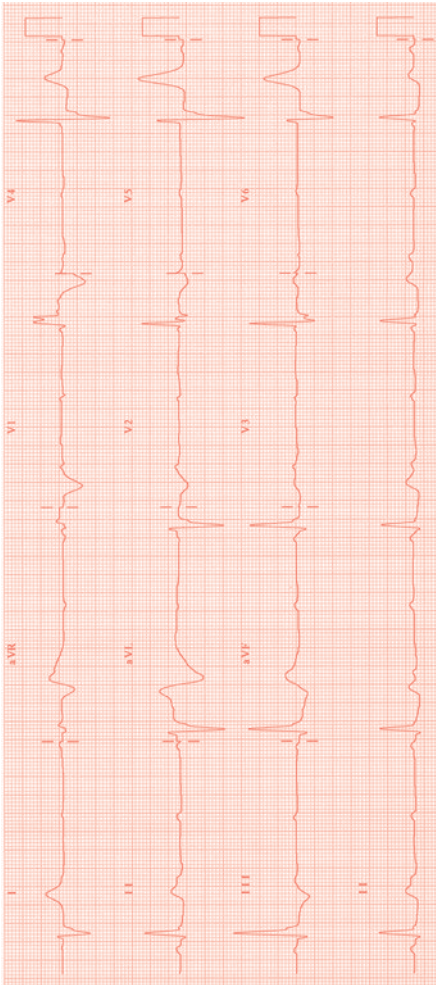


Fig. 21.27 There are regular non-conducted P waves with a broad complex QRS escape rhythm. There is no association between the atrial and the ventricular rates. For management see [p.148](#).

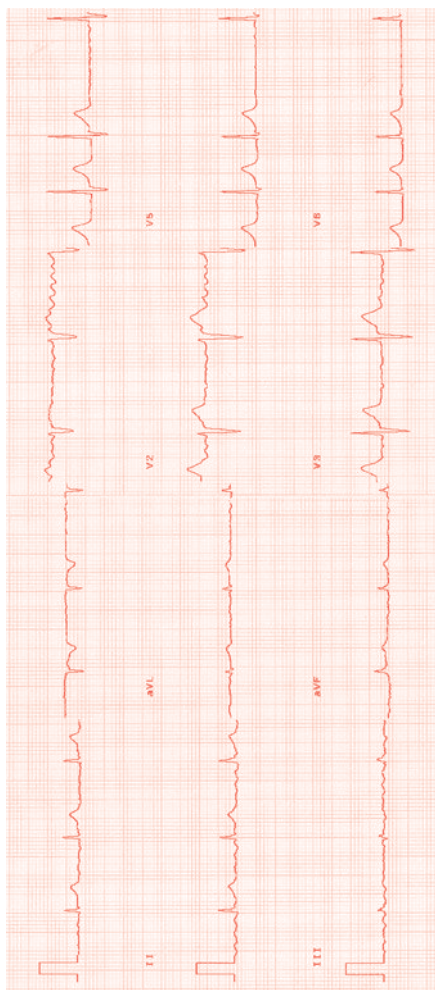

Atrial fibrillation

Fig. 21.28 Irregularly irregular ventricular rhythm with no discernible P waves. For management see  p.160.

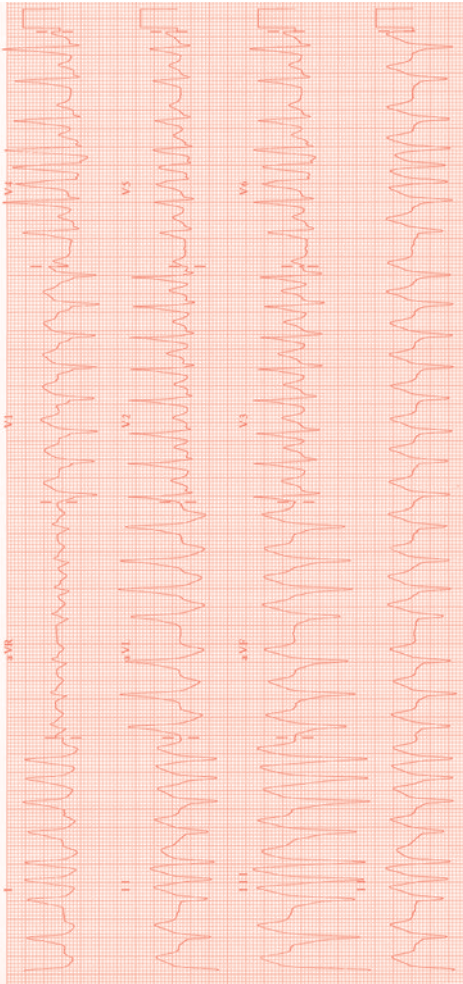

Pre-excited atrial fibrillation

Fig. 21.29 An irregular broad complex tachycardia with very rapid ventricular activation and conduction. For management see  p.163.

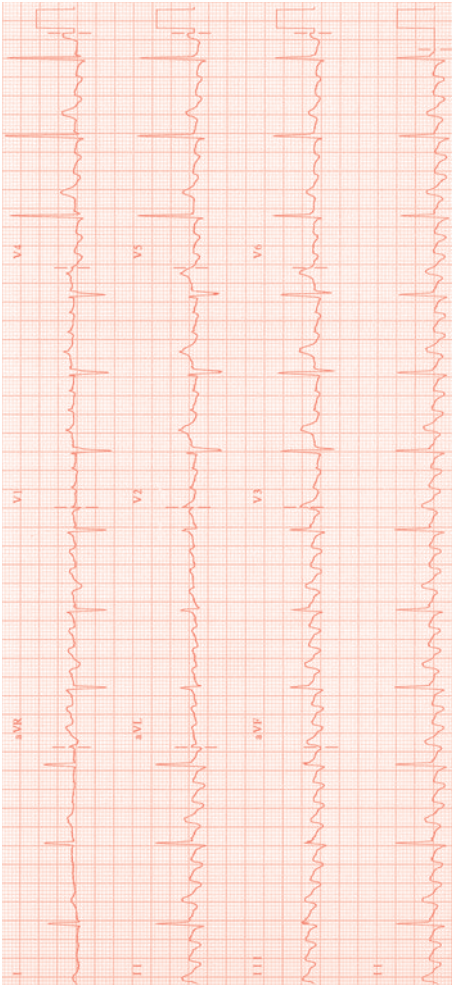
Atrial flutter

Fig. 21.30 The baseline is irregular with a 'saw-tooth' pattern. The flutter waves are conducted with a 4:1 pattern to the ventricle. For management see [p.166](#).

Atrial tachycardia

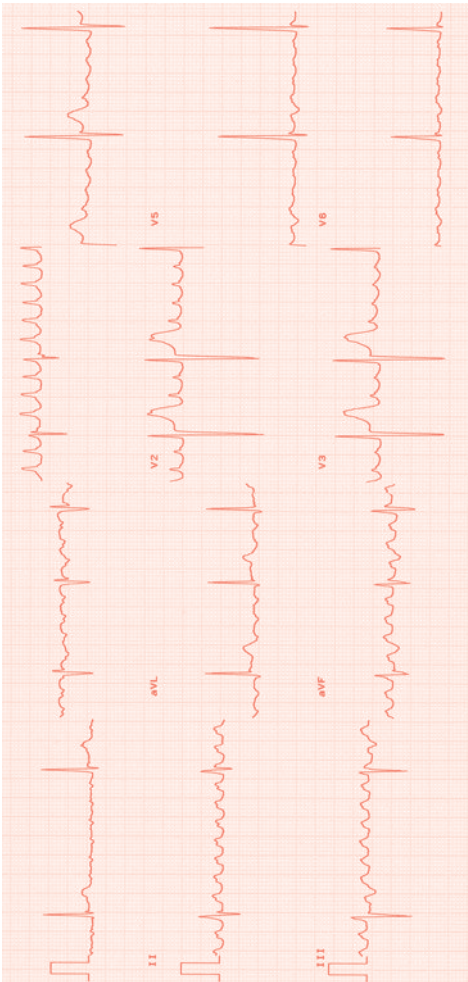


Fig. 21.31 The baseline is irregular with very rapid atrial activation (300 bpm) and a positive P wave in V1 suggesting a focal atrial tachycardia. The baseline returns to normal between each atrial beat. For management see [p.168](#).

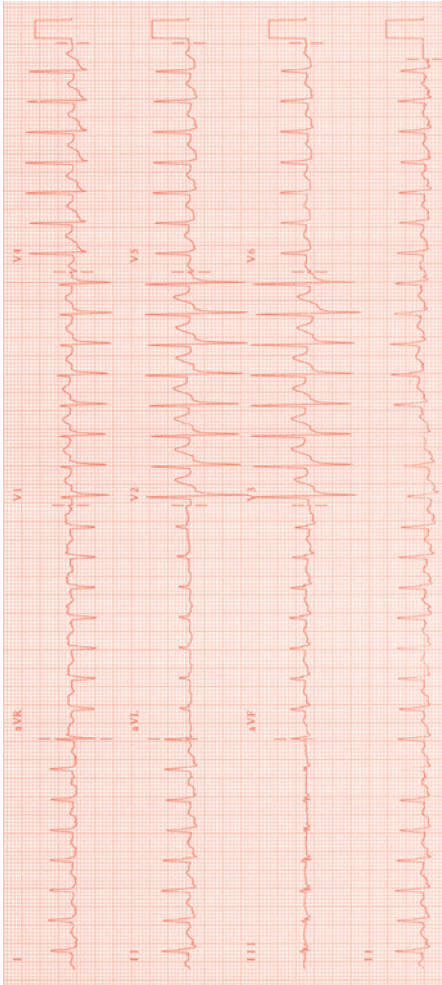

Supraventricular tachycardia (AVNRT)

Fig. 21.32 A narrow complex tachycardia (SVT). Differentiation from AVRT on the ECG is difficult but can be suggested: the terminal deflection on the R wave in V1 is likely to represent the R-prime (R') sign which suggests a terminal portion of P wave is visible there (the rest is hidden 'behind' the QRS). With a ventricular-to-atrial conduction time so short, AVNRT is the most likely diagnosis. For management see  p.170.

Supraventricular tachycardia (AVRT)

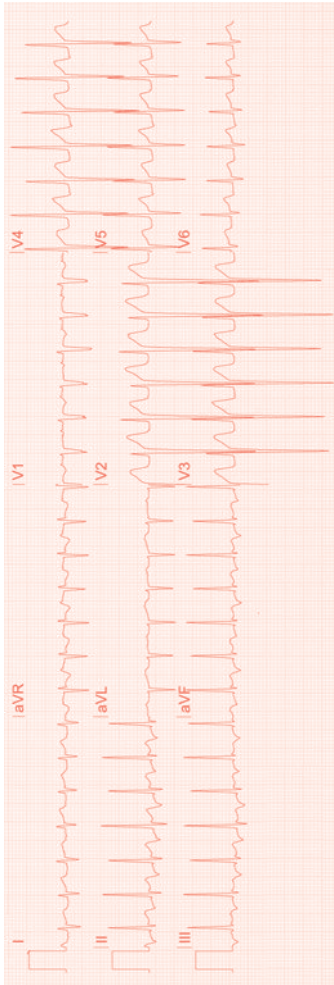


Fig. 21.33 A narrow complex tachycardia. There is retrograde P wave activation (clearly seen in V1 before the QRS complex). For management see [p.172](#).

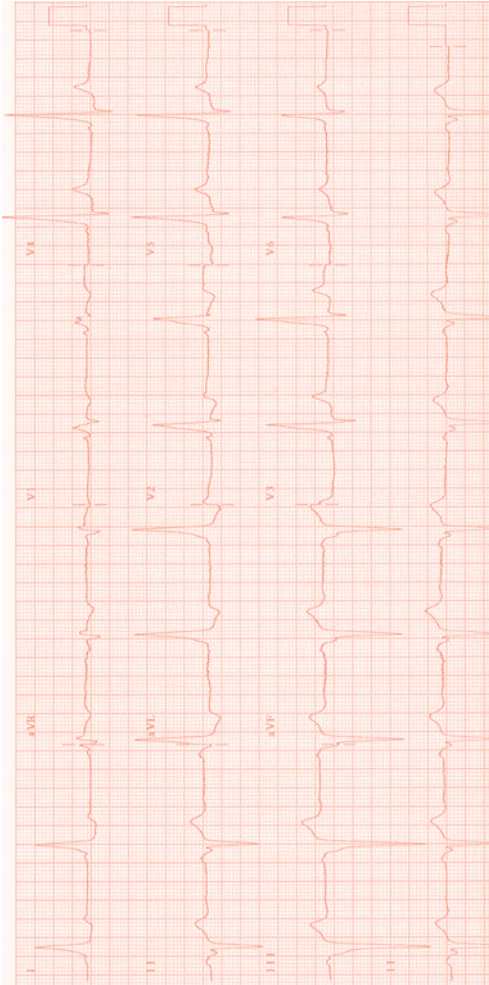

Pre-excitation

Fig. 21.34 Short PR interval due to the presence of a delta wave. There is a RBBB-type pattern present, suggesting the accessory pathway is left sided. The negative delta waves inferiorly suggest that the accessory pathway is posteroseptal. For management see  p.174.

Ventricular tachycardia

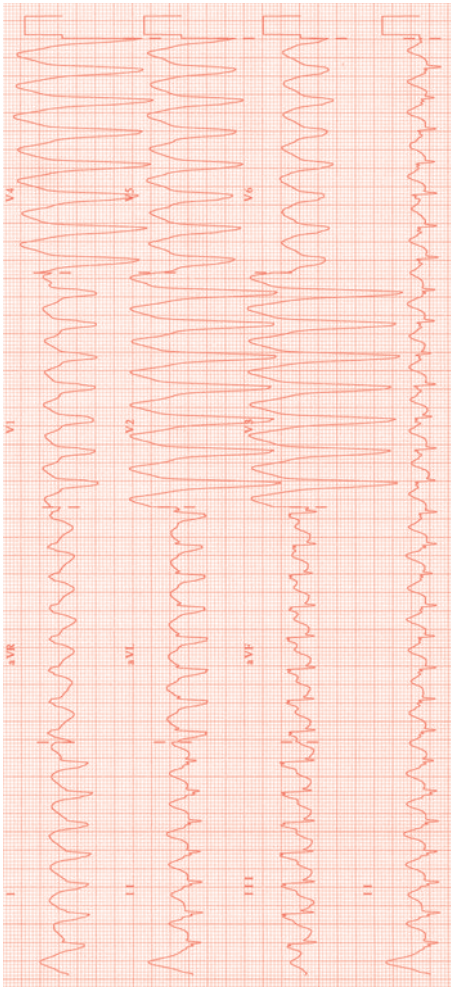



Fig. 21.35 A broad complex tachycardia with a ventricular rate of 180 bpm. AV dissociation is seen with buried P waves in V6. There is concordance across the chest leads. For management see  p.180.


Ventricular fibrillation

Fig. 21.36 Continuous ECG monitoring of a patient who develops increasing ventricular ectopic beats followed by the onset of a chaotic broad complex ventricular rhythm.

Accelerated idioventricular rhythm

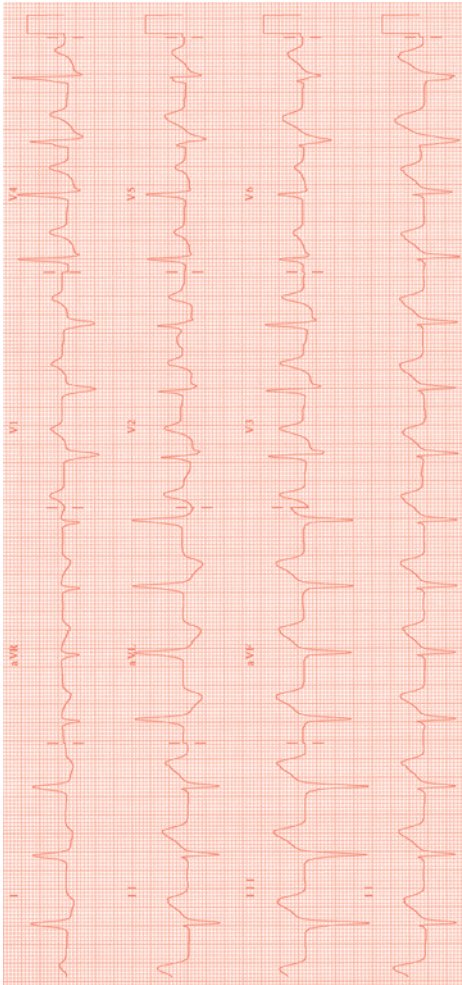


Fig. 21.37 An automatic ventricular rhythm with a rate <100 bpm. Usually seen in the context of myocardial ischaemia or MI.

Long QT

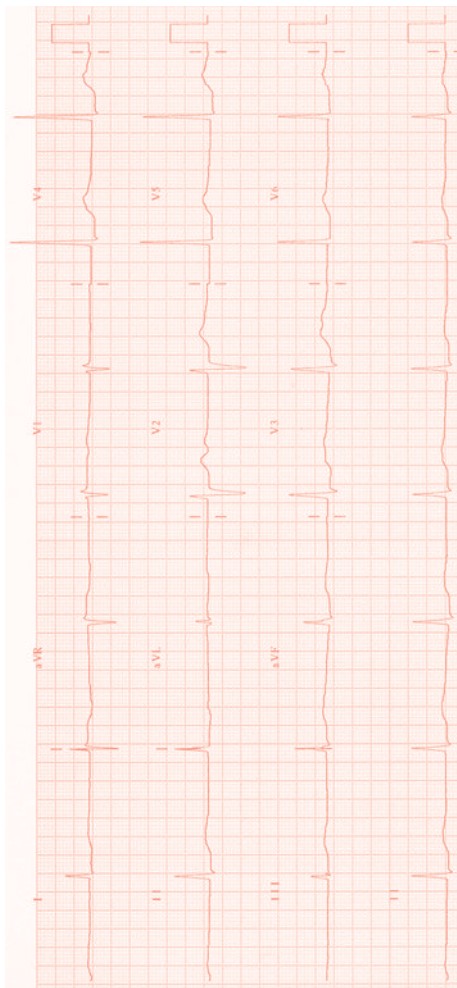


Fig. 21.38 The QT interval (start of the Q wave to the end of the T wave) is prolonged (>600 ms). See [Inherited long QT syndrome p.177](#); [Drug-induced long QT p.344](#).

Brugada syndrome

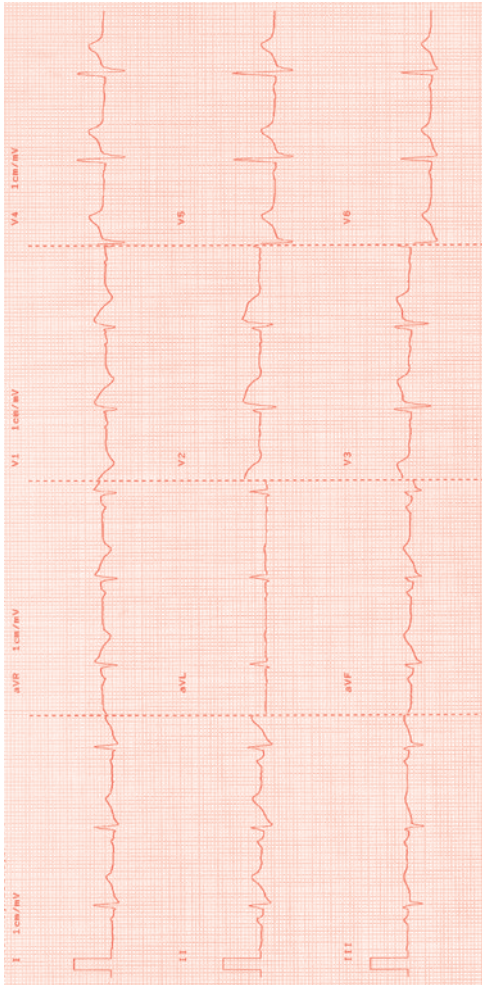


Fig. 21.39 Right precordial ST elevation with T-wave inversion in V1–V3. Association with SCD. see p.177.

Hypertrophic cardiomyopathy

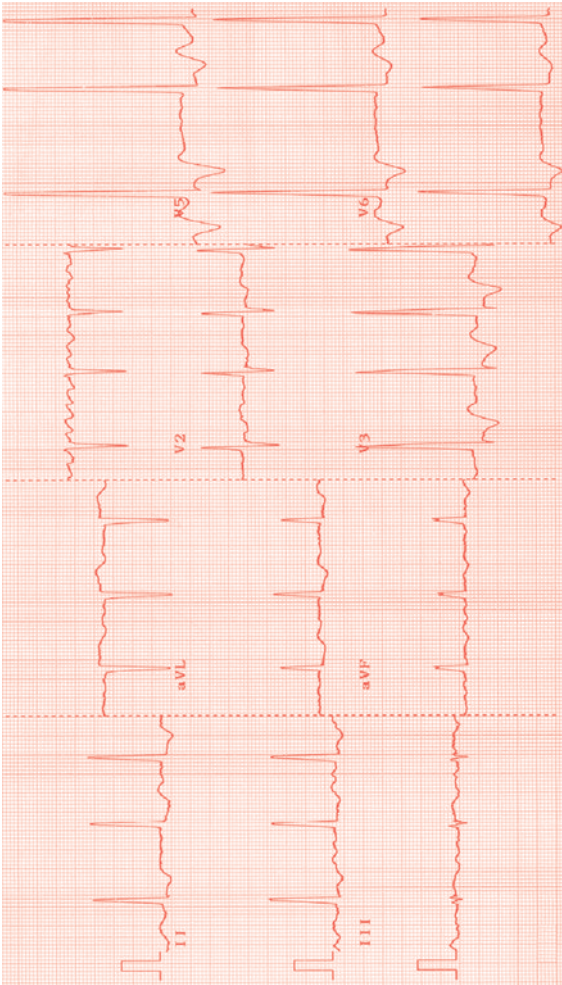



Fig. 21.40 The underlying rhythm is AF. Tall R waves are seen along with repolarization changes in V3–V6, in keeping with LV hypertrophy. See  p.86.

Arrhythmogenic right ventricular cardiomyopathy

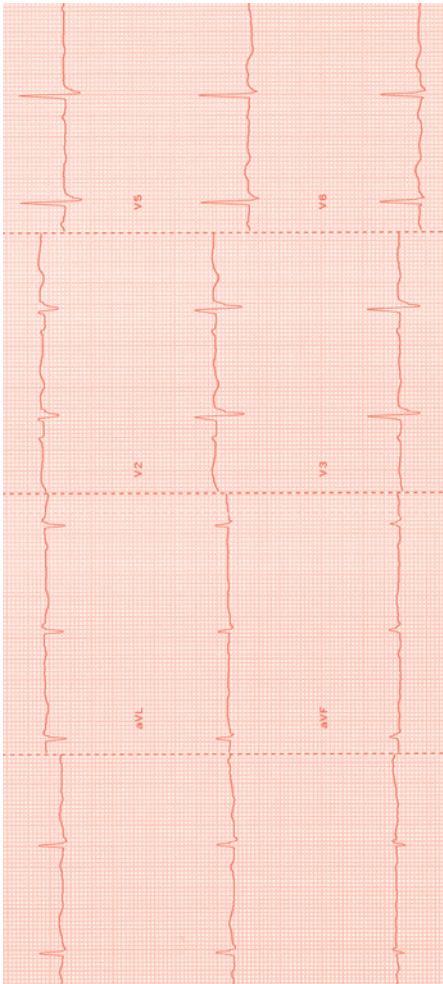


Fig. 21.41 T-wave inversion is seen in the right precordial leads (V1–V3). There is an epsilon wave (a small spike representing a late RV potential) seen in V1 and V2 in the upstroke of the ST segment. Associated with VT. See [p.86](#).

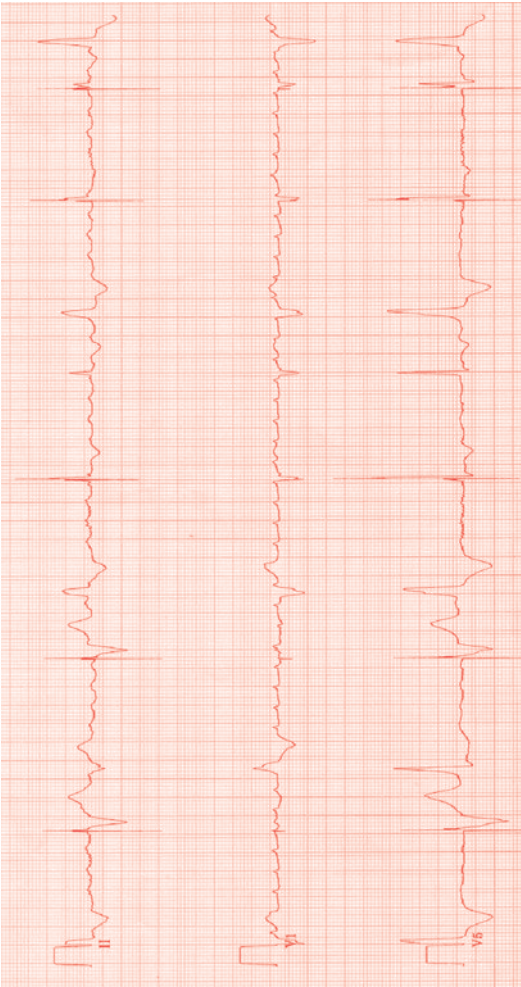
Single chamber pacemaker

Fig. 21.42 The underlying rhythm is atrial flutter with intermittent ventricular conduction and bigeminy. Pacing spikes precede widened (captured) ventricular complexes and narrow (fusion) ventricular beats.

Dual chamber pacemaker

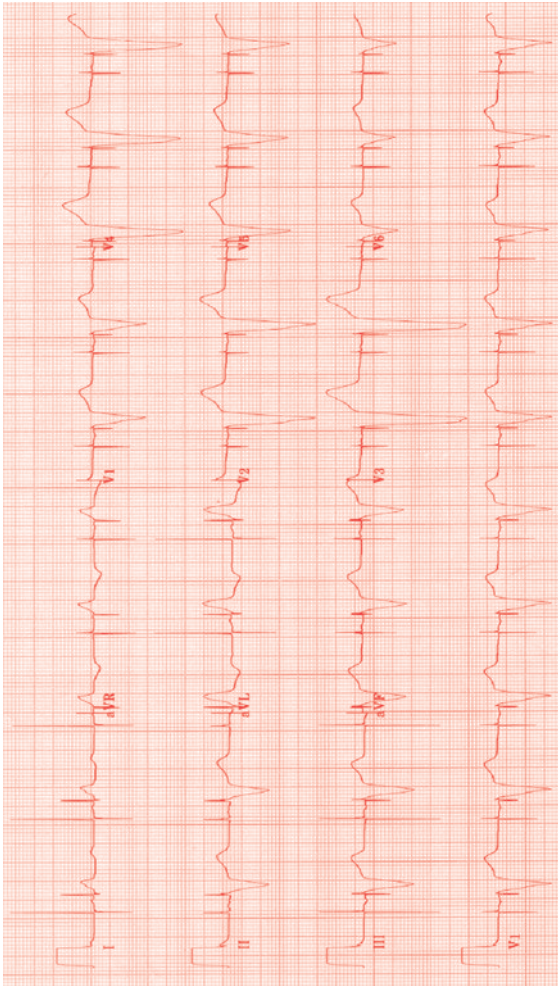


Fig. 21.43 There are pacing spikes preceding each atrial and ventricular complex.

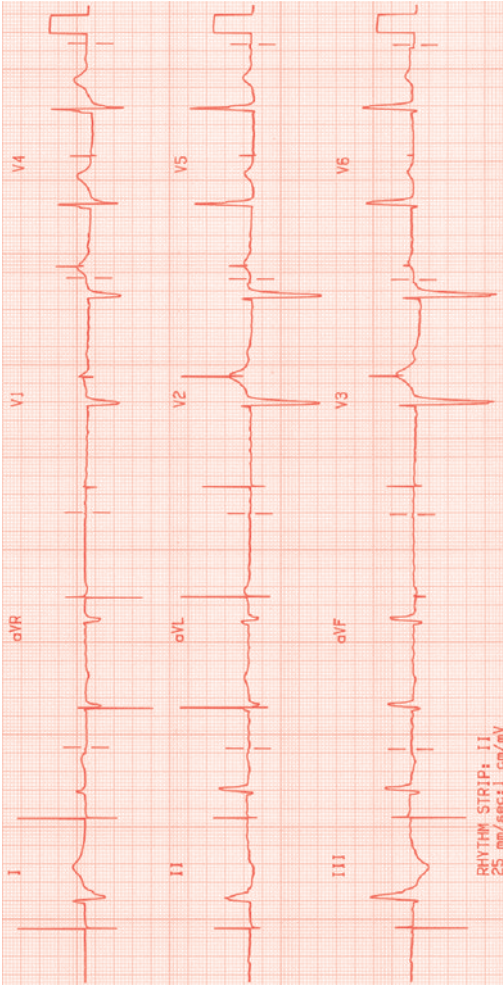
Pacemaker lead failure

Fig. 21.44 Pacemaker spikes can be seen with no ventricular capture. The ventricular lead had displaced.

Index

A

- accelerated idioventricular rhythm 423
- accessory pathway
 - atrioventricular nodal re-entrant tachycardia 168–9
- atrioventricular re-entrant tachycardia 170–1
 - ECG 392
 - see pre-excitation
- Wolff-Parkinson-White syndrome 172–3
- ACE inhibitors in heart failure 74, 284**
- acute coronary syndromes 39**
 - classification 41
 - pathophysiology 40
 - percutaneous coronary intervention 66
 - see also myocardial infarction
- acute heart failure
 - see heart failure
- acute thoracic syndromes 200–1**
 - intramural haematoma 200
 - penetrating atherosclerotic ulcer 200
- adenosine 154
- adrenaline 9
- adult congenital heart disease 253**
 - aortic coarctation 262–3
 - arrhythmias 280
 - atrial septal defect 256, 259
 - atrioventricular septal defect 258–9
 - cyanosis 276
 - Eisenmenger syndrome 278–9
 - Fallot's tetralogy 270–1
 - Fontan operation 274
 - heart failure 284–5
 - patent ductus arteriosus 260–1
 - single ventricle 272–3
 - surgical procedures 286
 - syncope 282–3
 - transposition of great arteries 264–5
 - congenitally corrected 262–3
 - ventricular septal defect 80, 258–9
- Advanced Life Support algorithm 5**
- aldosterone antagonists 72
- aliskiren 338
- alpha-blockers 320
- alteplase 52
- amiloride, dose 316
- amiodarone 154–5, 326
 - intravenous 326
- amlodipine, dose 314
- amoxicillin 129
- amphetamine, cardiotoxicity 342
- angina 15**
 - investigations 17
 - perioperative care 298
 - physical signs 16
 - unstable 62
 - TIMI risk score 65
 - see also NSTEMI
- angiotensin converting enzyme inhibitors
 - see ACE inhibitors
- anthracyclines 346
- antiarrhythmics 154–5, 322
 - see also *individual drugs*
- antibiotics
 - infective
 - endocarditis 128–9
 - prophylaxis 100, 134–5
 - in labour 242
- anticancer drugs 346
- anticoagulation**
 - NSTEMI 64
 - pregnancy 250
 - prosthetic valves 117
 - valvular heart disease 302
- antihypertensive therapy
 - in aortic dissection 196
- antiplatelet therapy 298, 336**
- anuria 78
- aortic balloon pump 10–11
- aortic coarctation 262–3**
 - operated patients 262
 - unoperated patients 262
- aortic disease in pregnancy 246–7**
- aortic dissection 15, 189**
 - differential diagnosis 46, 192
 - endovascular stenting 197
 - hypertensive crisis 348
 - investigations 10, 192
 - management 196
 - Marfan syndrome 199, 201
 - pregnancy 246
 - presentation 192
 - prognosis 198
- aortic regurgitation 95, 104–5**
 - perioperative care 302
- aortic stenosis 95, 102**
 - acute problems 102
 - causes 102
 - clinical features 102
 - heart failure 81
 - MRI 103
 - perioperative care 291
 - in pregnancy 240
 - treatment 102
- aortic valve disease, mixed 104
- aortography 194, 196
- arrhythmias 137**
 - adult congenital heart disease 280
 - atrial fibrillation
 - see atrial fibrillation
 - atrial flutter
 - see atrial flutter
 - atrial tachycardia
 - see atrial tachycardia
- atrioventricular block 146
- atrioventricular
 - nodal re-entrant tachycardia 170–1
- atrioventricular re-entrant tachycardia 172–3
- bradycardia 138
- electrical storms 184–5
- implantable cardioverter defibrillators 186–7
- junctional
 - bradycardia 144–5
- perioperative care 304
- pregnancy 244
- sinus arrest 142–3
- sinus bradycardia 140–1
- sinus tachycardia 158–9
- tachycardia 152–3
- treatment 280
- ventricular fibrillation 176–7
- ventricular pre-excitation 174–5
- ventricular tachycardia
 - see ventricular tachycardia
- Wolff-Parkinson-White syndrome 174–5
- arterial blood gases in heart failure 76

- arterial line insertion 370
 arthritis 118
 aspirin 336
 atenolol 154
 dose 312
 atherosclerotic ulcer 200
 atorvastatin, dose 332
atrial fibrillation 160–1
 and atrioventricular
 block 150
 ECG 414
 pre-excitation 414
 and heart failure 90
 long-term
 anticoagulation 164
 mitral stenosis 106
 post-cardiac surgery 306
 pre-excited 162
 pregnancy 244
 rapid control of
 ventricular rate 162
 thromboembolic
 risk 164–5
 treatment 162–3
atrial flutter 166–7
 and atrioventricular
 block 150
 atypical 280
 ECG 416
 pregnancy 244
atrial septal defect 256–7
 operated patients 256
 unoperated patients 256
 atrial switch operation 286
 atrial tachycardia 168–9
 ECG 416
 see also atrial fibrillation;
 atrial flutter
atrioventricular block
 1st degree 146
 ECG 411
 2nd degree
 ECG 412
 Mobitz type II 147
 Mobitz type I
 (Wenckbach
 phenomenon) 147
 3rd degree
 (complete) 147
 ECG 413
 atrioventricular block
 57, 146
 after cardiac surgery 149
 and atrial fibrillation/
 flutter 150
 and myocardial
 infarction 148
 post-surgery 306
 atrioventricular nodal
 re-entrant tachycardia
 170–1
 atrioventricular re-entrant
 tachycardia 172–3
 atrioventricular septal
 defect 260–1
- B**
 ball-and-cage valve 115
 balloon valvuloplasty
 101, 106
 bendroflumethiazide 72
 dose 316
 Bentall operation 286
 benzylpenicillin 129
**beta-blockers 90, 154,
 312**
 contraindications 312
 dose 312
 heart failure 74, 284
 indications 312
 mechanism of action 312
 prophylactic 299
 side effects 312
 toxicity 313
 see also *individual drugs*
 bezafibrate 334
 bi-leaflet tilting disc
 valve 115
 bisoprolol 154
 dose 312
 Blalock-Taussig shunt 286
bradycardia 138
 junctional 144–5
 sinus 140–1
 temporary pacing 138
 treatment 138
 types of 138
 brain natriuretic peptide 71
breathlessness 19
 causes 21
 diagnosis 20
 investigations 22
 respiratory failure 21
 signs 20
 speed of onset 20
 symptoms 20
 Brock procedure 286
 Brugada syndrome, 176–7
 ECG 424
 bumetanide, dose 316
bundle branch block
 alternating 396
 bifascicular/
 trifascicular 396
 ECG 408
 and cardiac
 catheterization 396
 ECG 394
 left 394, 406
 right 406, 408
 trifascicular 408
 left 394
 pace complexes and
 ventricular tachycardia
 morphology 396–7
 right 394
 and supraventricular
 tachycardia 392
- C**
 calcium antagonists 154, 314
 candesartan, dose 318
cardiac arrest 4
 cardiac asthma 80
cardiac drugs 309
 antiarrhythmics 154–5,
 322
 antiplatelet therapy
 298, 336
 beta-blockers see beta-
 blockers
 calcium antagonists
 155, 314
 diuretics see diuretics
 renin-angiotensin system
 inhibitors 318
 statins 332
 see also *individual drugs*
 and types
cardiac pacing
 overdrive 185
 perioperative care 304
 temporary 368–9
 see also pacemakers
cardiac syncope 30
cardiac tamponade 208
cardiac tumours 352
cardiogenic shock 56, 82
 definition 82
 myocardial infarction 91
 treatment 82–3
cardiomyopathy 86
 arrhythmogenic right
 ventricular 427
 dilated 88
 hypertrophic see
 hypertrophic
 cardiomyopathy
 restrictive 88
cardiotoxicity 302
 anticancer drugs 346
 drug overdose 340
 QT prolongation 344–5
 recreational drugs 342
cardiovascular
collapse 31
 Advanced Life Support
 algorithm 5
 cardiac arrest 4
 circulatory management 8
 continuing
 investigation 10
 differential diagnosis 6
 immediate actions 8–9
 initial assessment 6
 respiratory
 management 8

- shock 4
treatment 10
- carditis in rheumatic fever 118
- carotid sinus massage 27
- Carpentier-Edwards valve 115
- carvedilol, dose 303
- ceftriazone 129
- central venous lines 362**
femoral vein
 approach 364–5
internal jugular
 approach 364–5, 367
subclavian
 approach 364–5
- central venous monitoring 12**
- central venous oxygen saturation 12
- central venous pressure 12
- chest pain 13**
causes 14
diagnosis 14
investigations 17
presentation 15
- chest X-ray
 aortic dissection 189, 192
 pulmonary embolism 214
 valvular heart disease 96
- ciprofibrate 334
- ciprofloxacin 129
- circumflex artery 42
- clopidogrel 336
 NSTEMI 64
- cocaine
 cardiotoxicity 342
 hypertensive crisis 348
- commotio cordis 350
- complete heart block 146**
ECG 412
- computed tomography in
 aortic dissection 194
- confusion/drowsiness 78
- constrictive pericarditis 210**
- continuous positive airway pressure 10
- coronary angiography/revascularization**
aortic dissection 194
peri-operative 298
ST-elevation myocardial infarction 50
unstable angina/
 non-ST-elevation myocardial infarction 64
- coronary artery anatomy 42–3**
- coronary artery bypass graft, perioperative care 298
- coronary artery disease 39**
- coronary atherothrombosis, risk factors 41
- perioperative care 298
- cor pulmonale 224
- Corrigan's sign 105
- CT see computed tomography
- CT pulmonary angiography 216–17
- current of injury (on ECG) 388
- cyanosis 276
- D**
- Damus-Kaye-Stansel operation 286
- daunorubicin 346
- D-dimer 216
- decompensation
 heart failure 70
 valvular heart disease 94
- de Musset's sign 105
- diabetes mellitus,
 heart failure 67
- digoxin 154, 328
 heart failure 74, 284
 toxicity 330–1
- digoxin-specific antibodies 330
- dilated cardiomyopathy 88
- diltiazem 314
- in arrhythmia 154
- diuretics 316**
 heart failure 72
 see also *individual drugs*
- dobutamine 9
- dopamine 9
- doxorubicin 346
- Dressler syndrome 58
- Duroziez's sign 105
- E**
- ECG see electrocardiogram
- echocardiography**
aortic dissection 194
- infective endocarditis 126–7
- in pregnancy 242
- prosthetic valves 114
- pulmonary embolism 214
- saline contrast 230
- systemic emboli 230–1
- transoesophageal
 aortic dissection 194–5
 mitral regurgitation 109
- transthoracic, aortic dissection 194
- valvular heart disease 96
- eclampsia 248**
- ecstasy, cardiotoxicity 342
- Eisenmenger syndrome 278–9
- electrical storms 184–5
- electrocardiogram 383**
accelerated idioventricular rhythm 423
- accessory pathways 392
- ambulatory monitoring 36
- anterolateral myocardial 400
- aortic dissection 192
- arrhythmogenic right ventricular cardiomyopathy 427
- atrial fibrillation 414
- pre-excitation 415
- atrial flutter 416
- atrial tachycardia 417
- Brugada syndrome 425
- bundle branch block 394
 left 395, 407
 right 406, 408
 trifascicular 409
- current of injury 388
- dominant R wave in V1, 392
- electrolytes and 393
- exercise stress testing 380
- heart block
 1st degree 410
 2nd degree 412
 3rd degree (complete) 413
- high take-off 388
- hypertrophic cardiomyopathy 87, 426
- implantable loop recorders 36
- interpretation 386–7
- junctional rhythm 410
- left ventricular hypertrophy 392
- long QT syndrome 424
- mean frontal axis 386
- myocardial infarction anterior 389
 inferior 401
 inferolateral-posterior 402
 posterior 390–1
- myocardial ischaemia 402
- normal values 387
- NSTEMI 62–3
- pacemakers
 dual chamber 429
 lead failure 430
 single chamber 428
- patient-activated event recorder 36
- pericarditis 207, 404
- physiology 384
- post-surgery 306
- pre-excitation 420

electrocardiogram**(cont.)**

- pulmonary embolism 217, 219, 405
- pulmonary hypertension 223, 406
- STEMI 44–5
- ST segment abnormalities 388
- supraventricular tachycardia 418–19
- syncope 26, 29
- valvular heart disease 96
- ventricular fibrillation 422
- ventricular tachycardia 421
- embolus, systemic see systemic emboli
- enalapril, dose 318
- endocarditis see infective endocarditis
- ephedrine 9
- epinephrine see adrenaline
- eprenone, dose 316
- esmolol
 - aortic dissection 196
 - arrhythmias 154
 - hypertensive crisis 348
- exercise stress testing 378
- ezetimibe 334

F

- Fallot's tetralogy 270–1
- felodipine, dose 314
- fenofibrate 334
- fibrates 334
- flecainide 154, 324
- flucloxacillin 127
- fluid challenge 12
- 5-fluorouracil 346
- Fontan operation 274, 277, 286
- furosemide 72
 - dose 316

G

- gemfibrozil 334
- gentamicin 129
- gestational hypertension 248
- Glenn shunt 288–9
- glyceryl trinitrate 9
- glycoprotein IIb/IIIa inhibitors 336
- NSTEMI 65
- TIMI risk score 65

H

- haemofiltration 80
- haemolysis caused by prosthetic valves 116

- heart block see atrioventricular block
- heart failure 67**
 - adult congenital heart disease 284–5
 - adverse signs 78
 - and atrial fibrillation 90
 - cardiogenic shock 82
 - causes 69
 - clinical features 68
 - decompensation 70
 - differential diagnosis 70
 - haemodynamic profiles 74
 - investigations 70
 - management 76–7
 - monitoring and goals 76
 - perioperative care 300
 - in pregnancy 238–9
 - and sepsis 90
 - special circumstances 80
 - acute myocardial infarction 80
 - acute ventricular septal defect 80
 - aortic stenosis 81
 - bronchoconstriction (cardiac asthma) 80
 - diabetes mellitus 80
 - flash pulmonary oedema 81
 - hypertensive crisis 80
 - intractable pulmonary oedema and hypoxia 80
 - mitral valve rupture 80
 - right heart failure 80–1
 - thyrotoxicosis 80
 - treatment 284
- heart murmurs 95**
 - grading 97
 - innocent 97
 - herceptin 346
 - hydralazine 320
 - hyperkalaemia, ECG 393

hypertension

- gestational 248
- perioperative care 300
- pregnancy 248
- pulmonary see pulmonary hypertension

hypertensive crisis 80, 348

- aortic dissection 348
- treatment 348

hypertrophic cardiomyopathy 86

- ECG 87, 426
- in pregnancy 238
- hypokalaemia, ECG 393
- hypomagnesaemia, ECG 393

- hypotension
 - heart failure 78
 - post-myocardial infarction 58
 - post-surgery 306
- hypoxia 80

I

- implantable cardioverter defibrillators 186–7
- implantable loop recorders 36
- infective endocarditis 121**
 - avoidance of 303
 - cardiac involvement 124–5
 - clinical features 124
 - complications 132
 - emboli 124, 132
 - culture-negative 130
 - diagnosis 124–5
 - differential diagnosis from tumours 127
 - immunological phenomena 124
 - investigations 126
 - echocardiography 126–7
 - management 128–9
 - antimicrobial therapy 128–9
 - valve replacement surgery 128
 - presentation 122
 - prophylaxis 134–5
 - prosthetic valves 116, 130
 - interleukin-2, 346
 - intra-aortic balloon counterpulsation 374
 - indications 375
 - mechanism of action 375
 - removal 376
- intramural haematoma 200
- irbesartan, dose 318
- ivabradine 338

J

- Jatene procedure 286
- junctional bradycardia 144–5
- junctional rhythm 410

K

- Konno operation 288

L

- labetalol
 - aortic dissection 196
 - hypertensive crisis 349

Lecompte manoeuvre 288
 left ventricular aneurysm 58
 left ventricular hypertrophy,
 ECG 392
 lidocaine 155
 lignocaine 155
 lisinopril, dose 318
long QT syndrome
 drug-induced 344–5
 ECG 424
 inherited (p.175)
 losartan, dose 318
 lymphoma 354–5

M

magnesium sulphate 155
 magnetic resonance imaging
 aortic dissection 198–9
 aortic stenosis 103
 pulmonary stenosis 110
Marfan syndrome
 aortic dissection 199, 201
 pregnancy 246
 metaraminol 9
 metolazone 72
 dose 316
 metoprolol, dose 312
 migraine, with patent
 foramen ovale 232
mitral regurgitation
95, 108
 perioperative care 302
 post-myocardial
 infarction 57
mitral stenosis 95, 106
 perioperative care 302
 in pregnancy 242
 mitral valve rupture 80
 monoamine oxidase
 inhibitors in
 hypertensive crisis 348
 morphine in heart failure 74
 MRI see magnetic resonance
 imaging
 Müller's sign 105
 Mustard operation 280
myocardial infarction
 and atrioventricular
 block 147
 cardiogenic shock 91
 ECG
 anterior 399
 inferior 401
 inferolateral-
 posterior 402
 posterior 394–5
 investigations 17
 non-atherosclerotic
 causes 40
 non-ST segment elevation
 see NSTEMI
 perioperative care 298

physical signs 16
 in pregnancy 240
 ST elevation see STEMI
 myocardial ischaemia,
 ECG 403
 myocardial wall
 rupture 57
 thrombus of 57
myocarditis 84
 myxoma 352–3

N

nicorandil 320
 nicotinic acid 334
 nifedipine, dose 314
 nitrates 320
 heart failure 74
 noradrenaline 9
 Norwood operation 288
NSTEMI 62
 anticoagulation 64
 glycoprotein IIb/IIIa
 inhibitors 65
 immediate
 management 64
 early invasive
 treatment 64
 investigations 62
 ECG 62–3
 signs 62
 symptoms 62
 thienopyridines 64

O

oesophageal pain 15
 oliguria 78
 orthostatic hypotension 28
 overdrive pacing 185

P

pacemakers
 dual chamber, ECG 429
 lead failure, ECG 430
 overdrive pacing in VT 185
 pacing complexes 396–7
 single chamber, ECG 428
 temporary pacing
 138, 368–9
palpitation 33
 papillary
 fibroelastoma 352–3
 patent ductus
 arteriosus 260–1
 patent foramen ovale with
 migraine 232
**percutaneous coronary
 intervention**
 acute coronary
 syndromes 66

perioperative care 298
 STEMI 51–2
pericardial disease 372
pericardial drainage
(pericardiocentesis)
372
 pericardial drains 306
pericardial effusion
208–9
pericarditis 15, 204
 differential diagnosis 46
 investigations 17, 208
 ECG 207, 404
 management 206
 physical signs 16
 post-myocardial
 infarction 57
 perindopril, dose 318
perioperative care 291
 arrhythmias and
 pacing 304
 cardiac failure/reduced
 left ventricular
 function 300
 cardiovascular drugs 296
 coronary artery
 disease 298
 elective/semi-urgent
 cases 296
 emergencies 296
 hypertensive patients 300
 issues 292
 post-surgery
 problems 306
 predictors of risk 294
 anaesthetic-related 294
 patient-related 294
 surgery-related 294
 preoperative
 assessment 292
 valvular heart disease 302
 pheochromocytoma,
 hypertensive crisis 348
 postpericardiotomy
 syndrome 306
post-surgery
problems 306
 atrial fibrillation 306
 atrioventricular
 conduction
 block 306
 hypertensive patients 306
 postpericardiotomy
 syndrome 306
 potassium channel
 blockers 154
 Pott's anastomosis
 shunt 288
practical procedures 359
 central venous lines 362
 exercise stress testing 378
 insertion of arterial
 line 370

practical procedures (cont.)

- intra-aortic balloon counterpulsation 374
- pericardial drainage (pericardiocentesis) 372
- pulmonary artery (Swan-Ganz) catheters 366
- temporary pacing 368–9
- pravastatin, dose 332
- pre-eclampsia 248**
- pre-excitation
 - atrial fibrillation, ECG 414
 - ECG 420
- Wolff-Parkinson-White syndrome 174–5
- pregnancy 235**
 - anticoagulation 252
 - aortic disease 246–7
 - arrhythmias 244
 - cardiac management 237
 - echocardiography 243
 - general management 236
 - hazardous conditions in 237
 - heart failure 238–9
 - hypertension 248
 - hypertensive crisis 348
 - hypertrophic cardiomyopathy 238
 - Marfan syndrome 247
 - myocardial infarction 240
 - normal physiological changes 236
 - pulmonary embolism 249
 - valvular heart disease 242
 - ventricular tachycardia 244
- preoperative assessment 292**
- procainamide 155
- propafenone 155
- propranolol
 - aortic dissection 196
 - dose 312
 - hypertensive crisis 349
- prosthetic valves 114–15**
 - anticoagulation 117
 - bioprosthetic 114
 - clinical 114
 - complications 116
 - echocardiography 114
 - endocarditis 116, 130
 - metallic 114
 - types of
 - ball-and-cage 115
 - bi-leaflet tilting 115
 - Carpentier-Edwards 115
 - tilting disc 115
 - pulmonary artery (Swan-Ganz) catheters 366–7

pulmonary embolism 15, 212

- investigations 17, 217
 - chest X-ray 214
 - ECG 215, 217, 404
 - echocardiography 216
- management 218
- physical signs 16, 214–15
- pregnancy 250
- presentation 214
- risk factors 214
- pulmonary hypertension 220**
 - causes 221
 - classification 221
 - investigations 220
 - ECG 406
 - management 222
 - vasodilator therapy 222
 - presentation 220
 - treatment 278
- pulmonary oedema 91**
 - flash 81
 - in heart failure 78
 - intractable 80
 - non-cardiogenic 70
 - post-myocardial infarction 56
- pulmonary regurgitation 110**
- pulmonary stenosis 110**
 - MRI 110
- pulmonary vascular disease 213**
- pulsus paradoxus 209

Q

- QT prolongation see long QT syndrome
- Quincke's sign 105

R

- ramipril, dose 318
- Rastelli operation 288
- recreational drugs, cardiotoxicity 342
- re-entry tachycardias 244**
- renin-angiotensin system inhibitors 318
- reperfusion therapy 46, 48
 - indications for 48–9
- respiratory failure 21**
- restrictive cardiomyopathy 88**
- reteplase 52
- rheumatic fever 118–19**
- rifampicin 129

right ventricular infarction 54

- Ross operation 288
- rosuvastatin, dose 332

S

- saline contrast echocardiography 230
- sarcoma 354
- Senning operation 288
- sepsis and heart failure 90
- shock 4**
 - causes of 7
 - simvastatin, dose 332
 - single ventricle 272–3
- sinus arrest 142–3**
- sinus bradycardia 140–1**
- sinus tachycardia 158–9**
- sodium channel blockers 154
- sodium nitroprusside
 - aortic dissection 196
 - heart failure 74
 - hypertensive crisis 348
- sotalol 154
 - dose 312
- spironolactone 72
 - dose 316
 - heart failure 284
- statins 332
- ST elevation myocardial infarction see STEMI
- STEMI 44**
 - additional treatments 54
 - complications 56
 - early 57
 - immediate 56
 - late 58
 - differential diagnoses 46
 - ECG 44–5
 - electrocardiogram 44–5
 - immediate management 46
 - investigations 44–5
 - percutaneous coronary intervention 50–1
 - post-infarct management 60
 - reperfusion therapy 46, 48
 - risk stratification and prognosis 54–5
 - signs 44
 - symptoms 44
 - thrombolysis 52–3
 - trypsin measurement 47
 - stents, endovascular 196
 - streptokinase 52
 - ST segment abnormalities on ECG 388

subarachnoid haemorrhage
in hypertensive
crisis 348

**supraventricular
tachycardia**

and bundle branch
block 397

ECG 418–19

syncope 23

adult congenital heart
disease 282–3

cardiac 30

carotid sinus massage 27

causes 25

diagnosis 24

driving and lifestyle

restrictions 31

hospital admission 26

investigations 26

ECG 26, 29

tilt table testing 27

neurally mediated

(vasovagal) 28

orthostatic

hypotension 28

systemic emboli 227

T

tachycardia 152

adenosine in 156–7

atrial see atrial tachycardia

atrioventricular nodal

re-entrant 170–1

atrioventricular

re-entrant 172–3

immediate

management 152

pharmacological

treatment 154–5

presentation 152

re-entry 244

sinus 158–9

treatment options 152

types of 153

ventricular see ventricular

tachycardia

tenecteplase 52

theophylline,

cardiotoxicity 340

thienopyridines 64

thrombolysis

choice of

thrombolytic 52

contraindications 53

failure to reperfuse 52

STEMI 52–3

thrombophilia screen 216

thrombosis in

prosthetic valves 116

thyrotoxicosis 80

tilting disc valve 115

tilt table testing 27

torsade de pointes

182–3

transoesophageal

echocardiography

aortic dissection 194–5

mitral regurgitation 109

transposition of the

great arteries

264–5

arterial switch

operation 264

atrial switch

operation 264

congenitally

corrected 268–9

surgical options 264

unoperated

patients 264

transthoracic

echocardiography see

echocardiography

Traube's sign 105

traumatic heart

disease 350

blunt trauma 350

penetrating trauma 350

tricuspid

regurgitation 112

tricuspid stenosis 112

tricyclic antidepressants,

cardiotoxicity 340

troponin 47

tumours see cardiac

tumours

U

unstable angina see angina

V

valsartan, dose 318

valvular heart disease 93

antibiotic prophylaxis 100

chest X-ray 96

chronic 100

clinical signs 96

decompensation 94

differential diagnosis 96

ECG 96

echocardiography 96

general management 98

indications for

surgery 99

investigations 96

murmurs see heart

murmurs

non-cardiac

surgery in 100

perioperative care 302

in pregnancy 242

presentation 94

prosthetic valves see

prosthetic valves

rheumatic fever

118–19

symptoms and signs 96

see also specific valve

lesions

vancomycin 128–9

vasodilators in heart

failure 74

ventilation

continuous positive

airway pressure 10

invasive 80

non-invasive 10, 80

ventricle

left see left ventricle/

ventricular

right see right ventricle/

ventricular

single 272, 286

ventricular arrhythmia

post-myocardial

infarction 56

ventricular

fibrillation 176–7

ECG 422

ventricular pre-excitation

see pre-excitation

ventricular septal

defect 80, 258–9

ventricular septal

rupture 57

ventricular tachycardia

58, 178–9

adult congenital heart

disease 280

ECG 420

monomorphic 180–1

morphology 396–7

polymorphic 182–3

pregnancy 244

see also ventricular

fibrillation

verapamil 155

dose 315

W

Waterston shunt 288

Wenckebach

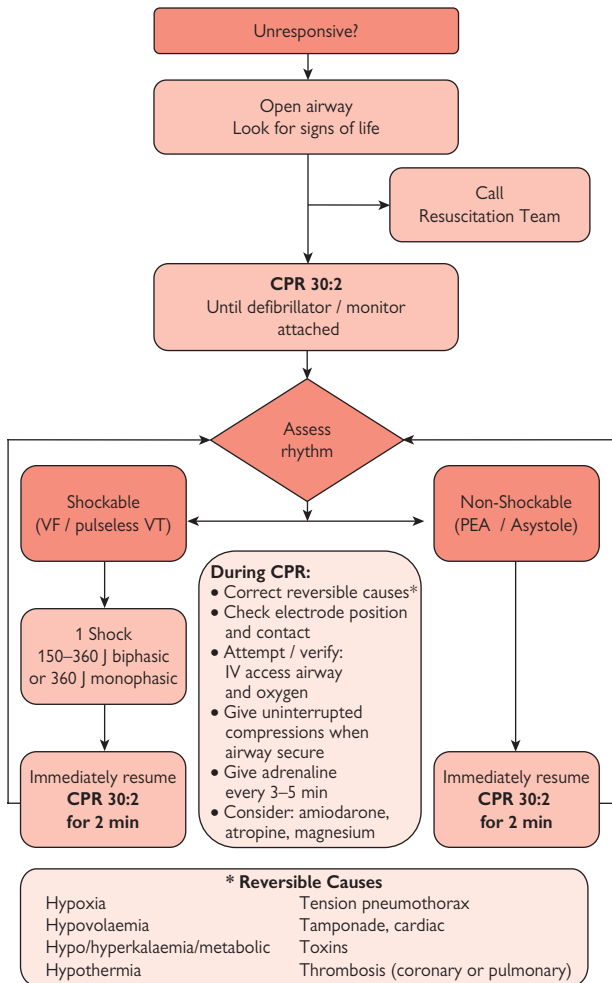
phenomenon 147

Wolff-Parkinson-

White syndrome

174–5

This page intentionally left blank



Reproduced with permission from the Resuscitation Council UK.