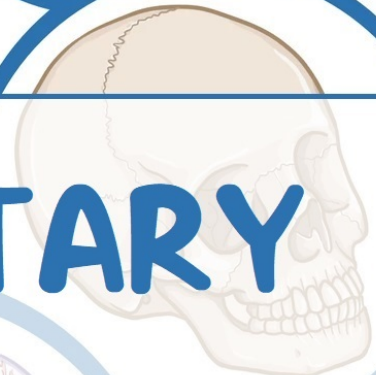
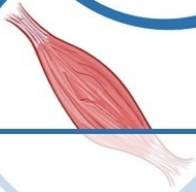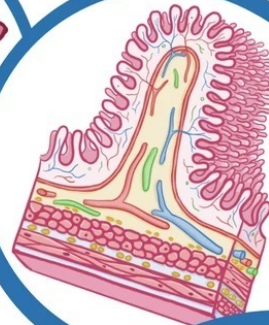
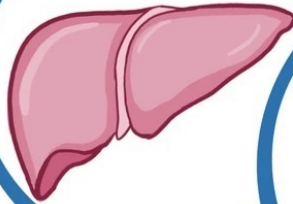
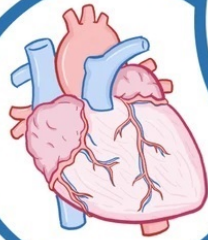
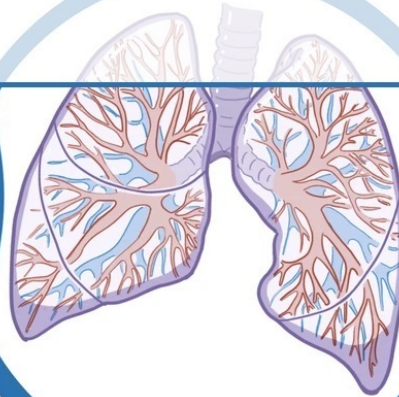
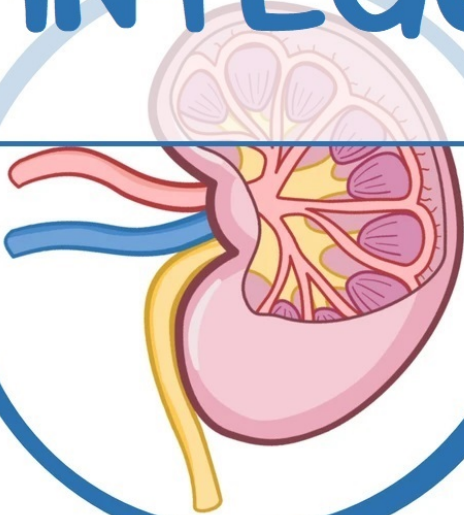


# PHYSIOLOGY

---



## INTEGUMENTARY



HIGH-YIELD  
NOTES

[AfraTafreeh.com](http://AfraTafreeh.com)

# Table of Contents

**Skin Structures 1**

**Skin Anatomy & Physiology 1**

**Hair, Skin & Nails 3**

**Wound Healing 5**



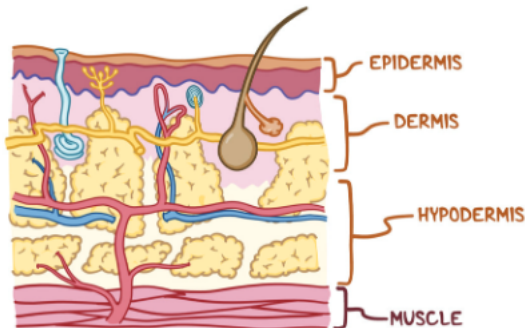
# NOTES

## SKIN STRUCTURES

### SKIN ANATOMY & PHYSIOLOGY

[osms.it/skin-anatomy-and-physiology](https://osms.it/skin-anatomy-and-physiology)

- Skin is body's largest organ
  - Seven percent of total body weight
- Comprises integumentary system, appendages (hair, nails, oil, sweat glands)
  - Protects body (infection, abrasion, dehydration, etc)
  - Regulates body temperature
  - Detects pain, sensation, pressure
  - Essential for vitamin D production
- Three layer division
  - Epidermis, dermis, hypodermis



**Figure 25.1** The three layers of the skin, from superficial to deep, include: the epidermis, dermis, and hypodermis.

#### EPIDERMIS

- Epidermis
  - Stratified squamous epithelium
  - Thin outermost layer
- Multiple layers of developing keratinocytes (contain keratin)
  - Make, secrete glycolipids; prevent water seeping into/out of body

#### Stratum basale

- **Innermost layer:** single columnar stem cell layer; dividing, producing keratinocytes
  - Keratinocytes contain cholesterol precursors activated by UVB light → vitamin D (regulates calcium absorption)
- Also contains melanocytes (secrete melanin, giving skin its color)
  - UVB light stimulates melanin secretion → placed into melanosomes, moved up by keratinocytes → scatters UVB light → natural sunscreen (prevents skin cancer from excessive UVB light)

#### Stratum spinosum

- **Second layer:** comprises 8–10 keratinocyte cell layers which can no longer divide
  - Proteins on keratinocytes help them adhere together
  - Dendritic cells seek out invading microbes

#### Stratum granulosum

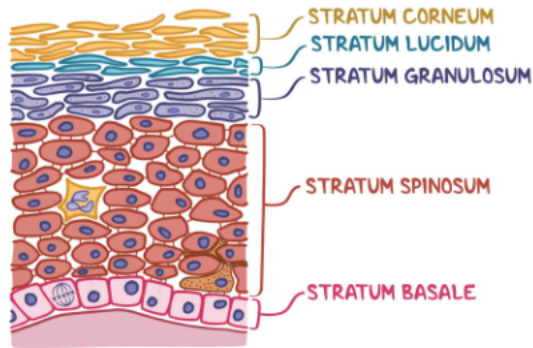
- **Third layer:** comprises 3–5 keratinocyte cell layers undergoing keratinization (flatten out, die) → epidermal skin barrier formed
  - Keratohyalin granules in keratinocytes contain keratin precursors which aggregate, cross-link → keratin bundles
  - Lamellar granules in keratinocytes contain glycolipids (secreted to cell surface, glues cells together)

#### Stratum lucidum

- **Fourth layer:** comprises 2–3 dead keratinocyte cell layers that have secreted most of their lamellar granules
  - Only found in thick skin (e.g. palms, soles of feet)

## Stratum corneum

- **Uppermost layer:** comprises 20–30 dead keratinocyte cell layers glued together with glycolipids
  - Dead **keratinocytes** secrete defensins to fight pathogens
  - Cells from stratum lucidum push up → cells from this layer shed → skin flakes/dandruff



**Figure 25.2** The five layers of the epidermis. Stratum basale is the deepest layer and stratum corneum is the most superficial.

## DERMIS

- Dermis
  - Central layer
  - Two layer division (papillary layer; deeper, thicker reticular layer)

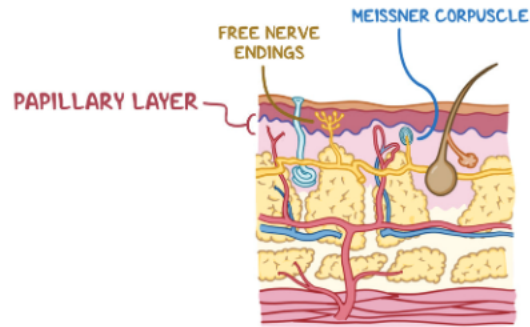
### Papillary layer

- Fibroblasts (producing collagen) arranged in papillae
- Contains blood vessels, macrophages, nerve endings (e.g. Meissner's corpuscles for fine touch, free nerve endings for pain)
- Responsible for fingerprints (↑ gripping, sensing abilities)

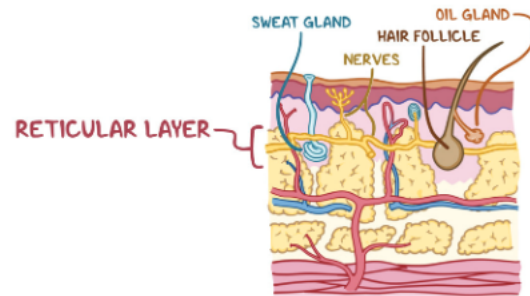
### Reticular layer

- Fibroblasts (produces elastin for flexibility)
- Contains oil, sweat glands; lymphatic, blood vessels; hair follicles; macrophages; nerves (e.g. Pacinian corpuscle for pressure, vibration)
- Collagen packed tightly → ↑ support
- Regulates temperature with blood vessels, sweat glands

- Blood vessels dilate when hot (blood moves closer to surface → allows heat loss)/contract when cold (blood moves away from surface → prevents heat loss)
- Sweat glands ↑ secretion when hot (↑ heat to evaporate sweat)/↓ when cold (↓ heat to evaporate sweat)



**Figure 25.3** The papillary layer of the dermis contains multiple types of nerve endings.



**Figure 25.4** Contents of the reticular layer of the dermis.

## HYPODERMIS

- Hypodermis (subcutaneous tissue) inner layer
  - Contains adipocytes (store fat), fibroblasts, macrophages, blood vessels, nerves, lymphatics
  - Insulates deeper tissues; provides padding; anchors skin to underlying muscle with connective tissue (e.g. collagen)

# HAIR, SKIN, & NAILS

osms.it/hair-skin-and-nails

- Skin appendages include hair, nails, skin glands (oil/sebaceous, sweat/sudoriferous)
    - Regulate body temperature; environmental protection
    - Originate in dermis
  - Hair, nails comprised of long, filamentous protein (keratin)
    - **Keratin:** produced by keratinocytes during keratinization (cells rapidly replicate, die)
    - Soft keratin (produced by skin); hard keratin (produced by hair, nails)
- HAIR**
- Includes vellus hairs (short, thin); terminal hairs (more visible, growth starts at puberty)
  - Found everywhere
    - **Exceptions:** palms, soles of feet, lips
  - Hair strands sit in follicle; epidermal tissue dips into dermis
    - Associated with sebaceous glands, arrector pili muscles, apocrine glands, nerve receptors
  - **Composition:** shaft, root, bulb
    - **Hair matrix:** active hair growth site, found inside bulb; contains keratinocytes, melanocytes; blood supplied by papilla
  - Keratinocytes die, flatten out → hard keratin fills up cell → gradually get pushed up follicle forming hair
    - **Hair growth:** includes growth, resting phases
    - Keratinocytes in bulb replicate set number of times → follicle eventually stops producing hair/produce vellus hairs instead (genetically determined) → baldness
  - Melanocytes produce melanin (protein pigments that give hair color)
    - Melanocytes move melanin into melanosomes → taken up by keratinocytes

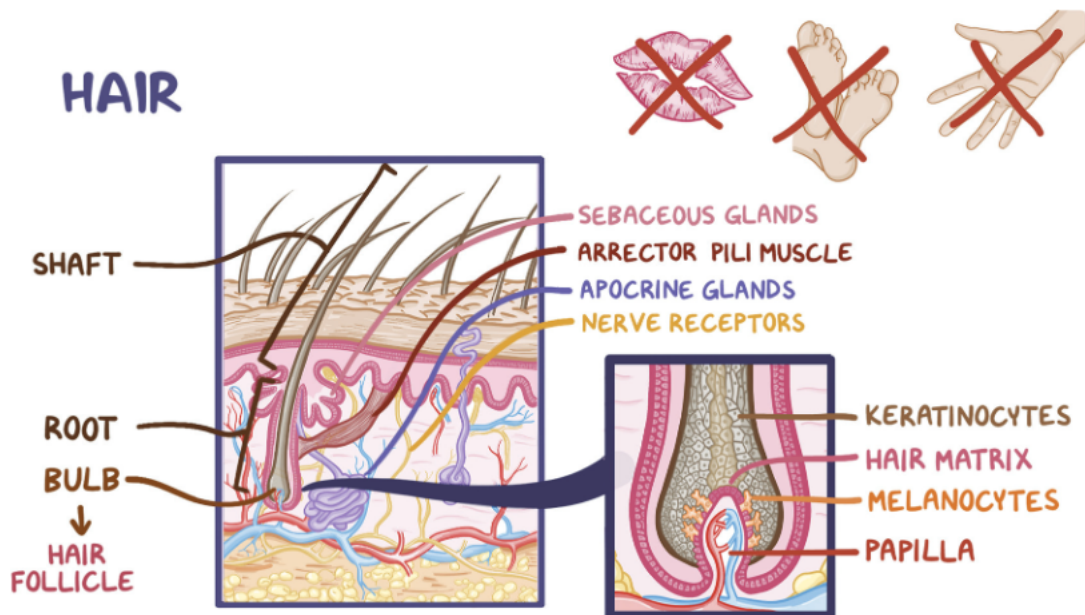
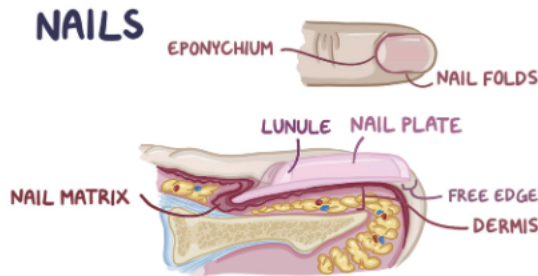


Figure 25.5 Composition of hair and associated structures.

- ↑ age → ↓ melanin → faded, white hair
- Nerve receptors around bulb stimulated when hair shaft moves
- Arrector pili muscle contracts, pulls hair (e.g. cold weather/frightened) → goosebumps

## NAILS

- Grow from proximal to distal fingertips/toes
  - Surrounded on either side by nail folds
  - Closed off proximally by eponychium → forms cuticle (dead skin keratinocytes that cover junction between nail, skin)
- **Nail matrix composition:** lunula, nail plate
  - **Lunula:** white, crescent-shaped part of nail near eponychium
  - **Free edge:** nail plate portion hanging over skin
- Modified keratinocytes in matrix form plate by keratinization (similar to hair)
- Nails grow continually through life (unlike hair)



**Figure 25.6** Superior view and cross section of a finger illustrating components of the nail.

## SEBACEOUS GLANDS

- Secrete sebum (softens hair shaft, prevents moisture-loss, deters pathogens) onto hair follicles/through pores → skin surface
- **During puberty:** ↑ androgen hormones → ↑ sebum production → blocks pores, plugs hair follicles → enclosures allow infection development (e.g. acne, folliculitis)

## SUDORIFEROUS GLANDS

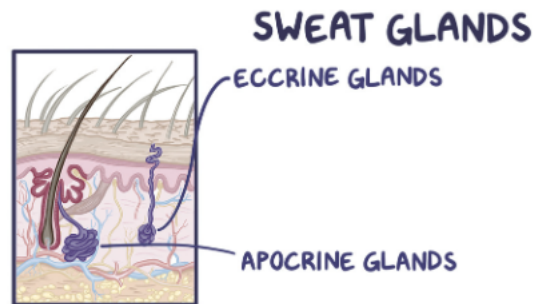
- AKA sweat glands

### Eccrine (merocrine) glands

- Found everywhere
  - **Exceptions:** lips, ear canal, clitoris, glans of penis
- Coil-shaped structure; in dermis; duct opens into pore on skin surface
- **Sweat:** hypotonic (mostly water, electrolytes); dermcidin (destroys bacteria); cools body (evaporation)
- Sympathetic nervous system activation during ↑ cardiovascular activity, fight-or-flight response, fear/anxiety

### Apocrine glands

- Found in armpits, genitals
  - Become active during puberty
- Similar to eccrine glands
  - Bigger, fewer; produce secretions with ↑ lipids, proteins
  - Secretions metabolized by bacteria → body odor
- Several modified apocrine gland types
  - **Ceruminous glands:** in ear; produce cerumen; protects eardrum (with ear canal hairs)
  - **Mammary glands:** in breasts; produce milk



**Figure 25.7** The two types of sweat glands (sudoriferous glands).

afratafreeh.com exclusive

# WOUND HEALING

osms.it/wound-healing

- Damaged tissue repair process
  - Acute wounds heal quickly (days–weeks)
  - Chronic wounds heal slowly (months)

## Regenerative tissue capacity

- **Classification:** labile, stable, permanent
- **Labile tissues** (e.g. skin, connective tissue, intestines)
  - **Heal well:** stem cells constantly divide → rapid, effective healing
- **Stable tissues** (e.g. liver, endocrine glands, proximal kidney tubules)
  - **Heal slowly:** mature differentiated cells divide/regenerate by hyperplasia
- **Permanent tissues** (e.g. skeletal muscle, cartilage, neurons)
  - **Heal poorly:** lack of stem cells, no hyperplasia → replaced by scar tissue (fibrosis) → function loss

## Open wounds

- Open wounds healed by primary, secondary, tertiary intention
- **Primary intention** (most surgical wounds)
  - Wound edges fuse (e.g. stitching/gluing) → stem cells (e.g. epidermis) approximate, regenerate damaged tissue (minimal scarring)
- **Secondary intention**
  - Wound edges too far apart (e.g. pressure ulcers, tooth extraction, severe burns) → stem cells do not approximate → wound replaced by connective tissue growing from base upwards (slower healing; more scar tissue)
- **Tertiary intention** (delayed closure)
  - Wound cleaned, debrided → purposefully left open (↓ bacterial contamination likelihood) → closed by primary intention/left open for secondary intention

## Penetrating trauma wound healing

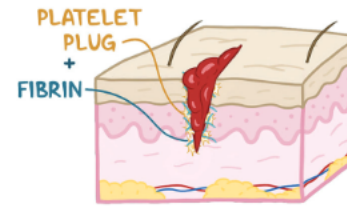
- Penetrating trauma wound healing steps (e.g. cutting finger → damaged epidermis, dermis, interstitial space)
- **Hemostasis** (first step)
  - Blood vessels constrict → platelets adhere to site → forms platelet plug → fibrin mesh reinforces platelet plug → forms **blood clot**
- **Inflammation** (second step)
  - Damaged cells release chemokines, cytokines → **neutrophils, macrophages** recruited; **blood vessels dilate** → immune cells clear debris, digest dead/damaged cells, destroy microbes → blood clot, dead macrophages combine, form scab
- **Epithelization/migration** (third step)
  - **Basal cells** (epidermal stem cells) proliferate, replace lost/damaged cells → rejuvenated epidermal layer (approx. 48 hours)
- **Fibroplasia** (fourth step)
  - **Fibroblasts** in dermis proliferate, secrete collagen (assemble → form collagen fibrils → collagen bundles) → blood vessel growth stimulated (**angiogenesis**); fibroblasts also produce glycoproteins, sugars → create **granulation tissue** in dermal layer
- **Maturation** (fifth step)
  - **Collagen cross-linking:** covalent bonds form between collagen bundles, improving tensile strength
  - **Collagen remodeling:** fibroblasts degrade subpar collagen
  - **Contraction:** myofibroblasts produce contractile proteins, pulling wound's edges together
  - **Repigmentation:** melanocytes proliferating, restoring color to damaged skin

## Chronic wounds

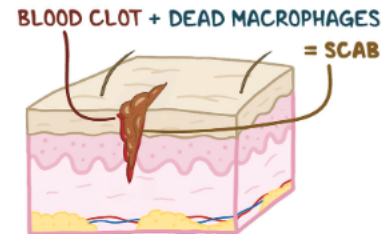- Healing prevention factors → chronic wounds
  - *Narrowed capillaries*: prolonged compression/disease (e.g. diabetes, atherosclerosis) → ↓ blood flow → damaged tissue cannot be reached by immune cells, insufficient oxygen/nutrients → tissue necrosis
  - *Infection*: pathogens compete for oxygen; cause ongoing damage, inflammation
  - *Edema*: disrupts fibroblast activity, collagen deposition, collagen cross linking

## WOUND HEALING

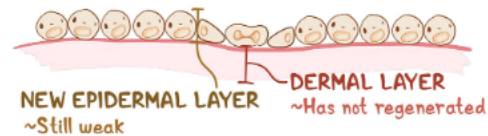
### FIRST STEP



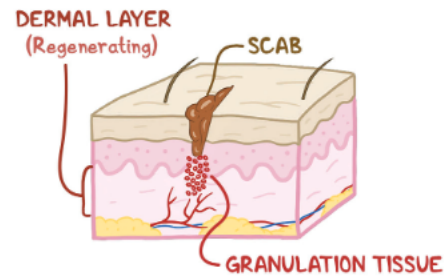
### SECOND STEP



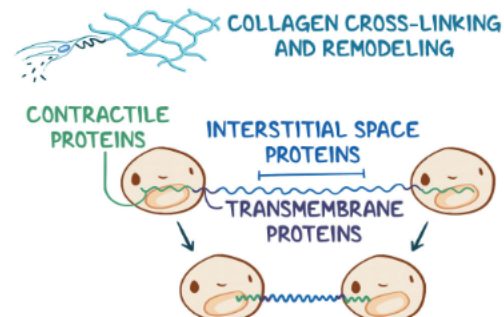
### THIRD STEP



### FOURTH STEP



### FIFTH STEP



**Figure 25.8** The five steps of penetrating trauma wound healing.